

**PATIENT**

Chester Nichols

**SPECIES**

Canine

**BREED**

Dachshund

**SEX**

Neutered Male

**AGE**

2 Years

**WEIGHT**

15.8 Lbs.

**INTERPRETED BY**

Andrea Nicastro, DMV,  
Diplomate DACVIM  
(Small Animal  
Internal Medicine)

**IMAGING PERFORMED BY**

Dr. Logas

**HOSPITAL NAME**

Bradentown  
Veterinary Hospital

**REFERRING VET**

Laurel Logas

**INVOICE**

10052

**DATE**

12/17/21

**PRESENTING CLINICAL SIGNS**

History: P is presenting for exam. P has history of seizures since April 2021. Was seen at ER and mild elevation in liver values noted. Not on any meds as seizures were occurring every 6 weeks but have increased to weeks now.

Abnormal PE/Chem/CBC/UA Results: CBC/Chem- GGT-15 (0-14), TBIL-0.9 (0.0-0.6)  
Bile acid. Pre :9.2 Post: 28

**ULTRASONOGRAPHIC EXAMINATION OF THE ABDOMEN**

**Urinary System**

The urinary bladder, trigone, and pelvic urethra are normal in thickness and the mucosal surface is smooth. The bladder is moderately distended. A small amount of suspended echogenic debris is observed within the lumen. No masses, inflammatory changes or calculi are observed. Ureteral papillae and visualized portion of the proximal urethra, visible to a depth of 2 cm, are normal.

The prostate is not definitively visualized due to its pelvic location

The left kidney is normal size (3.83 cm in length); normal shape and architecture with smooth peripheral margins. There is a normal 1:3 cortex to medulla ratio with normal corticomedullary distinction. There is no evidence of pyelectasia, nephroliths, infarcts or hydronephrosis.

The right kidney is normal size (4.56 cm in length); normal shape and architecture with smooth peripheral margins. There is a normal 1:3 cortex to medulla ratio with normal corticomedullary distinction. There is no evidence of pyelectasia, nephroliths, infarcts or hydronephrosis.

**Adrenal Glands**

The left adrenal gland is normal size (0.41 cm at cranial pole) (0.48 cm at caudal pole) normal shape; homogenous parenchyma. The glandular echogenicity and detail are unremarkable. Capsule, cortex, and medullary definition are normal. The phrenicoabdominal vein and surrounding vasculature are normal.

The right adrenal gland is normal size (1.41 cm at cranial pole) (0.51 cm at caudal pole) (1.89 cm in length) normal shape; homogenous parenchyma. The glandular echogenicity and detail are unremarkable. Capsule, cortex, and medullary definition are normal. The phrenicoabdominal vein and surrounding vasculature are normal.

**Spleen**

The spleen is normal in size (1.26 cm in width at the level of the hilus) with a normal capsular contour. There is appropriate echogenicity and echotexture. No focal lesions are observed. Splenic vasculature is normal.

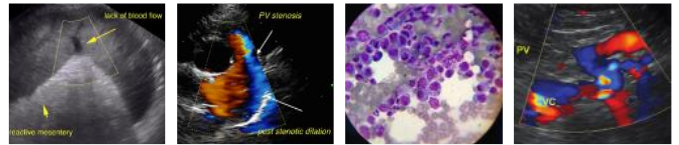
**Liver**

The liver is subjectively normal in size with normal contours and structure. There is appropriate echogenicity and echotexture. No overt structural evidence of inflammatory, infiltrative or regenerative pathology is evident. Vascular and biliary tracts are of normal volume with no evidence of congestion. No pathological hepatic lymphadenopathy observed.

The gall bladder lumen is moderately distended. The wall is thin and smooth. Luminal contents are anechoic. The cystic and common bile ducts are normal/not seen.

**Gastrointestinal**

The gastric lumen is mildly to moderately distended with ingesta and gas. The gastric wall is normal in thickness with a normal layering pattern. The small intestinal lumen is not dilated. The stomach and intestine are free of stasis and exhibit normal peristaltic activity. The gastric wall and pylorus are



**PATIENT**

Chester Nichols

normal in thickness with a normal layering pattern. The pyloric outflow tract is patent. The small intestinal wall thickness is normal with a normal layering pattern and appropriate mural detail. Discreet masses are not identified. The colonic wall is normal. No obstructive disease is noted.

**SPECIES**

Canine

**Pancreas**

The region of the pancreas is isoechoic relative to surrounding omental fat. No obvious parenchymal abnormalities are observed. There is no evidence of regional inflammation or effusion. A portion of the pancreas is obscured by the gastric distention. In the visualized portions, no obvious pathology is observed.

**BREED**

Dachshund

**Free Abdomen**

The peritoneal cavity is normal. There is no evidence of inflammation or effusion. The abdominal lymph nodes are normal/not visible.

**SEX**

Neutered Male

**ULTRASONOGRAPHIC FINDINGS**

**Primary Findings**

- Unremarkable abdomen. An obvious cause for the patient's mildly elevated serum bile acids is not identified in this study. Considerations include microvascular dysplasia, congenital portosystemic shunts (less likely, due to the minimal degree of bile acid elevation), other hepatopathy.

**AGE**

2 Years

**WEIGHT**

15.8 Lbs.

**INTERPRETATION OF THE FINDINGS & FURTHER RECOMMENDATIONS**

- Consider a repeat pre- and post-prandial serum bile acids +/- a blood ammonia level to further evaluate for hepatic encephalopathy as a possible cause for seizures. Otherwise, referral to a board-certified neurologist is recommended for further seizure evaluation.
- To further assess for liver disease, a contrast abdominal CT scan (to assess for a portosystemic shunt) and/or a liver biopsy can be considered.

**INTERPRETED BY**

Andrea Nicastro, DMV,  
Diplomate DACVIM  
(Small Animal  
Internal Medicine)

**IMAGING  
PERFORMED BY**

Dr. Logas

**HOSPITAL NAME**

Bradentown  
Veterinary Hospital

**REFERRING VET**

Laurel Logas

**INVOICE**

10052

**DATE**

12/17/21



**PATIENT**

Chester Nichols

**SPECIES**

Canine

**BREED**

Dachshund

**SEX**

Neutered Male

**AGE**

2 Years

**WEIGHT**

15.8 Lbs.

**INTERPRETED BY**

Andrea Nicastro, DMV,  
Diplomate DACVIM  
(Small Animal  
Internal Medicine)

**IMAGING  
PERFORMED BY**

Dr. Logas

**HOSPITAL NAME**

Bradentown  
Veterinary Hospital

**REFERRING VET**

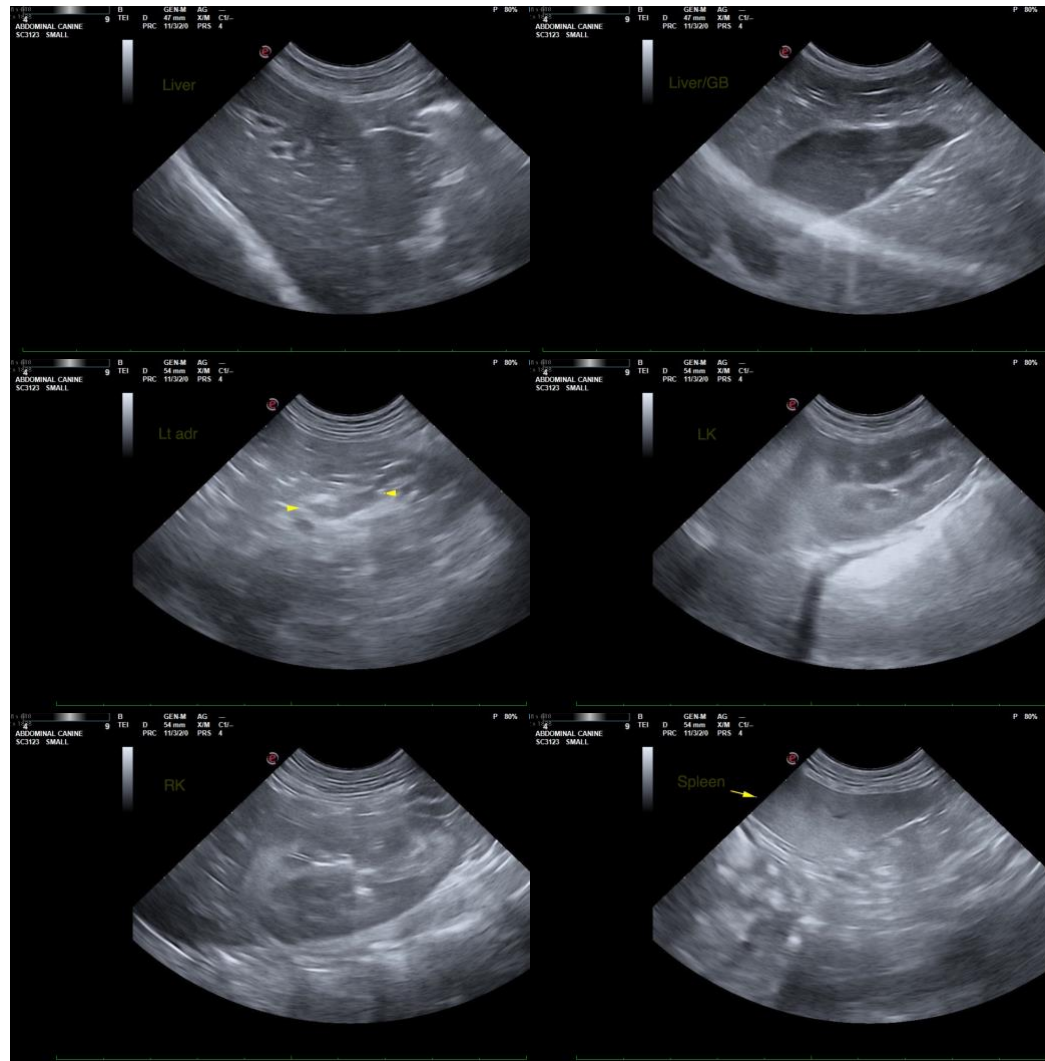
Laurel Logas

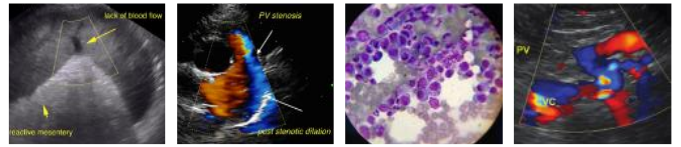
**INVOICE**

10052

**DATE**

12/17/21





**PATIENT**

Chester Nichols

**SPECIES**

Canine

**BREED**

Dachshund

**SEX**

Neutered Male

**AGE**

2 Years

**WEIGHT**

15.8 Lbs.

**INTERPRETED BY**

Andrea Nicastro, DMV,  
Diplomate DACVIM  
(Small Animal  
Internal Medicine)

**IMAGING PERFORMED BY**

Dr. Logas

**HOSPITAL NAME**

Bradentown  
Veterinary Hospital

**REFERRING VET**

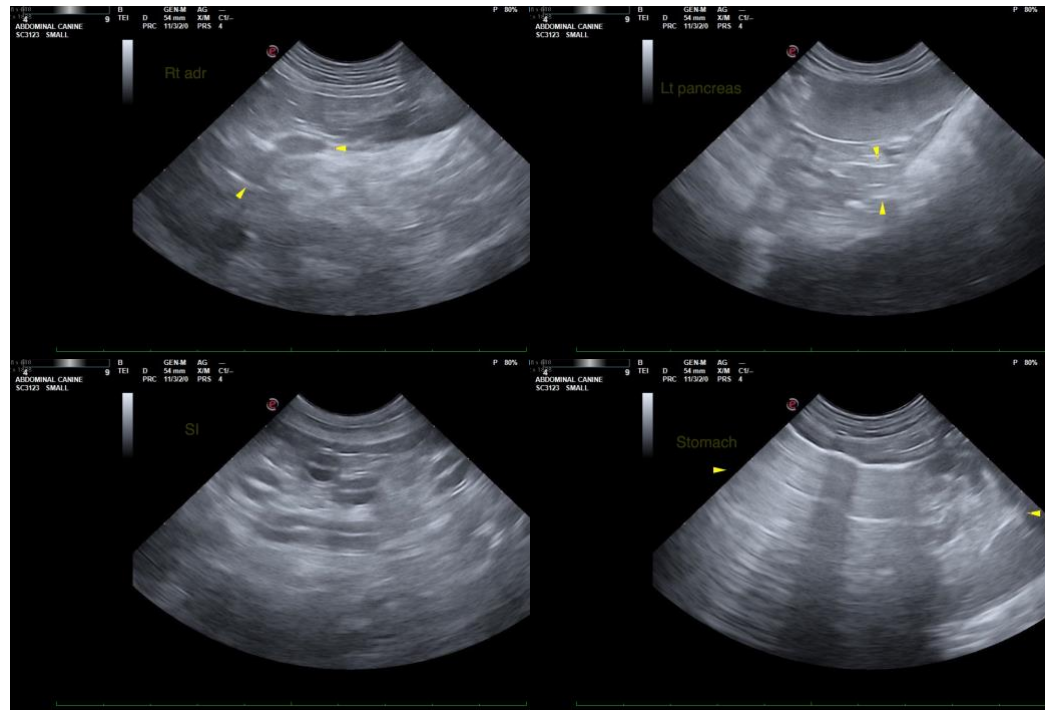
Laurel Logas

**INVOICE**

10052

**DATE**

12/17/21



The information and recommendations provided are based on the images presented by the referring veterinarian. No evaluation can be communicated regarding pathology that was not visible in the image/video clips provided.

Thank you for this referral. If the clinical or image interpretation does not parallel your findings or if I can be of any further assistance please contact me.

**Andrea Nicastro, DVM, Diplomate DACVIM (Small Animal Internal Medicine)**  
info@SonoPath.com