

**DATE**

1/24/2022

**PRESENTING CLINICAL SIGNS**

History: Occasional vomiting over a period of 3 weeks' time (hours after eating, digested food and fluid or fluid alone), now has diarrhea (watery, with blood at end). Still normal appetite and water intake. Some lethargy but only since diarrhea started. Lab work today, x-rays will be repeated today. Rads performed last week which showed enteritis and turgid bowel (review attached).

**PATIENT**

Rocky Thomas

Date of Previous IntraPet Ultrasound: No previous IntraPet scans.  
Sedation: Patient sedated with Torbugesic.

**SPECIES**

Canine

Imaging Performed By: Andi Parkinson, RDMS.

**BREED**

Labradoodle

**ULTRASONOGRAPHIC EXAMINATION OF THE ABDOMEN****Urinary System**

The urinary bladder and visible portion of the pelvic urethra are normal for the degree of luminal distension. The urine is anechoic with no evidence of debris. Cystic calculi and discrete masses are not observed. The region of the trigone and the visible portion of the proximal urethra are normal.

**SEX**

Male, neutered

The prostate is normal in size (1.27 cm in width) and shape. Parenchyma is homogenous. The prostatic urethra appears normal without evidence of dilation or obstruction.

**AGE**

2/6/2021

The left kidney is normal size (6.21 cm in length); normal shape and architecture with smooth peripheral margins. There is a normal 1:3 cortex to medulla ratio with normal corticomedullary distinction. There is no evidence of pyelectasia, nephroliths, infarcts or hydroureter.

**WEIGHT**

69 lbs.

The right kidney is normal size (5.10 cm in length); normal shape and architecture with smooth peripheral margins. There is a normal 1:3 cortex to medulla ratio with normal corticomedullary distinction. There is no evidence of pyelectasia, nephroliths, infarcts or hydroureter.

**INTERPRETED BY**

Andrea Nicastro, DVM,  
Diplomate ACVIM  
(Small Animal Internal  
Medicine)

**Adrenal Glands**

The left adrenal gland is normal size (0.64 cm at cranial pole) (0.57 cm at caudal pole) (2.94 cm in length); normal shape; homogenous parenchyma. The glandular echogenicity and detail are unremarkable. Capsule, cortex, and medullary definition are normal. The phrenicoabdominal vein and surrounding vasculature are normal.

**HOSPITAL NAME**

Stay Pet Veterinary

The right adrenal gland is normal size (0.63 cm at cranial pole) (0.60 cm at caudal pole) (2.07 cm in length); normal shape; homogenous parenchyma. The glandular echogenicity and detail are unremarkable. Capsule, cortex, and medullary definition are normal. The phrenicoabdominal vein and surrounding vasculature are normal.

**REFERRING VET**

Dr. Klimovitz

**Spleen**

The spleen is normal in size (2.09 cm in width at the level of the hilus) with a normal capsular contour. There is appropriate echogenicity and echotexture. No focal lesions are observed. Splenic vasculature is normal.

**INVOICE**

12894

**Liver**

The liver is subjectively normal in size with normal contours and structure. There is appropriate echogenicity and echotexture. No overt structural evidence of inflammatory, infiltrative or regenerative pathology is evident. Vascular and biliary tracts are of normal volume with no evidence of congestion. No pathological hepatic lymphadenopathy observed. The gall bladder lumen is moderately distended. The wall is thin and smooth. Luminal contents are mostly anechoic. The cystic and common bile ducts are normal/not seen.

### ***Gastrointestinal***

The gastric lumen is distended with ingesta. The gastric wall and pylorus are normal in thickness with a normal layering pattern. The pyloric outflow tract is patent. The small intestinal lumen is not dilated. The small intestinal wall thickness is normal with a normal layering pattern and appropriate mural detail. Discreet masses are not identified. The colonic wall is normal. The colonic lumen contains liquid appearing fecal material. No obstructive disease is noted.

### ***Pancreas***

The pancreas is diffusely prominent in size with minimal deviation from the normal peripheral contours. The parenchyma is hypoechoic relative to surrounding omental fat. No distinct focal lesions are observed. The pancreatic duct is not overtly dilated. There is no evidence of peripancreatic effusion.

### ***Free Abdomen***

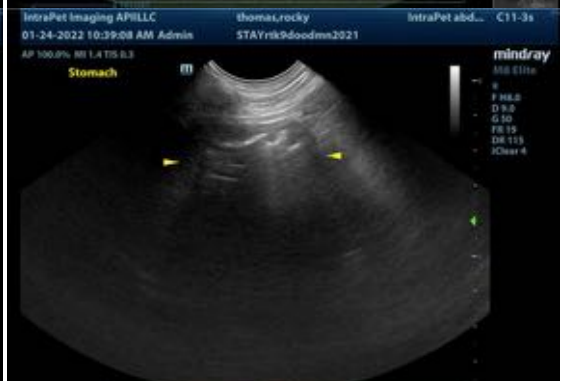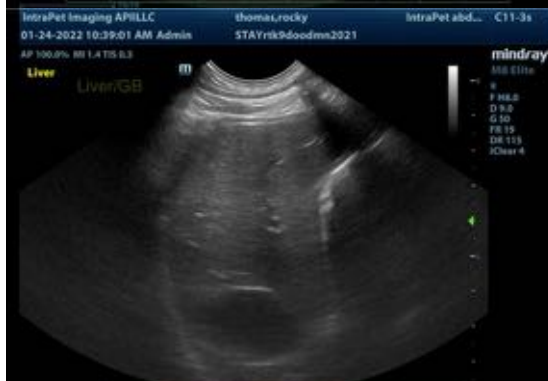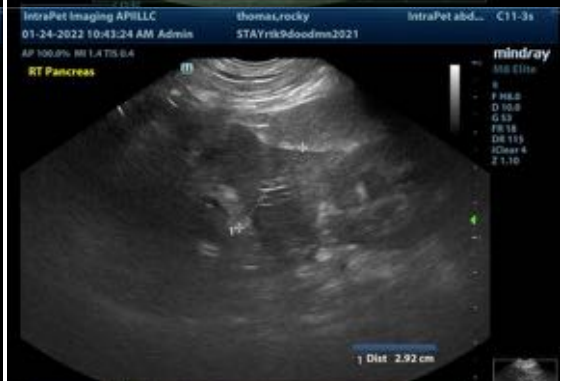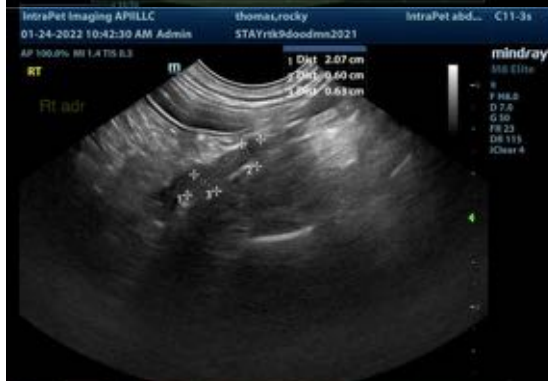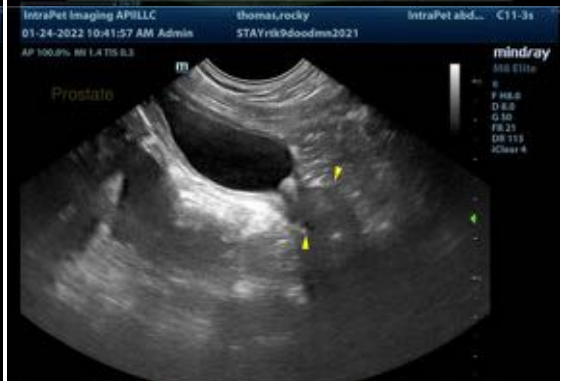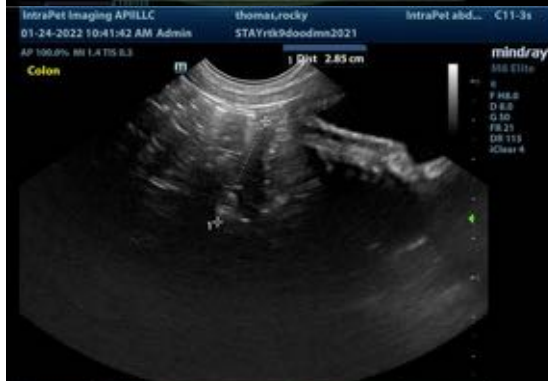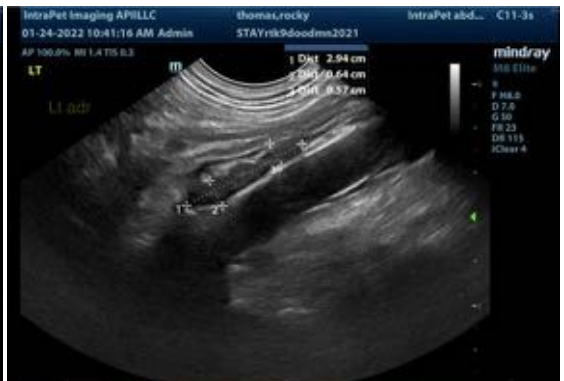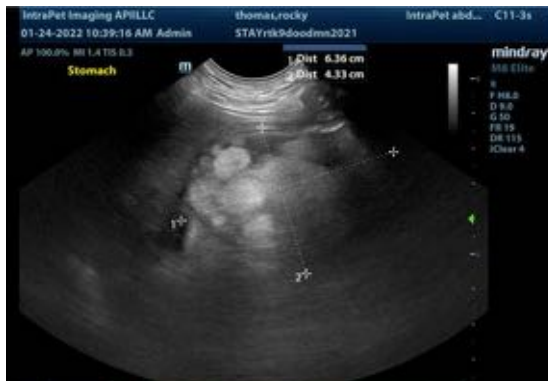The peritoneal cavity is normal. There is no evidence of inflammation or effusion. The abdominal lymph nodes are normal/not visible.

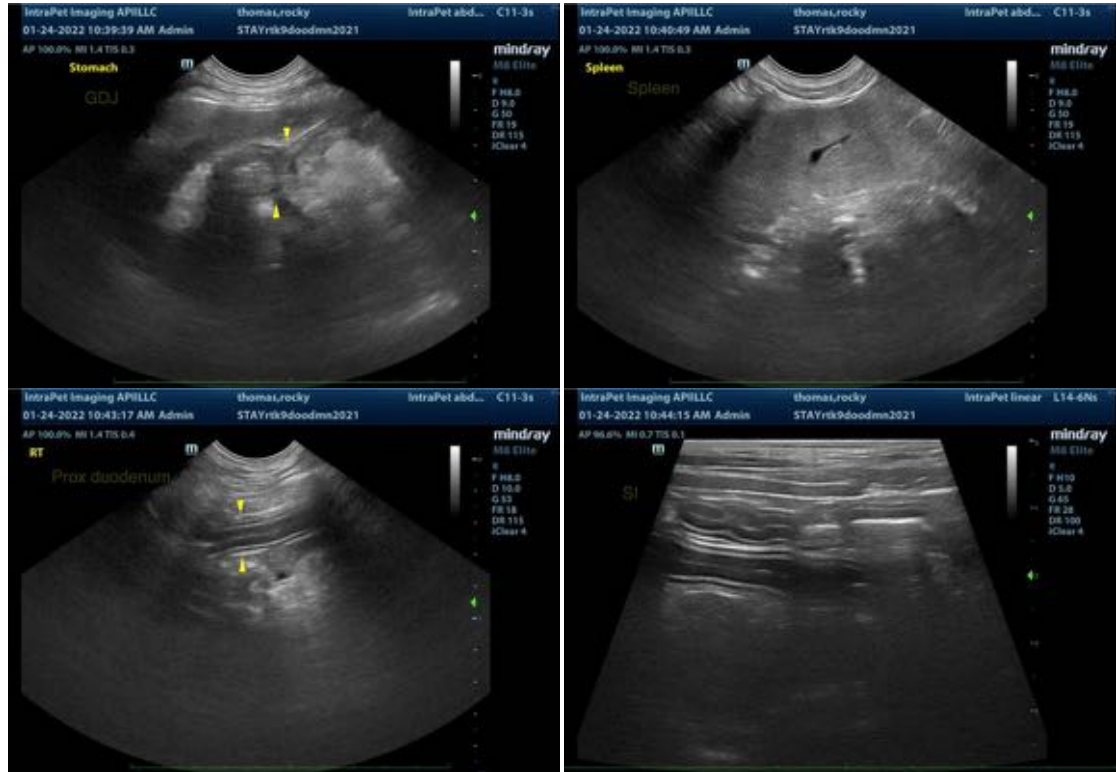
## **ULTRASONOGRAPHIC FINDINGS**

- The presence of ingesta in the gastric lumen despite fasting is suggestive of delayed gastric emptying.
- The pancreatic changes could be consistent with mild chronic pancreatitis. Alternatively, the changes may be a normal variant for this patient.

## **INTERPRETATION OF THE FINDINGS & FURTHER RECOMMENDATIONS**

- Malabsorption panel including serum cobalamin, folate, TLI and PLI.
- A fecal evaluation for ova/Giardia
- Prophylactic deworming with Fenbendazole at 50 mg/kg once a day for 5 days is recommended. Repeat above protocol in 3 weeks.
- A resting cortisol level to screen for hypoadrenocorticism. If resting cortisol level is < 2.0 mcg/dL, an ACTH stimulation test is recommended
- A 6-week limited antigen diet trial to assess for food allergies
- Consider pre and post prandial serum bile acids to assess for occult hepatic dysfunction.
- Consider empirical treatment for small intestinal bacterial overgrowth with a 4 week course of Tylosin.
- Consider supplementation with a probiotic with a high colony count (i.e., Visbiome or Provable Forte).
- Depending on the results of the above diagnostics/therapeutics, endoscopic or surgical gastrointestinal biopsies may be necessary to get a definitive diagnosis.
- Three-view thoracic radiographs should be performed prior to anesthesia, particularly to assess cardiovascular status and for any evidence of esophageal disease.





The information and recommendations provided are based on the images presented by the referring veterinarian. No evaluation can be communicated regarding pathology that was not visible in the image/video clips provided.

Thank you for this referral. If the clinical or image interpretation does not parallel your findings or if I can be of any further assistance please contact me.

Andrea Nicastro, DVM, Diplomate ACVIM (*Small Animal Internal Medicine*)  
Andrea.nicastro@sonopath.com