



**PATIENT**

Gino Rivera

**SPECIES**

Canine

**BREED**

Yorkshire Terrier

**SEX**

Male

**AGE**

6 Yrs.

**WEIGHT**

6.2 lbs.

**INTERPRETED BY**

Andrea Nicastro, DVM,  
Diplomate ACVIM  
(Small Animal Internal  
Medicine)

**IMAGING PERFORMED BY**

Dr. Ferrer

**HOSPITAL NAME**

Paseos VC

**REFERRING VET**

Dr. Ferrer

**INVOICE**

12895

**DATE**

1/24/2022

**PRESENTING CLINICAL SIGNS**

**History:** Presented for an abdominal ultrasound. Pt has a history of Diarrhea ( liquid and hematochezia). Pt was hospitalized 4 days ago with IV fluids and metronidazole, famotidine and cerenia and pt was improving, but still having diarrhea and now inappetence and some vomiting. Pt was started on panacur 3 days ago and proviable and mirtzapine. Today we sent more metronidazole.  
**Abnormal PE/Chem/CBC/UA Results:** The PE did not show any major abnormalities related to the diarrhea and decrease appetite noticed. Fecal direct showed overgrowth of bacteria. BW were unremarkable. ALT 193 ( 10-125) ALP 126 (23-212) ABD rads: Large intestine full of gas

**ULTRASONOGRAPHIC EXAMINATION OF THE ABDOMEN**

*Urinary System*

The urinary bladder, trigone, and pelvic urethra are normal in thickness and the mucosal surface is smooth. The bladder lumen is moderately distended with anechoic urine. No masses, inflammatory changes or calculi are observed. Ureteral papillae and visualized portion of the proximal urethra, visible to a depth of 2 cm, are normal.

The prostate is normal in size (0.53 cm in width) and shape. Parenchyma is homogenous. The prostatic urethra appears normal without evidence of dilation or obstruction.

The left kidney is normal size (3.40 cm in length); normal shape and architecture with smooth peripheral margins. There is a normal 1:3 cortex to medulla ratio with minimal loss of corticomedullary distinction. A thin hyperechoic medullary band is observed adjacent to the corticomedullary junction. There is no evidence of pyelectasia, nephroliths, infarcts or hydroureter. Renal vasculature is normal.

The right kidney is normal size (3.76 cm in length); normal shape and architecture with smooth peripheral margins. There is a normal 1:3 cortex to medulla ratio with minimal loss of corticomedullary distinction. A thin hyperechoic medullary band is observed adjacent to the corticomedullary junction. There is no evidence of pyelectasia, nephroliths, infarcts or hydroureter. Renal vasculature is normal.

*Adrenal Glands*

The left adrenal gland is mildly enlarged (0.46 cm at cranial pole) (0.55 cm at caudal pole) (1.62 cm in length); normal shape; homogenous parenchyma. The glandular echogenicity and detail are unremarkable. Capsule, cortex, and medullary definition are normal. The phrenicoabdominal vein and surrounding vasculature are normal.

The right adrenal gland is mildly enlarged (0.65 cm at cranial pole) (0.67 cm at caudal pole); normal shape; homogenous parenchyma. The glandular echogenicity and detail are unremarkable. Capsule, cortex, and medullary definition are normal. The phrenicoabdominal vein and surrounding vasculature are normal.

*Spleen*

The spleen is normal in size (0.76 cm in width at the level of the hilus) with a normal capsular contour. There is appropriate echogenicity and echotexture. No focal lesions are observed. Splenic vasculature is normal.

*Liver*

The liver is subjectively prominent to enlarged with swollen to slightly irregular peripheral contours. The parenchyma is isoechoic relative to the spleen. Numerous varying sized heterogeneous nodules are



**PATIENT**

Gino Rivera

observed throughout the organ. Vascular and biliary tracts are of normal volume with no evidence of congestion. The gall bladder lumen is moderately distended. The wall is thin and smooth. A moderate to large amount of aggregated echogenic partially dependent to suspended sludge is observed within the lumen. The cystic and common bile ducts are normal/not seen.

**SPECIES**

Canine

**Gastrointestinal**

The gastric lumen is not distended. The gastric wall is normal in thickness with a normal layering pattern. The small intestinal lumen is not dilated. The small intestinal wall thickness is normal with a normal layering pattern and appropriate mural detail. Discreet masses are not identified. The ileocecal colic junction is normal. The wall of the descending colon is mildly thickened (up to 0.36 cm) with a prominent submucosal layer. A small amount of fluid is observed within the lumen. No obstructive disease is noted.

**BREED**

Yorkshire Terrier

**SEX**

Male

**Pancreas**

The base and limbs of the pancreas are visible with normal curvilinear peripheral contours. The parenchyma is largely isoechoic relative to surrounding omental fat and slightly mottled in appearance. The pancreatic duct is visible but not overtly dilated. There is no evidence of peripancreatic inflammation or effusion.

**AGE**

6 Yrs.

**Free Abdomen**

**WEIGHT**

6.2 lbs.

There is no evidence of free fluid. The medial iliac lymph nodes are prominent in size, the largest measuring 1.16 cm in length. A few prominent mesenteric lymph nodes are also seen, the largest measuring 0.65 cm in length. Surrounding mesentery is hyperechoic.

**INTERPRETED BY**

Andrea Nicastro, DVM,  
Diplomate ACVIM  
(Small Animal Internal  
Medicine)

**ULTRASONOGRAPHIC FINDINGS**

**Primary Findings:**

- The diffuse hepatic nodules are concerning for infiltrative neoplasia. However, multifocal inflammatory disease +/- fibrosis cannot be completely excluded. Changes are similar to the previous sonogram.
- The descending colonic wall changes are most consistent with an inflammatory process with a lower possibility of emerging neoplasia.
- The prominent abdominal lymph nodes are most consistent with reactive lymphadenitis or lymphoid hyperplasia. Neoplastic infiltration is considered less likely.
- Gallbladder sludge. Differentials include cholestasis, early mucocele formation, secondary to fasting, other. Changes are similar to slightly worse compared to the previous sonogram.
- The bilateral adrenomegaly is most consistent with a hyperplasia with a low possibility of emerging neoplasia.

**Secondary Findings:**

- Age-related pancreatic remodeling. Low-grade pancreatitis may be present, particularly if the patient exhibits discomfort on cranial abdominal palpation.
- Minor age-related degenerative renal changes.

**IMAGING PERFORMED BY**

Dr. Ferrer

**HOSPITAL NAME**

Paseos VC

**REFERRING VET**

Dr. Ferrer

**INVOICE**

12895

**DATE**

1/24/2022



## PATIENT

Gino Rivera

## SPECIES

Canine

## BREED

Yorkshire Terrier

## SEX

Male

## AGE

6 Yrs.

## WEIGHT

6.2 lbs.

## INTERPRETATION OF THE FINDINGS & FURTHER RECOMMENDATIONS

- Regarding the diarrhea, consider the following:
  - Fecal PCR infectious disease panel.
  - A fecal evaluation for ova/Giardia, preferably on a pre-Fenbendazole sample.
  - GI panel (sent to Texas A&M).
  - A 6-week limited antigen diet trial to assess for food allergies
  - Depending on the results of the above diagnostics as well as the Panacur/Proviaible trial, endoscopic or surgical gastrointestinal biopsies may be necessary to get a definitive diagnosis. Endoscopy is the safest method for biopsying the colon.
- Regarding the hepatic nodules, a fine needle aspirate is recommended (if clotting status is appropriate). If cytology results are inconclusive, liver biopsies may be necessary to get a definitive diagnosis.
- Three-view thoracic radiographs should be performed to assess for pulmonary metastatic disease prior to anesthesia.
- Regarding the gallbladder changes, consider initiation of Ursodiol therapy. Alternatively, a repeat ultrasound in 2-3 weeks, preferably 2 hours post small meal can be considered. If gallbladder changes are similar to the current scan, consider initiation of Ursodiol at that time.

## INTERPRETED BY

Andrea Nicastro, DVM,  
Diplomate ACVIM  
(Small Animal Internal  
Medicine)

## IMAGING PERFORMED BY

Dr. Ferrer

## HOSPITAL NAME

Paseos VC

## REFERRING VET

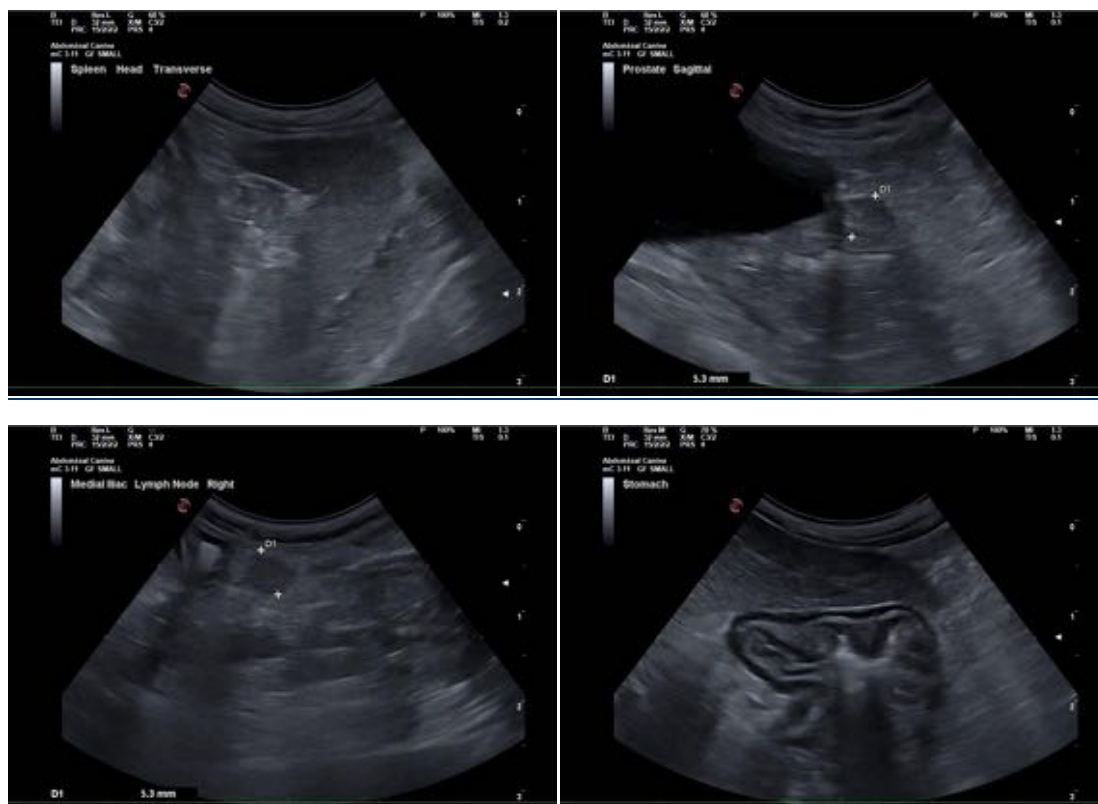
Dr. Ferrer

## INVOICE

12895

## DATE

1/24/2022





## PATIENT

Gino Rivera

## SPECIES

Canine

## BREED

Yorkshire Terrier

## SEX

Male

## AGE

6 Yrs.

## WEIGHT

6.2 lbs.

## INTERPRETED BY

Andrea Nicastro, DVM,  
Diplomate ACVIM  
(Small Animal Internal  
Medicine)

## IMAGING PERFORMED BY

Dr. Ferrer

## HOSPITAL NAME

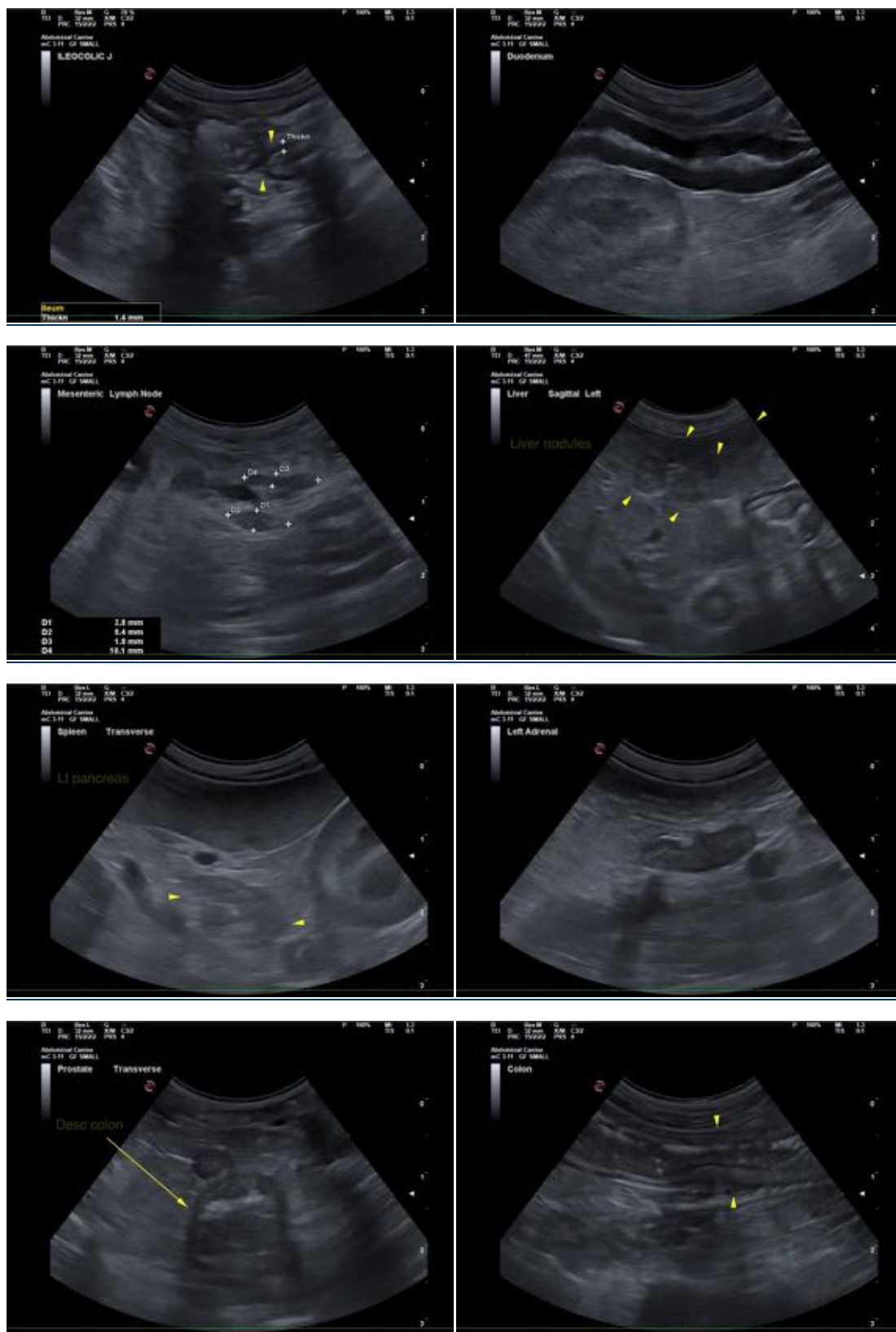
Paseos VC

## REFERRING VET

Dr. Ferrer

## INVOICE

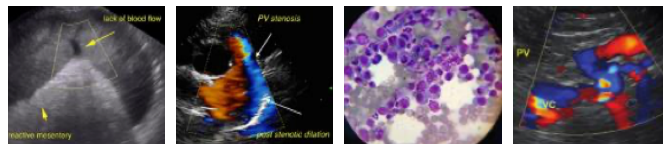
12895



The information and recommendations provided are based on the images presented by the referring

## DATE

1/24/2022



**PATIENT**

Gino Rivera

veterinarian/sonographer. No evaluation can be communicated regarding pathology that was not visible in the image/video clips provided.

Thank you for this referral. If the clinical or image interpretation does not parallel your findings or if I can be of any further assistance please contact me.

**SPECIES**

Canine

Andrea Nicastro, DVM, Diplomate ACVIM (*Small Animal Internal Medicine*)

**BREED**

Yorkshire Terrier

Andrea.nicastro@sonopath.com

**SEX**

Male

**AGE**

6 Yrs.

**WEIGHT**

6.2 lbs.

**INTERPRETED BY**

Andrea Nicastro, DVM,  
Diplomate ACVIM  
(*Small Animal Internal  
Medicine*)

**IMAGING  
PERFORMED BY**

Dr. Ferrer

**HOSPITAL NAME**

Paseos VC

**REFERRING VET**

Dr. Ferrer

**INVOICE**

12895

**DATE**

1/24/2022