

**DATE PRESENTING CLINICAL SIGNS**

9/16/21

History: Liver FNA

**CYTOLOGY SUBMISSION**

FNA of Liver

**INTERPRETED BY**

L.D. McGill, DVM,  
Ph.D., DACVP

**OBSERVATIONS**

Liver: Submitted our 5 excellent images of moderate collections of hepatocytes and other cells from the liver in Aerial. The cellularity includes excellent hepatocytes with granularity and focal areas of vacuolization. There are scattered inflammatory cells in the surrounding RBCs which include neutrophils and lymphocytes. There are no changes that would suggest malignancy or sepsis in this collection.

**PATIENT**

Aerial Lanini

**INTERPRETATION OF THE FINDINGS & FURTHER RECOMMENDATIONS**

**SPECIES**

Liver - Hepatocellular granularity with focal vacuolization and mild chronic suppurative inflammation.

Canine

**COMMENTS**

The hepatocytes demonstrate granularity and vacuolization. The vacuolization suggests some type of metabolic challenge including the potential of steroid hepatopathy. Other types of changes are not identified. There is certainly no evidence of malignancy or sepsis. Inflammation is present. Leptospirosis is possible but generally the inflammation is more severe than we see in this collection. My concern is that the liver changes are likely secondary to problems in other organs including the intestine, pancreas or possibly steroid hepatopathy. Other pharmaceutical therapy can cause this type of change in hepatocytes. Your understanding of the history in Aerial may be beneficial in confirming a reason for this hepatocellular vacuolization.

**BREED**

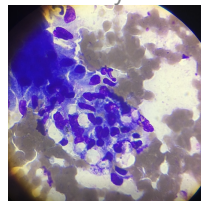
Yorkshire

**SEX**

Male Neutered

**AGE**

11y



**WEIGHT**

13.5 lbs

Image shows hepatocytes with granularity above and vacuolization below. Inflammatory cells are associated with these hepatocytes collected from Aerial.

**The information and recommendations provided are based on the images presented by the referring veterinarian. No evaluation can be communicated regarding pathology that was not visible in the image/video clips provided.**

**HOSPITAL NAME**

Eugene Animal Hospital

Thank you for this referral. If the clinical or image interpretation does not parallel your findings or if I can be of any further assistance please contact me.

**REFERRING VET**

Dr. Morrison

**L.D. McGill, DVM, Ph.D., DACVP**

8288 Top of the World Drive  
Cottonwood Heights, UT 84121  
ldmcgill.vetpath@gmail.com  
cell: 801-865-1220

**INVOICE NUMBER**

70406



**DATE**

9/16/21

**INTERPRETED BY**

L.D. McGill, DVM,  
Ph.D, DACVP

**PATIENT**

Aerial Lanini

**SPECIES**

Canine

**BREED**

Yorkshire

**SEX**

Male Neutered

**AGE**

11y

**WEIGHT**

13.5 lbs

**HOSPITAL NAME**

Eugene Animal Hospital

**REFERRING VET**

Dr. Morrison

**INVOICE NUMBER**

70406