



DATE PRESENTING CLINICAL SIGNS

8/27/21

History: two nights ago around 2:30am is when P woke up O by groaning and vocalizing, O noticed shallow and fast breathing and tachycardia. Looking better today. Wasn't drinking much water but today he did drink a good amount. Seems very uncomfortable, hesitant, tender.

INTERPRETED BY

L.D. McGill, DVM,
Ph.D, DACVP

Hasn't eaten for 2 days, had a small taste of biscuits and gravy this AM
Pee ok, huge bowel movement yesterday
Running around the patio about 2 days ago and slipped/fell
Drooling more excessively the last couple days
Elevated ALP-272, all other values within reference interval.

PATIENT

Marley Huntington

CYTOLOGY SUBMISSION

FNA of Lung

SPECIES

Canine

OBSERVATIONS

Lung aspirate: Submitted our 3 excellent videos of excellent collections of cells from a mass in the lung of Marley. There are packets of cells scattered throughout a red blood cell smear. The packets of cells are aggregated epithelial cells that demonstrate anisocytosis and anisokaryosis. There are large numbers of the cells in several fields. Other fields have smaller aggregates and there are individualized cells as well. Interspersed in the red blood cells are scattered neutrophils and macrophages.

BREED

Poodle

INTERPRETATION OF THE FINDINGS & FURTHER RECOMMENDATIONS

Lung mass - Carcinoma with secondary inflammation and hemorrhage

SEX

Male Neutered

COMMENTS

The clumping of the cells supports a carcinoma collected from the lung tissue. The specific cell of origin is not identified but it could be primary pulmonary tissue or secondary and metastatic. There is some mild inflammation. If the mass is localized, excision can be considered but in the long run an unfavorable prognosis is warranted. With this excellent collection of cells, a pulmonary carcinoma in Marley is essentially a confirmed diagnosis.

AGE

13y

WEIGHT

47.1

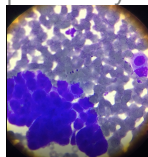


Image showing a group of carcinoma cells in the collection from the lung in Marley. They are aggregating in variable clumps.

HOSPITAL NAME

Pleasant Hill Animal
Hospital

The information and recommendations provided are based on the images presented by the referring veterinarian. No evaluation can be communicated regarding pathology that was not visible in the image/video clips provided.

REFERRING VET

Dr. Hans Larsen

Thank you for this referral. If the clinical or image interpretation does not parallel your findings or if I can be of any further assistance please contact me.

INVOICE NUMBER

70400



DATE L.D. McGill, DVM, Ph.D., DACVP

8/27/21
8288 Top of the World Drive
Cottonwood Heights, UT 84121
ldmcgill.vetpath@gmail.com
cell: 801-865-1220

INTERPRETED BY

L.D. McGill, DVM,
Ph.D., DACVP

PATIENT

Marley Huntington

SPECIES

Canine

BREED

Poodle

SEX

Male Neutered

AGE

13y

WEIGHT

47.1

HOSPITAL NAME

Pleasant Hill Animal
Hospital

REFERRING VET

Dr. Hans Larsen

INVOICE NUMBER

70400