

DATE PRESENTING CLINICAL SIGNS

8/22/22 History: History: weight loss and acute diarrhea Current Medications probiotic
Abnormal PE/Chem/CBC/UA Results: -WBC 22K, elevated eos 2.4K and monos 2.4K

INTERPRETED BY CYTOLOGY SUBMISSION

L.D. McGill, DVM,
Ph.D, DACVP
FNA of Intestinal wall mass

OBSERVATIONS

PATIENT

Abby Ortman

SPECIES

Feline

Intestinal wall aspirate: Submitted are 6 excellent videos of excellent to moderate collections of cells from the intestinal mass in Abby. The most cellular collections are excellent collections of round cells from the intestinal mass. These cells have minimal cytoplasm with rounded nuclei. Where identified, the cytoplasm is bluish gray. These are most characteristic of small to intermediate sized lymphocytes. Large atypical cells are not identified. There are smears that have very few of these cells but they have large numbers of erythrocytes and scattered inflammatory cells including eosinophils. This is likely secondary to the mass.

INTERPRETATION OF THE FINDINGS & FURTHER RECOMMENDATIONS

BREED

DSH

Intestinal wall mass - Small cell to intermediate cell lymphoma.

SEX

FS

AGE

10y

COMMENTS

This cellularity in the very densely cellular collections are characteristic of lymphoma. This appears to be a small to intermediate cell lymphoma. There is research to suggest that these masses can be excised and prolong the life of Abby. Very likely lymphoma will occur again in the future but hopefully this is farther along in Abby's life. Other tissues may be involved but most commonly intestinal lymphoma is limited to the intestine and does not involve the regional lymph nodes. The regional lymph nodes often respond to inflammation as a result of the mass. A guarded to unfavorable prognosis is warranted due to the presence of the lymphoma in this intestinal wall biopsy from Abby.

WEIGHT

11.5 lbs

HOSPITAL NAME

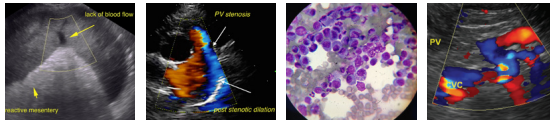
Willakenzie Animal
Clinic

REFERRING VET

Dr. Brandt

INVOICE NUMBER

40583



DATE

8/22/22

INTERPRETED BY

L.D. McGill, DVM,
Ph.D, DACVP

PATIENT

Abby Ortman

SPECIES

Feline

BREED

DSH

SEX

FS

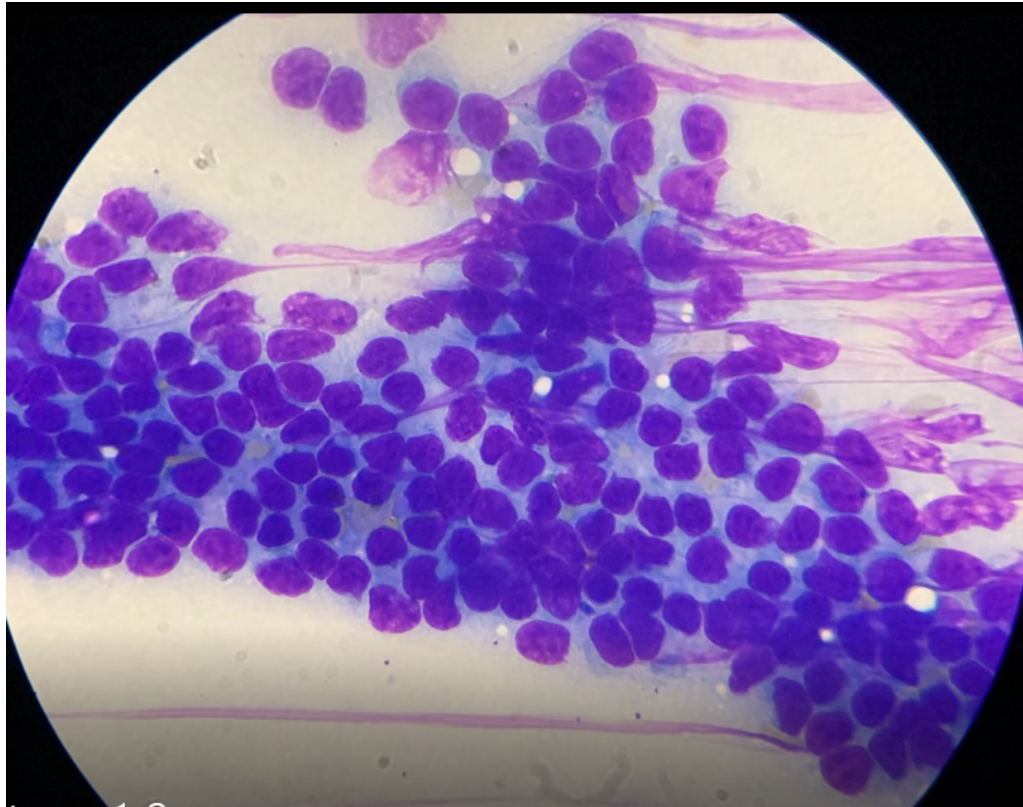


Image shows a representative collection of cells from the intestinal wall mass in Abby. The strung out material is nuclear material that is smudged. The majority of the cells are well preserved.

AGE

10y

The information and recommendations provided are based on the images presented by the referring veterinarian. No evaluation can be communicated regarding pathology that was not visible in the image/video clips provided.

WEIGHT

11.5 lbs

Thank you for this referral. If the clinical or image interpretation does not parallel your findings or if I can be of any further assistance, please contact me.

HOSPITAL NAME

Willakenzie Animal
Clinic

L.D. McGill, DVM, Ph.D., DACVP
8288 Top of the World Drive
Cottonwood Heights, UT 84121
ldmcgill.vetpath@gmail.com
cell: 801-865-1220

REFERRING VET

Dr. Brandt

INVOICE NUMBER

40583