

DATE 8-18-21 **PRESENTING CLINICAL SIGNS** Lethargy, inappetence with frequent vomiting; hx of squamous cell carcinoma; anemia on previous BW, US showed marked splenic enlargement

INTERPRETED BY L.D. McGill, DVM, Ph.D, DACVP **CYTOLOGY SUBMISSION** FNA of spleen

PATIENT Zena Crutcher **OBSERVATIONS** Spleen: Submitted are 2 excellent videos of excellent collections of cells from the spleen in Zena. There are large numbers of round cells that are extremely varied in size and shape. Many of these cells have purple to metachromatic granules in their cytoplasm. Many are irregularly granulated. Some of these cells appear to be phagocytosing fluid or red blood cells. Scattered smaller cells with granular cytoplasm are also identified. These cells are characteristic mast cells. There are a few other cells but most of the cells in these collections are feline mast cells.

SPECIES feline **INTERPRETATION OF THE FINDINGS & FURTHER RECOMMENDATIONS** Spleen - Splenic mast cell tumor

BREED DSH **COMMENTS**

SEX FS . This is an excellent collection of mast cells from the spleen in Zena. These mast cells are extremely pleomorphic which supports neoplasia. Whether this is the only location for mast cell neoplasia or if there are others in the abdominal cavity you will need to evaluate further. Splenectomy in cats with mast cell disease will often add to the lifetime of the cat but very likely in the future, Xena will succumb to mast cell disease. In other words an unfavorable prognosis for the long term is warranted.

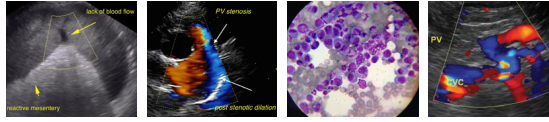
AGE 13 years **The information and recommendations provided are based on the images presented by the referring veterinarian. No evaluation can be communicated regarding pathology that was not visible in the image/video clips provided.**

WEIGHT 10.6# **Thank you for this referral. If the clinical or image interpretation does not parallel your findings or if I can be of any further assistance please contact me.**

HOSPITAL NAME The Veterinary Hospital **L.D. McGill, DVM, Ph.D., DACVP**
8288 Top of the World Drive
Cottonwood Heights, UT 84121
ldmcgill.vetpath@gmail.com
cell: 801-865-1220

REFERRING VET Dr. Berman

INVOICE NUMBER 80288



DATE

8-18-21

INTERPRETED BY

L.D. McGill, DVM,
Ph.D., DACVP

PATIENT

Zena Crutcher

SPECIES

feline

BREED

DSH

SEX

FS

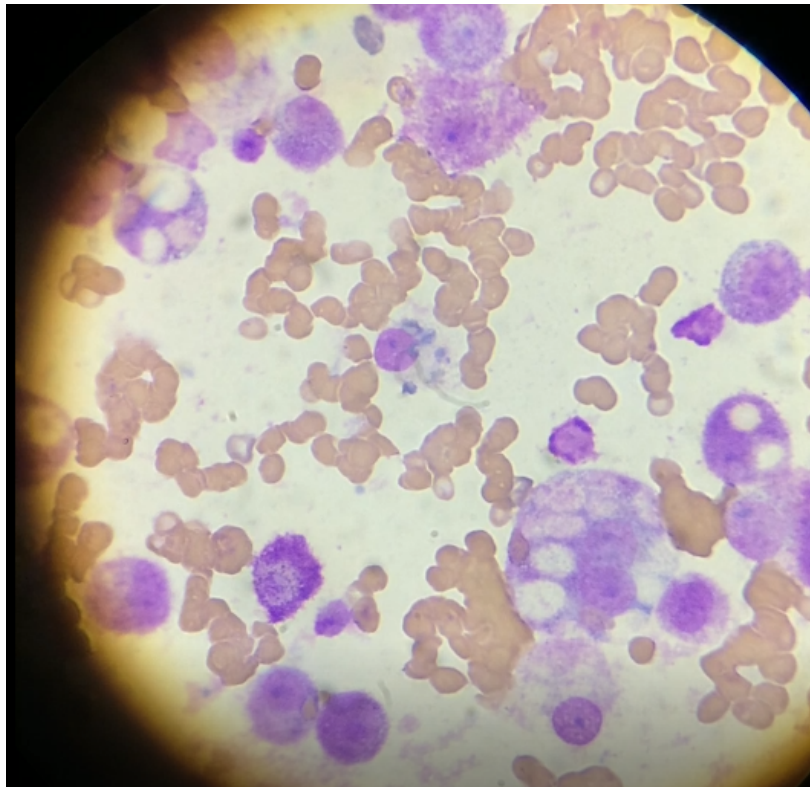


Image shows a representative field of mast cells with irregular sizes and shapes. Some of the cells are phagocytic.

AGE

13 years

WEIGHT

10.6#

HOSPITAL NAME

The Veterinary Hospital

REFERRING VET

Dr. Berman

INVOICE NUMBER

80288