

DATE **PRESENTING CLINICAL SIGNS**
8-18-21 History of PU/PD, inappropriate urination, periodic lameness, overweight, DJD left stifle.

INTERPRETED BY **CYTOLOGY SUBMISSION**
L.D. McGill, DVM, Ph.D, DACVP FNA of spleen

L.D. McGill, DVM,
Ph.D, DACVP

PATIENT **OBSERVATIONS**
Roxy Davenport Spleen: Submitted are 3 excellent videos of moderate collections of cells from the spleen in Roxy. There is a mixture of cells throughout all of the videos. They include neutrophils as a prominent cellularity with scattered nucleated RBCs, macrophages and some reactive lymphoid cells. The neutrophils suggest inflammation. Many of the macrophages contain hemosiderin supporting erythrophagocytosis. There are no neoplastic characteristics in the collection.

SPECIES **INTERPRETATION OF THE FINDINGS & FURTHER RECOMMENDATIONS**
Canine Spleen - Chronic suppurative splenitis with evidence of erythrophagocytosis and probable hemolytic change.

BREED **COMMENTS**
Miniature Schnauzer The cellularity supports an inflammatory process in the spleen. This inflammatory process could be from any reaction in Roxy. It could be draining from the pancreas or intestine or only be the result of a hemolytic process. There is evidence of hemolysis or erythrophagocytosis but the cause for this is not identified. There was one clump of cells that suggested fibrohistiocytic nodules but this is not specific. There is no suggestion of malignancy or sepsis.

SEX
FS

AGE **The information and recommendations provided are based on the images presented by the referring veterinarian. No evaluation can be communicated regarding pathology that was not visible in the image/video clips provided.**
13 years

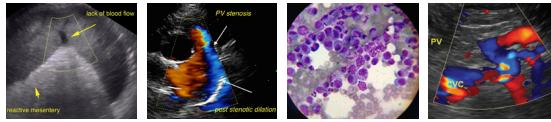
WEIGHT Thank you for this referral. If the clinical or image interpretation does not parallel your findings or if I can be of any further assistance please contact me.

23.6#

HOSPITAL NAME **L.D. McGill, DVM, Ph.D., DACVP**
Sutherlin Veterinary Hospital 8288 Top of the World Drive
Cottonwood Heights, UT 84121
ldmcgill.vetpath@gmail.com
cell: 801-865-1220

REFERRING VET
Dr. Herrera

INVOICE NUMBER
80290



DATE

8-18-21

INTERPRETED BY

L.D. McGill, DVM,
Ph.D, DACVP

PATIENT

Roxy Davenport

SPECIES

Canine

BREED

Miniature Schnauzer

SEX

FS

AGE

13 years

WEIGHT

23.6#

HOSPITAL NAME

Sutherland Veterinary
Hospital

REFERRING VET

Dr. Herrera

INVOICE NUMBER

80290

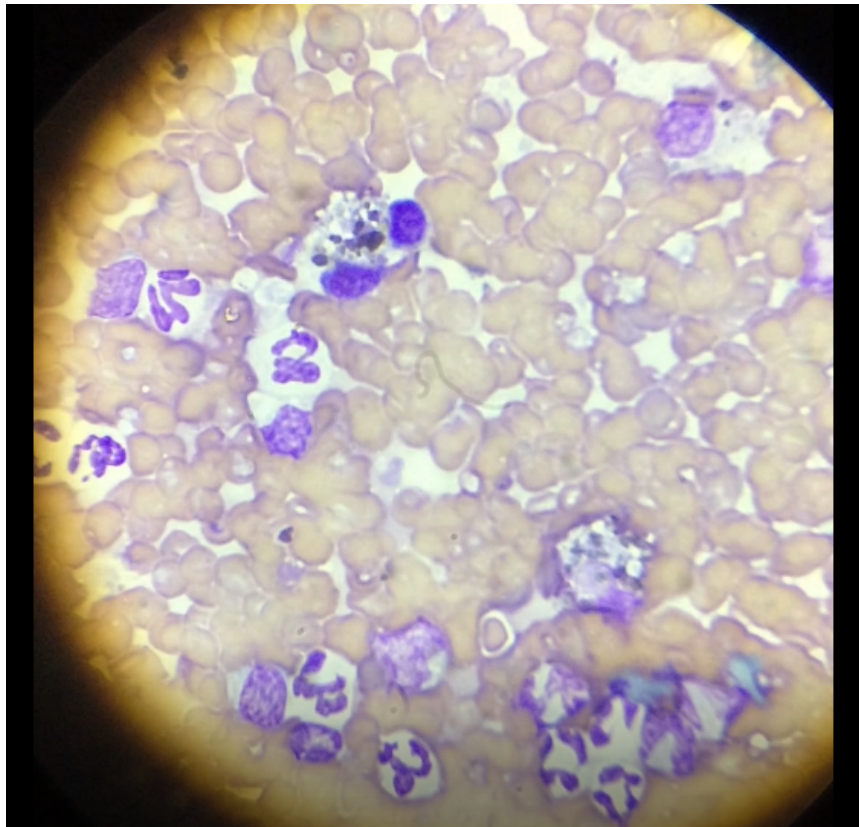


Image shows neutrophils and macrophages with hemosiderin and scattered nucleated RBCs collected from the spleen in Roxy.