

**DATE** **PRESENTING CLINICAL SIGNS**  
8-18-21 Recent vomiting, increasing in frequency; periods of lethargy; slightly underweight, MM slightly pale, intestines slightly thickened on palpation.

**INTERPRETED BY** **CYTOLOGY SUBMISSION**  
L.D. McGill, DVM, Ph.D., DACVP FNA ICJ/colonic mass found on Ultrasound

**PATIENT** **OBSERVATIONS**  
Adina Stroda Ileoceocolic mass: Submitted are 2 excellent videos of moderate to excellent collections of cells from the ileoceocolic junction in Adina. The cellularity in the first image demonstrates large numbers of lymphoid cells, many of which are quite large and irregular. They demonstrate prominent nucleoli. There are scattered mitotic figures. There is some inflammation associated with the reaction but the major process appears to be the large irregular lymphoid cells that are very prominent in many fields.

**SPECIES** **INTERPRETATION OF THE FINDINGS & FURTHER RECOMMENDATIONS**  
feline Ileoceocolic mass: Consistent with high-grade lymphoma

**BREED** **COMMENTS**  
DSH Sample text. Sample text. The cellularity in this collection strongly supports a high-grade lymphoma. There is some secondary inflammation. Immunophenotyping of the cells may be of benefit but this process does not seem to work as well in the cat as it does in the dog. It may not add to prognostication. Excision of the mass may prolong life in Adina. An unfavorable prognosis is warranted for long-term life.

**SEX**  
FS

**AGE** **The information and recommendations provided are based on the images presented by the referring veterinarian. No evaluation can be communicated regarding pathology that was not visible in the image/video clips provided.**  
14 years Thank you for this referral. If the clinical or image interpretation does not parallel your findings or if I can be of any further assistance please contact me.

**WEIGHT**  
7# **L.D. McGill, DVM, Ph.D., DACVP**  
8288 Top of the World Drive  
Cottonwood Heights, UT 84121  
**HOSPITAL NAME** ldmcgill.vetpath@gmail.com  
cell: 801-865-1220

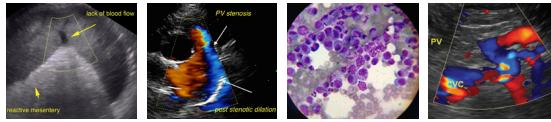
Santa Clara Animal Hospital

**REFERRING VET**

Dr. Brasted-Maki

**INVOICE NUMBER**

80289



**DATE**

8-18-21

**INTERPRETED BY**

L.D. McGill, DVM,  
Ph.D, DACVP

**PATIENT**

Adina Stroda

**SPECIES**

feline

**BREED**

DSH

**SEX**

FS

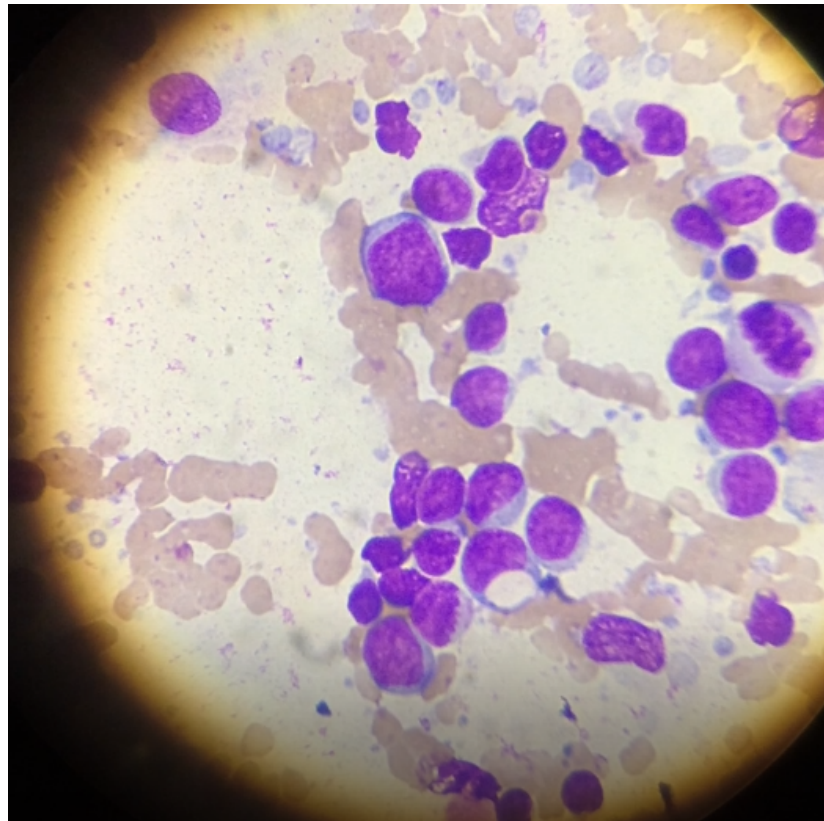


Image shows a representative group of cells from the mass in Adina. Note the large lymphoid cells and mitotic figure to the right side.

**AGE**

14 years

**WEIGHT**

7#

**HOSPITAL NAME**

Santa Clara Animal  
Hospital

**REFERRING VET**

Dr. Brasted-Maki

**INVOICE NUMBER**

80289