



DATE PRESENTING CLINICAL SIGNS

8/13/21

History: weight loss, inappetance, systolic murmur grade 4/6 has had previous echo and abdominal ultrasounds with you

INTERPRETED BY

L.D. McGill, DVM,
Ph.D, DACVP

CBC - slightly anemic- hct 33, rbc 4.88 Chem - marked hepatic disease - ALT >1000 (was 560 in 1/2021) AST 140, Alk Phos 498 (was 548) GGT 17 BUN is 58, creat is WNL at 1.4.

Current meds: Denamarin, spironolactone 25 mg-1/2 BID, sildenafil 10 mg BID, lasix 20mg q8 -12 hours, Vetmedin 3.75 mg - 1/2 BID, enalapril 5 mg SID

CYTOLOGY SUBMISSION

FNA of Spleen

PATIENT

Gracie Dechiara

OBSERVATIONS

Spleen: Submitted are 2 excellent videos of moderate to excellent collections of cells from the spleen in Gracie. There are large numbers of round cells in all of the videos. The majority of the round cells are nucleated RBC series. They include all of the various stages present. Many macrophages contain hemosiderin. There are moderate to large numbers of neutrophils scattered throughout. Lymphoid cells are not prominent. There are packets of cells that include apparent spindloid cells and macrophages. Some of these cells contain hemosiderin pigment.

SPECIES

Canine

BREED

Schnauzer

INTERPRETATION OF THE FINDINGS & FURTHER RECOMMENDATIONS

Spleen - Moderate to marked extramedullary hematopoiesis with structures suggesting fibrohistiocytic nodules.

COMMENTS

SEX

FS

The changes in this collection suggest the likelihood of extensive extramedullary hematopoiesis with evidence of red cell degeneration. There are areas of fibrosis and inflammation which are likely phagocytosing red blood cells. There are no changes that support malignant criteria.

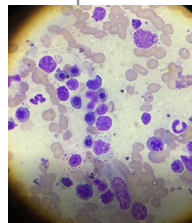
AGE

15 Years

There are changes that suggest the possibility of inflammation. This inflammation may be due to hemolytic changes or inflammation in other organs. I did not identify changes of sepsis. At this time I expect that these changes are secondary to hemolytic changes and inflammation in other parts of the abdominal cavity but not primary to the spleen.

WEIGHT

15 Pounds



HOSPITAL NAME

The Veterinary Hospital

Image shows many of the series of RBC development with macrophages and hemosiderin collected from Gracie. There are scattered neutrophils in this image.

REFERRING VET

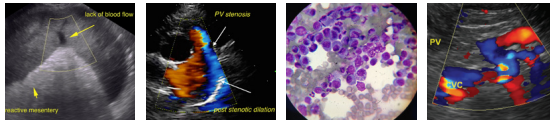
Dr. Johnson

The information and recommendations provided are based on the images presented by the referring veterinarian. No evaluation can be communicated regarding pathology that was not visible in the image/video clips provided.

Thank you for this referral. If the clinical or image interpretation does not parallel your findings or if I can be of any further assistance please contact me.

INVOICE NUMBER

70398



DATE L.D. McGill, DVM, Ph.D., DACVP

8/13/21
8288 Top of the World Drive
Cottonwood Heights, UT 84121
ldmcgill.vetpath@gmail.com
cell: 801-865-1220

INTERPRETED BY

L.D. McGill, DVM,
Ph.D., DACVP

PATIENT

Gracie Dechiara

SPECIES

Canine

BREED

Schnauzer

SEX

FS

AGE

15 Years

WEIGHT

15 Pounds

HOSPITAL NAME

The Veterinary Hospital

REFERRING VET

Dr. Johnson

INVOICE NUMBER

70398