



**DATE PRESENTING CLINICAL SIGNS**

8/13/21

History: Presented for lethargy, increased water drinking. Mid abdominal mass palpated but could not R/O splenic positioning (folding)  
Mild non-regenerative anemia, mild neutropenia and lymphopenia. Mild elevation of ALT, ALkPhos

**INTERPRETED BY CYTOLOGY SUBMISSION**

L.D. McGill, DVM,  
Ph.D., DACVP

FNA of spleen

**OBSERVATIONS**

**PATIENT**

Kobe Burroughs

Spleen: Submitted are 3 videos of excellent collections of cells from the spleen in Kobe. The cells are all round cells. There are scattered nucleated RBCs, plasma cells and macrophages. There are large numbers of large cells with large nuclei that are 4-6 times the size of RBCs and there are prominent mitotic figures particularly in video 2. The cytoplasm is prominent and gray-blue. There are vacuoles in the cytoplasm of these cells. They appear to be atypical lymphocytes.

**SPECIES**

Canine

**INTERPRETATION OF THE FINDINGS & FURTHER RECOMMENDATIONS**

Spleen: Aggregates of cells suggestive of early high-grade lymphoma with extramedullary hematopoiesis.

**BREED**

Rottweiler

**COMMENTS**

The cellularity in many fields supports early lymphoma of a high-grade nature. It has not effaced the entire cellularity. PCR on these slides may confirm the diagnosis. Splenectomy may be considered. Recollection of cells for flow cytometry may be confirmatory. I am concerned about lymphoma in Kobe but cannot confirm the diagnosis since the cells are not effacing the splenic structure. The testing suggested may be helpful to decide the next step. A guarded prognosis is warranted with these cells present on the videos.

**SEX**

Male Neutered

**AGE**

8 Years

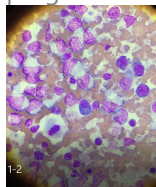


Image shows a field of large lymphoid cells with a mitotic figure collected from Kobe. There are scattered NRBCs in the image also.

**WEIGHT**

87 Pounds

**The information and recommendations provided are based on the images presented by the referring veterinarian. No evaluation can be communicated regarding pathology that was not visible in the image/video clips provided.**

**HOSPITAL NAME**

South Willamette  
Veterinary Clinic

Thank you for this referral. If the clinical or image interpretation does not parallel your findings or if I can be of any further assistance, please contact me.

**L.D. McGill, DVM, Ph.D., DACVP**

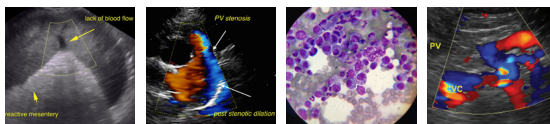
**REFERRING VET**

Dr. Willaman

8288 Top of the World Drive  
Cottonwood Heights, UT 84121  
ldmcgill.vetpath@gmail.com  
cell: 801-865-1220

**INVOICE NUMBER**

70396



**DATE**

8/13/21

**INTERPRETED BY**

L.D. McGill, DVM,  
Ph.D, DACVP

**PATIENT**

Kobe Burroughs

**SPECIES**

Canine

**BREED**

Rottweiler

**SEX**

Male Neutered

**AGE**

8 Years

**WEIGHT**

87 Pounds

**HOSPITAL NAME**

South Willamette  
Veterinary Clinic

**REFERRING VET**

Dr. Willaman

**INVOICE NUMBER**

70396