



**DATE PRESENTING CLINICAL SIGNS**

8/10/22

History: History: year long GI issues, vomits chronically. Takes Cerenia 2-3 times per week. Gradually losing weight. Abdominal palpation - one of the kidneys feels irregular  
Abnormal PE/Chem/CBC/UA Results: ABNORMAL Laboratory Findings Crea = 2.7. rest of lab work including UA are normal (USG =1.037) Current Medications cerenia

**INTERPRETED BY**

L.D. McGill, DVM,  
Ph.D, DACVP

**CYTOLOGY SUBMISSION**

FNA of Intestinal Mass & Right Kidney

**PATIENT OBSERVATIONS**

Scooter Burrell

Intestinal Mass: Submitted are 5 excellent videos of cells collected from the intestinal mass in Scooter. The cellularity is mainly that of a round cell proliferation. The round cells are regular in size and shape with prominent nuclei. Nucleoli are prominent. This cellularity is irregular with scattered inflammatory cells and scattered degenerate cells. The cellularity is demonstrating massive numbers of lymphoid cells which is not expected for an intestinal wall aspirate. The cellularity is varied throughout the collection.

**SPECIES**

Feline

Right Kidney Collection: Submitted are 4 excellent videos of minimal cellularity collected from the right kidney in Scooter. The cellularity is mixed. It includes neutrophils with scattered macrophages and even scattered lymphocytes. Smudged necrotic cells are present. Malignant characteristics are not identified in the cells in this collection.

**BREED**

DMH

**SEX**

Male Neutered

**INTERPRETATION OF THE FINDINGS & FURTHER RECOMMENDATIONS**

Intestinal mass - Round cell tumor consistent with intestinal lymphoma  
Right kidney collection - Minimal cellularity with cellular collection suggesting chronic suppurative inflammation.

**AGE**

7yrs

**COMMENTS**

The intestinal collection is most consistent with a probable high-grade lymphoma. This cellularity can be confirmed with immunophenotyping but with the massive numbers of lymphoid cells present, lymphoma is the most likely diagnosis. There is some secondary inflammation. These cells were not identified in the kidney collection. There is evidence of inflammation in the kidney and this could be secondary to the intestinal problem or primary. Due to the lymphoma in the intestine, an unfavorable prognosis is warranted. Excision of the mass may result in a favorable prognosis for a shorter period of time. The long term prognosis is unfavorable. The kidney changes can be a result of chronic inflammation and may be treatable.

**WEIGHT**

12lbs

**HOSPITAL NAME**

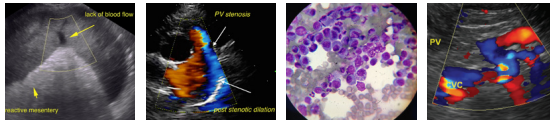
Q Street Animal Hospital

**REFERRING VET**

Dr. Bretschneider

**INVOICE NUMBER**

40578



**DATE**

8/10/22

**INTERPRETED BY**

L.D. McGill, DVM,  
Ph.D, DACVP

**PATIENT**

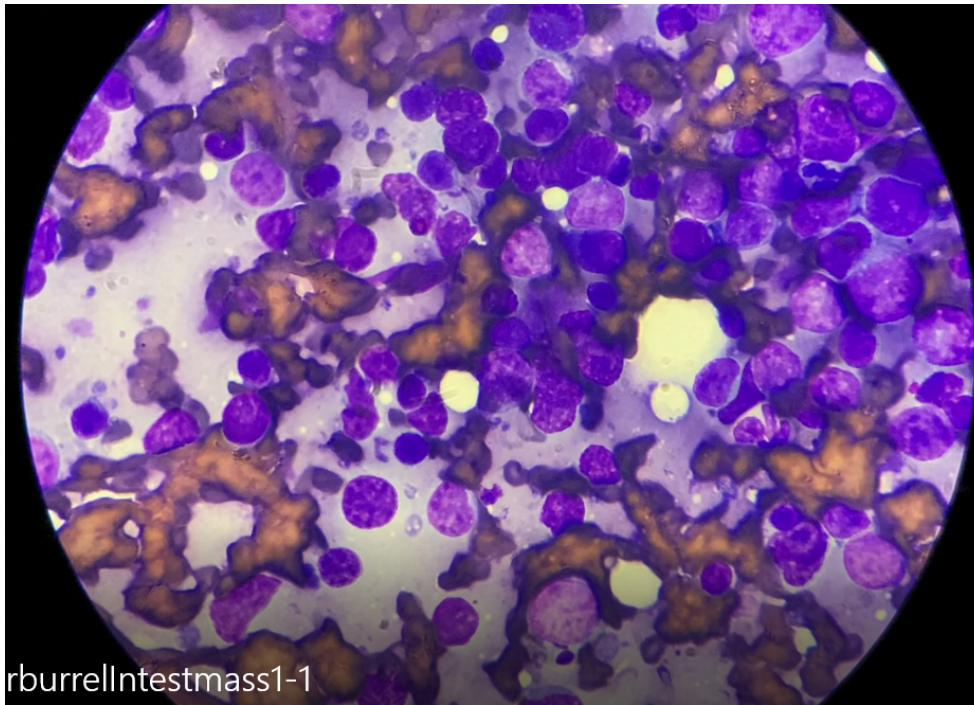
Scooter Burrell

**SPECIES**

Feline

**BREED**

DMH



rburrellIntestmass1-1

Image shows a group of round cells collected from the intestinal mass in Scooter. Note the large lymphoid cells with prominent nucleoli.

**SEX**

Male Neutered

**AGE**

7yrs

**WEIGHT**

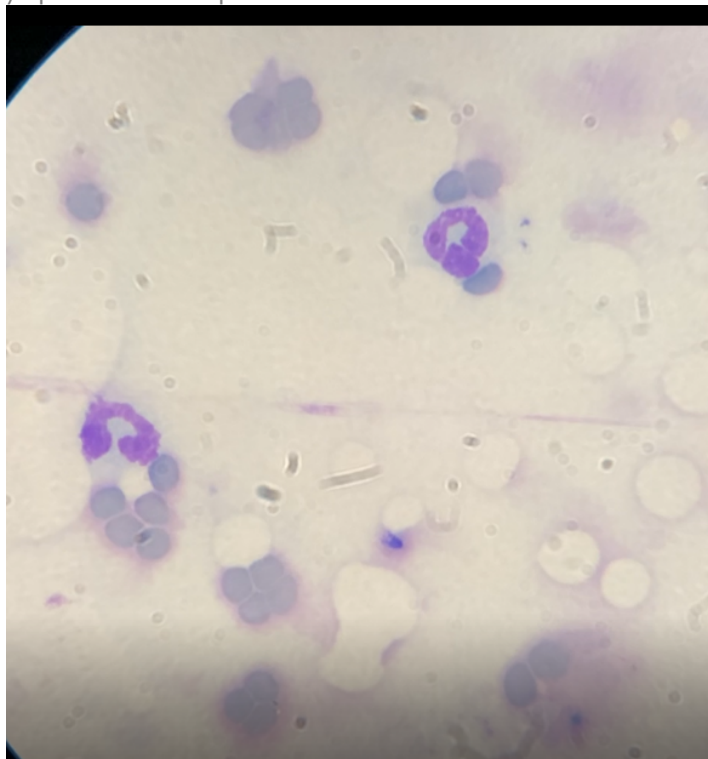
12lbs

**HOSPITAL NAME**

Q Street Animal Hospital

**REFERRING VET**

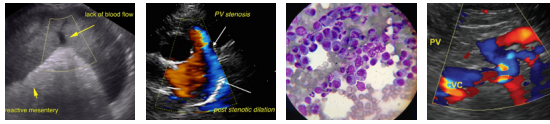
Dr. Bretschneider



**INVOICE NUMBER**

40578

Image shows a couple of neutrophils and RBCs collected from the right kidney in Scooter. There are minimal numbers of cells in this collection.



**DATE**

8/10/22

The information and recommendations provided are based on the images presented by the referring veterinarian. No evaluation can be communicated regarding pathology that was not visible in the image/video clips provided.

**INTERPRETED BY**

L.D. McGill, DVM,  
Ph.D., DACVP

Thank you for this referral. If the clinical or image interpretation does not parallel your findings or if I can be of any further assistance, please contact me.

**PATIENT**

Scooter Burrell

L.D. McGill, DVM, Ph.D., DACVP  
8288 Top of the World Drive  
Cottonwood Heights, UT 84121  
ldmcgill.vetpath@gmail.com  
cell: 801-865-1220

**SPECIES**

Feline

**BREED**

DMH

**SEX**

Male Neutered

**AGE**

7yrs

**WEIGHT**

12lbs

**HOSPITAL NAME**

Q Street Animal Hospital

**REFERRING VET**

Dr. Bretschneider

**INVOICE NUMBER**

40578