

DATE PRESENTING CLINICAL SIGNS

7/20/23

History: FNA of Panreas after ultrasound

INTERPRETED BY CYTOLOGY SUBMISSION

L.D. McGill, DVM,
Ph.D, DACVP

FNA of Panreas

PATIENT

Dippy Ryan

OBSERVATIONS

Pancreas: Submitted are 6 excellent videos of cells collected from the pancreatic cystic lesion in Dippy. The cellularity consists of large numbers of neutrophils interspersed with reactive macrophages and rare mature lymphocytes. The neutrophils are regular. Occasionally there are structures that suggest bacteria, but they are not present in the neutrophils. Occasionally some of the neutrophils are degenerate. There is no suggestion of malignancy.

SPECIES

Feline

INTERPRETATION OF THE FINDINGS & FURTHER RECOMMENDATIONS

BREED

DLH

Pancreas - Chronic pyogranulomatous inflammation with secondary necrosis and possible bacterial infection.

SEX

Male Neutered

COMMENTS

The cellularity in this collection is very characteristic of a chronic pancreatitis with suppurative inflammation. There are some changes that suggest bacterial infection. There is no suggestion of malignancy in this collection. Very likely the liver is responding secondarily to pancreatitis in this case. Treatment for pancreatitis and treatment for inflammation is encouraged. This is an excellent collection of cells from an inflammatory process in the pancreas. A guarded prognosis is warranted due to the chronic inflammation.

AGE

14y

WEIGHT

14

HOSPITAL NAME

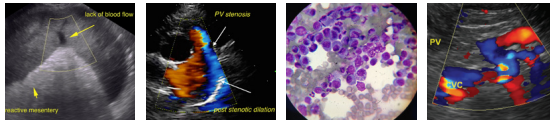
Q Street Animal Hospital

REFERRING VET

Dr. Bretschneider

INVOICE NUMBER

40780



DATE

7/20/23

INTERPRETED BY

L.D. McGill, DVM,
Ph.D, DACVP

PATIENT

Dippy Ryan

SPECIES

Feline

BREED

DLH

SEX

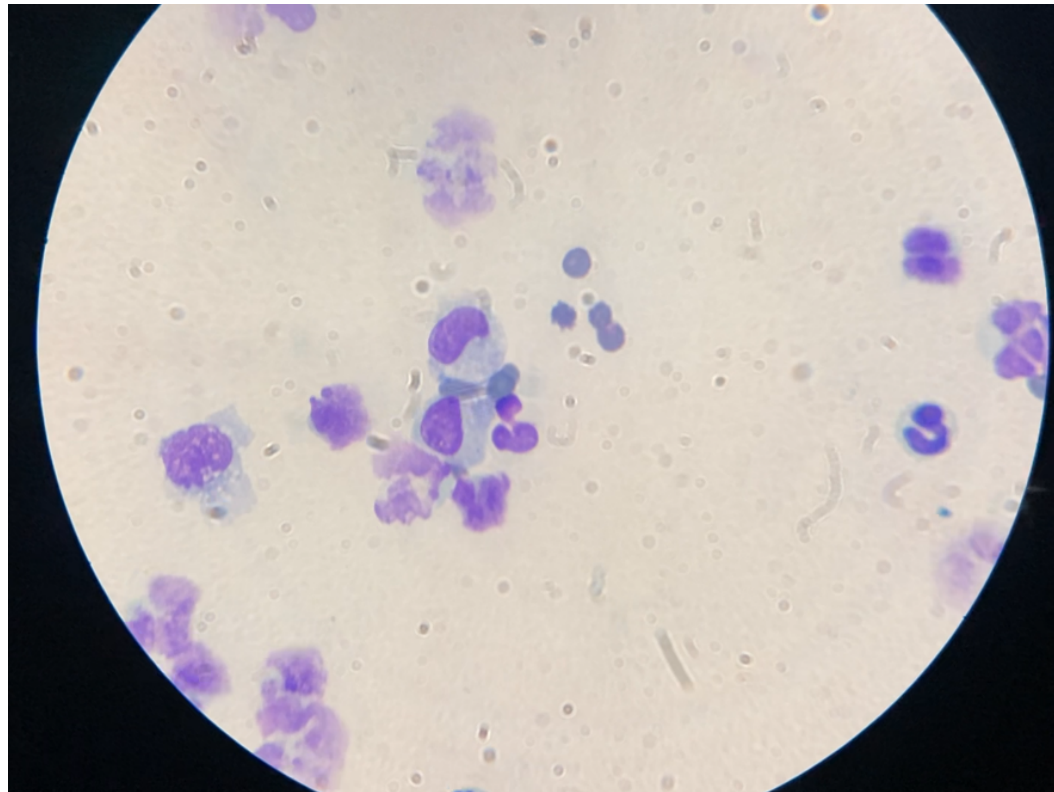
Male Neutered

AGE

14y

WEIGHT

14



The image shows macrophages with scattered neutrophils collected from the aspirate in the pancreas from Dippy. There is smudged nuclear degenerate debris in some locations. There are other fields that have many more neutrophils than this field, but this field demonstrates a mixture of cellularity.

The information and recommendations provided are based on the images presented by the referring veterinarian. No evaluation can be communicated regarding pathology that was not visible in the image/video clips provided.

Thank you for this referral. If the clinical or image interpretation does not parallel your findings or if I can be of any further assistance, please contact me.

HOSPITAL NAME

Q Street Animal Hospital

L.D. McGill, DVM, Ph.D., DACVP
8288 Top of the World Drive
Cottonwood Heights, UT 84121
ldmcgill.vetpath@gmail.com
cell: 801-865-1220

REFERRING VET

Dr. Bretschneider

INVOICE NUMBER

40780