

DATE PRESENTING CLINICAL SIGNS

6/12/22

Intermittent diarrhea for the past year, long hx of inappropriate urination.

INTERPRETED BY CYTOLOGY SUBMISSION

U/S Guided FNA: Intestinal wall

L.D. McGill, DVM,
Ph.D, DACVP

PATIENT

Alfredo Hancock

OBSERVATIONS

Intestinal wall aspirate: Submitted are 7 excellent videos of cells collected from the intestinal wall in Alfredo. The cellularity is moderate. Some fields have moderate numbers of cells and some have minimal numbers of cells. The cellularity in most fields is mixed. Neutrophils and macrophages are readily identified. There are some fields that demonstrate a few lymphoid cells but they are not the predominant cellularity. Malignant characteristics are not prominent. Due to the mixed cell collection, an inflammatory process is likely.

SPECIES

Feline

ULTRASONOGRAPHIC DIAGNOSIS

Severely thickened section of bowel with a prominent hypoechoic wall and hyperechoic thickened mucosa.

BREED

DSH

INTERPRETATION OF THE FINDINGS & FURTHER RECOMMENDATIONS

Intestinal wall aspirate - Consistent with pyogranulomatous inflammation.

SEX

Male Neutered

COMMENTS

The cellularity is mixed throughout this collection of cells. There are no cells that would support malignant characteristics. This inflammatory process is consistent with feline infectious peritonitis in the wall of the intestine. It could also be due to some type of bacterial infection or other inflammatory process. I am unable to identify malignant characteristics. These slides or other aspirates can be submitted to the laboratory for PCR testing. Alfredo should be evaluated for coronavirus infection. If that is very low, then further evaluation for intestinal inflammation is encouraged. With the cells identified in these excellent videos, an inflammatory process of a chronic nature appears to be the most likely process.

AGE

10 yrs

WEIGHT

7.8 lbs

HOSPITAL NAME

Q Street Animal Hospital

REFERRING VET

Dr. Bretschneider

INVOICE NUMBER

9093

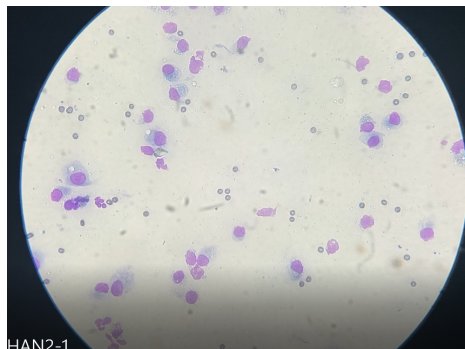
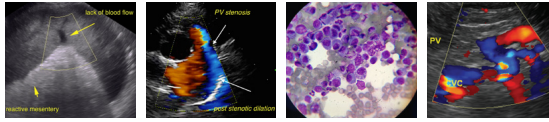


Image shows many macrophages with scattered neutrophils collected from the intestinal wall in Alfredo. Neoplastic characteristics are not identified.



DATE

6/12/22

INTERPRETED BY

L.D. McGill, DVM,
Ph.D, DACVP

The information and recommendations provided are based on the images presented by the referring veterinarian. No evaluation can be communicated regarding pathology that was not visible in the image/video clips provided.

Thank you for this referral. If the clinical or image interpretation does not parallel your findings or if I can be of any further assistance please contact me.

PATIENT

Alfredo Hancock

L.D. McGill, DVM, Ph.D., DACVP
8288 Top of the World Drive
Cottonwood Heights, UT 84121
ldmcgill.vetpath@gmail.com
cell: 801-865-1220

SPECIES

Feline

BREED

DSH

SEX

Male Neutered

AGE

10 yrs

WEIGHT

7.8 lbs

HOSPITAL NAME

Q Street Animal Hospital

REFERRING VET

Dr. Bretschneider

INVOICE NUMBER

9093