

DATE PRESENTING CLINICAL SIGNS

5/6/22 P has a long history (>1 yr) of picky eating on and off, waxing and waning lethargy and PU/PD. Last year O described a brief period of aggressive humping behaviors also.

INTERPRETED BY

L.D. McGill, DVM,
Ph.D, DACVP

Recently diagnosed mammary carcinoma, left mammary chain with firm masses (diagnosed through Lacuna FNA)

Long hx of KCS in left eye from removal of nictitans membrane during cherry eye procedure many years ago. Managed with BNP eye ointment and frequent lubrication of the eye, optimimmune.

Long history (>1 yr) Grade-IV-V systolic heart murmur; currently furosemide, pimobendan, benazepril.

PATIENT

Susie Leighton

Previous ACTH stim test-performed 11/10/21 was negative for Cushing's and Addison's. Last heat cycle in early April 2022

CYTOLOGY SUBMISSION

FNA of Liver Mass

SPECIES

Canine

OBSERVATIONS

Liver: Submitted are 6 good videos of moderate collections of hepatocytes with scattered aggregates of erythrocytes with inflammatory cells collected from the Susie. The hepatocytes demonstrate vacuolization in occasional cells. They are piled upon each other in irregular patterns. Many of the cells are quite small. The cellularity is varied with anisokaryosis and anisocytosis. In the surrounding red blood cells, there are scattered lymphocytes and neutrophils.

BREED

Boston Terrier

SEX

Female

INTERPRETATION OF THE FINDINGS & FURTHER RECOMMENDATIONS

Liver - Hepatocellular proliferation suggesting low-grade hepatocellular carcinoma or hepatocellular adenoma.

AGE

13yrs

COMMENTS

There is no suggestion of other infiltrating lesions into this liver tissue. The hepatocytes however demonstrate irregular patterns that suggest the possibility of a proliferative process within hepatocytes. Some of the characteristics suggest carcinoma but others are not as aggressive which could be a hepatocellular adenoma. Biopsy of this liver tissue is encouraged to confirm the diagnosis but there appears to be hepatocellular proliferation in the collection of hepatocytes submitted from Susie. A guarded to unfavorable prognosis is warranted.

WEIGHT

27.5lbs

HOSPITAL NAME

The Veterinary Hospital

REFERRING VET

Dr. Yomada

INVOICE NUMBER

40519



DATE

5/6/22

INTERPRETED BY

L.D. McGill, DVM,
Ph.D, DACVP

PATIENT

Susie Leighton

SPECIES

Canine

BREED

Boston Terrier

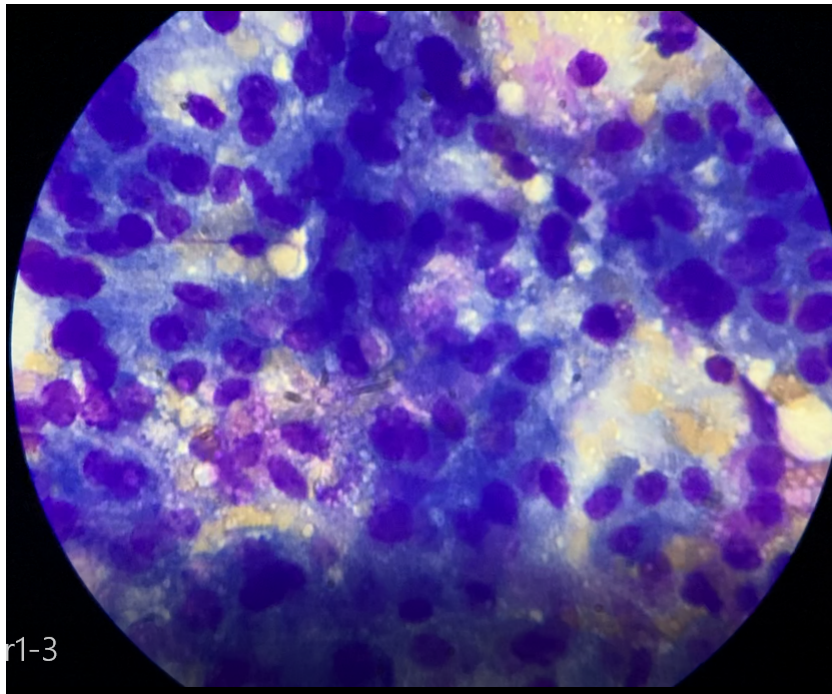


Image shows hepatocytes collected from the mass in the liver in Susie. The hepatocytes are piled upon each other and demonstrate anisokaryosis with vacuolization.

SEX

Female

The information and recommendations provided are based on the images presented by the referring veterinarian. No evaluation can be communicated regarding pathology that was not visible in the image/video clips provided.

AGE

13yrs

Thank you for this referral. If the clinical or image interpretation does not parallel your findings or if I can be of any further assistance, please contact me.

WEIGHT

27.5lbs

L.D. McGill, DVM, Ph.D., DACVP
8288 Top of the World Drive
Cottonwood Heights, UT 84121
ldmcgill.vetpath@gmail.com
cell: 801-865-1220

HOSPITAL NAME

The Veterinary Hospital

REFERRING VET

Dr. Yomada

INVOICE NUMBER

40519