

DATE PRESENTING CLINICAL SIGNS

3/23/22

History: Chronic liver enzyme elevation, initially responding to treatment with Ursodiol and Denamarin. Recently, liver enzymes have begun to rise again. Previous ultrasound 10-18-21.

INTERPRETED BY

L.D. McGill, DVM,
Ph.D, DACVP

CYTOLOGY SUBMISSION

FNA of Liver

OBSERVATIONS

Liver: Submitted is a single large video collected from cells aspirated from the liver in Patrick. There are hepatocytes scattered throughout the video. The hepatocytes demonstrate vacuolization and minimal granularity. There are very few inflammatory cells scattered throughout this collection in the surrounding red blood cells. There are no changes supporting malignancy or sepsis.

PATIENT

Patrick Stowe-Emerly

INTERPRETATION OF THE FINDINGS & FURTHER RECOMMENDATIONS

Liver - Moderate hepatocellular vacuolization and granularity with mild inflammation.

SPECIES

Canine

COMMENTS

The changes in this liver aspiration demonstrate secondary metabolic changes of a nonspecific nature. This could be secondary to problems in other organs such as the pancreas or intestine or could be due to primary liver metabolic changes including membrane leakage. There is no suggestion of neoplasia or sepsis. Very likely, Patrick will live a long life with these liver enzymes unless there is a problem in other organs that we have not identified. Continued monitoring is encouraged to hopefully identify a primary source of problems in Patrick.

BREED

Pomeranian

SEX

Male Neutered

AGE

6y

WEIGHT

16.8 lbs

HOSPITAL NAME

Q Street Animal Hospital

REFERRING VET

Dr. Hoerauf

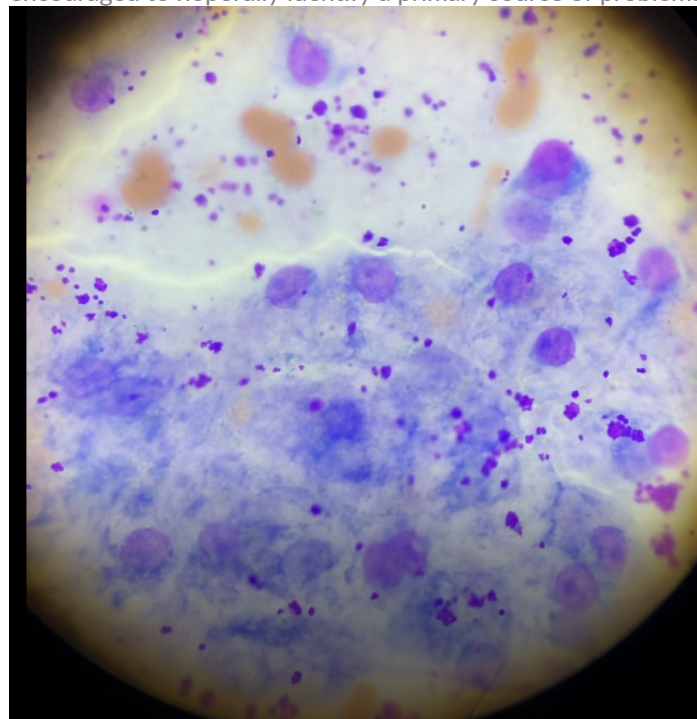


Image demonstrates hepatocellular vacuolization and some granularity from the liver in Patrick. There are a few lymphocytes associated. The purple granules are sonography gel.

INVOICE NUMBER

40485



DATE

3/23/22

The information and recommendations provided are based on the images presented by the referring veterinarian. No evaluation can be communicated regarding pathology that was not visible in the image/video clips provided.

INTERPRETED BY

L.D. McGill, DVM,
Ph.D., DACVP

Thank you for this referral. If the clinical or image interpretation does not parallel your findings or if I can be of any further assistance please contact me.

PATIENT

Patrick Stowe-Emery

L.D. McGill, DVM, Ph.D., DACVP
8288 Top of the World Drive
Cottonwood Heights, UT 84121
ldmcgill.vetpath@gmail.com
cell: 801-865-1220

SPECIES

Canine

BREED

Pomeranian

SEX

Male Neutered

AGE

6y

WEIGHT

16.8 lbs

HOSPITAL NAME

Q Street Animal Hospital

REFERRING VET

Dr. Hoerauf

INVOICE NUMBER

40485