

**DATE PRESENTING CLINICAL SIGNS**

2/28/23

History: P has been quickly losing weight, occasional vomiting of undigested food, not eating as much for 1 to 2 week duration.

On PE, P underweight, generalized muscle atrophy, dehydrated, greasy unkempt hair coat.

Ping pong ball sized firm mass palpated in the mid ventral abdomen.

**INTERPRETED BY**

L.D. McGill, DVM,  
Ph.D, DACVP

TP: 5.4

ALP 349

GGT 14

Tbili: 8.7

CBC unremarkable

lipase: normal

**PATIENT**

TT4, U/A, and Pt/PTT pending

Coco Hill

**CYTOLOGY SUBMISSION**

**SPECIES**

FNA of Liver

Feline

**OBSERVATIONS**

Liver: Submitted are 4 excellent videos of excellent collections of cells from the liver in Coco. Where hepatocytes are identified, there is marked vacuolization and prominent lipid in the cytoplasm of those cells. This is consistent throughout the videos. In the cells surrounding the hepatocytes there are large numbers of lymphoid cells, many of which are large and irregular. There are scattered neutrophils and some macrophages and a few fields, but the majority of the associated cells with the hepatocytes are large lymphoid cells.

**BREED**

Dlh

**SEX**

fs

**INTERPRETATION OF THE FINDINGS & FURTHER RECOMMENDATIONS**

**AGE**

Liver - Consistent with high-grade lymphoma with severe secondary hepatocellular lipidosis and feline fatty liver syndrome.

9y

**WEIGHT**

6.7 lbs

**COMMENTS**

The cellularity in the collection is mainly that of excellent collections of hepatocytes that are showing severe hepatocellular lipidosis. This supports feline fatty liver syndrome. However, this appears to be a secondary change to the infiltration of large numbers of lymphoid cells. Some fields are more representative than others. The lymphoid cells are large and atypical with irregular nucleoli. This supports a high-grade lymphoma in the liver. The liver and spleen could be involved, but the lymph node not be involved. An unfavorable prognosis is warranted in this case in my opinion. If chemotherapy is contemplated, then further evaluation of the lymphoid cells is in order. Very likely other organs are involved as well.

**HOSPITAL NAME**

West Salem Animal  
Clinic

**REFERRING VET**

Dr. Crane

**INVOICE NUMBER**

40674



**DATE**

2/28/23

**INTERPRETED BY**

L.D. McGill, DVM,  
Ph.D, DACVP

**PATIENT**

Coco Hill

**SPECIES**

Feline

**BREED**

Dlh

**SEX**

fs

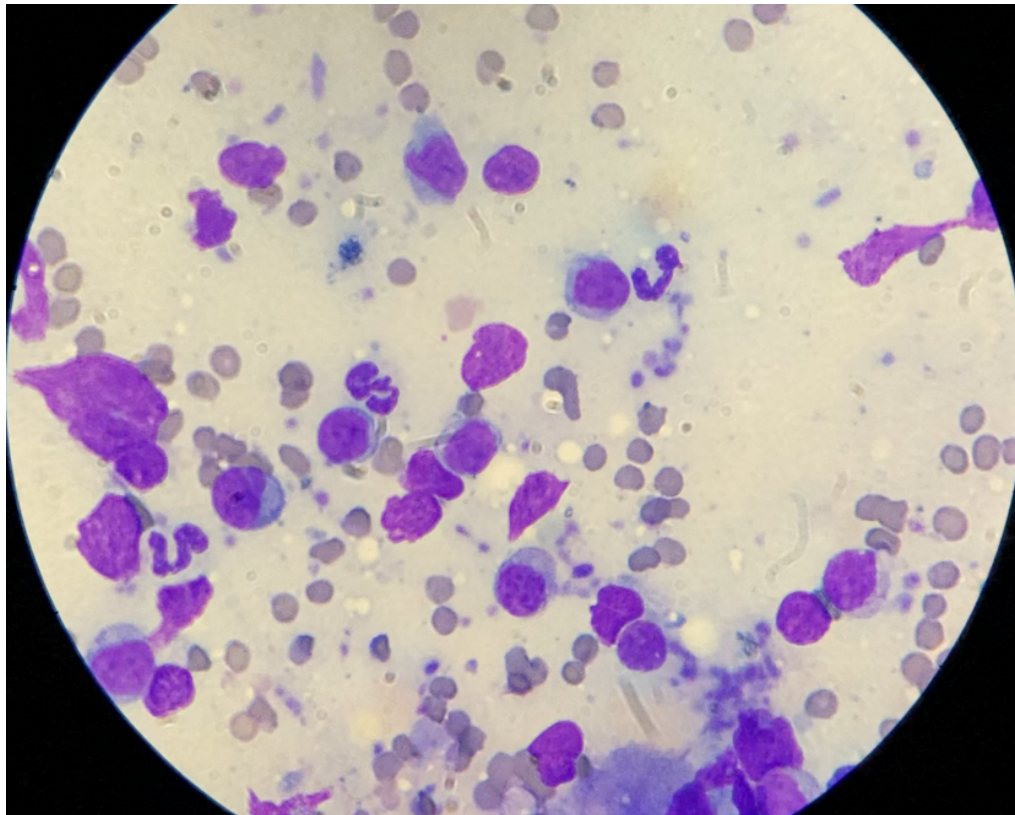


Image shows a group of cells with irregular lymphocytes and scattered neutrophils collected from the liver in Coco. Hepatocytes are not present in this field.

**AGE**

9y

The information and recommendations provided are based on the images presented by the referring veterinarian. No evaluation can be communicated regarding pathology that was not visible in the image/video clips provided.

**WEIGHT**

6.7 lbs

Thank you for this referral. If the clinical or image interpretation does not parallel your findings or if I can be of any further assistance, please contact me.

**HOSPITAL NAME**

West Salem Animal  
Clinic

L.D. McGill, DVM, Ph.D., DACVP  
8288 Top of the World Drive  
Cottonwood Heights, UT 84121  
ldmcgill.vetpath@gmail.com  
cell: 801-865-1220

**REFERRING VET**

Dr. Crane

**INVOICE NUMBER**

40674