



DATE **PRESENTING CLINICAL SIGNS**
12/7/21 History: FNA of spleen Post Ultrasound

INTERPRETED BY **CYTOLOGY SUBMISSION**
L.D. McGill, DVM, Ph.D, DACVP FNA of spleen Post Ultrasound.

PATIENT **OBSERVATIONS**
Lili Barkley Spleen: Submitted are 6 excellent videos of cells collected from the spleen in Lili. The cellularity is moderate to excellent throughout all of these videos. The nucleated cells are interspersed with red blood cells. There is a mixture of inflammatory cells throughout the reaction with many small mature lymphocytes. The majority of the cells that appear to be atypical are spindle cells that are definitely demonstrating anisocytosis and anisokaryosis. Some of these cells are polyhedral. Some of the spindle cells are associated with eosinophilic material. There are some aggregates of platelets interspersed in these smears.

SPECIES **INTERPRETATION OF THE FINDINGS & FURTHER RECOMMENDATIONS**
Canine Spleen - Spindle cell proliferation consistent with hemangiosarcoma or possible fibrosarcoma.

BREED **COMMENTS**
Jack Russell Terrier The cellularity in this excellent collection is not supporting lymphoma at all. That was my original suspicion but it is not present. There are adequate numbers of irregular spindle cells, many of which are packeted to suggest the possibility of a sarcoma. Hemangiosarcoma is a good possibility. If this is a hemangiosarcoma, then I'm very impressed with the cellular collection since they often do not release this many cells due to hemorrhagic cystic regions in the mass. Necrosis and inflammation occurs in those tumors and this is present in the smears. I think there is a very good possibility that this is a neoplastic process and thus splenectomy is encouraged.

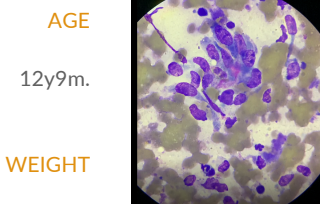


Image shows some of the irregular spindle cells with inflammation surrounding them in this collection from Lili. Note the anisocytosis and anisokaryosis in the spindle cells.

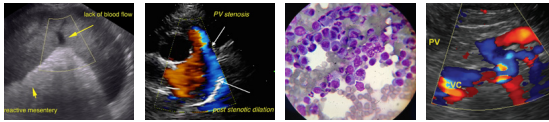
HOSPITAL NAME **The information and recommendations provided are based on the images presented by the referring veterinarian. No evaluation can be communicated regarding pathology that was not visible in the image/video clips provided.**
Pawsitive Wellness Veterinary Care

Thank you for this referral. If the clinical or image interpretation does not parallel your findings or if I can be of any further assistance please contact me.

REFERRING VET
Dr. Hardy
L.D. McGill, DVM, Ph.D., DACVP
8288 Top of the World Drive
Cottonwood Heights, UT 84121
ldmcgill.vetpath@gmail.com

INVOICE NUMBER
70429

cell: 801-865-1220



DATE

12/7/21

INTERPRETED BY

L.D. McGill, DVM,
Ph.D, DACVP

PATIENT

Lili Barkley

SPECIES

Canine

BREED

Jack Russell Terrier

SEX

fs

AGE

12y9m.

WEIGHT

18.8 lbs

HOSPITAL NAME

Pawsitive Wellness
Veterinary Care

REFERRING VET

Dr. Hardy

INVOICE NUMBER

70429