



DATE PRESENTING CLINICAL SIGNS

12/24/21

History: Screening spleen for mast cell Post mast cell removal

CYTOLOGY SUBMISSION

FNA of Spleen

INTERPRETED BY

L.D. McGill, DVM,
Ph.D, DACVP

OBSERVATIONS

Spleen: Submitted are 6 excellent videos of cells collected from the spleen in KitKat. The cellularity is mixed. There are scattered neutrophils interspersed with lymphoid cells and a very few nucleated RBCs. The lymphoid cells are reactive with many small mature lymphocytes. Atypical lymphoid cells are few. There are no suggestions of mast cells in any of the fields available to evaluate.

PATIENT

KitKat Kulink

INTERPRETATION OF THE FINDINGS & FURTHER RECOMMENDATIONS

Spleen - No suggestion of mast cell neoplasia with evidence of lymphoid hyperplasia.

SPECIES

Canine

COMMENTS

The cellularity supports some type of chronic inflammation with lymphoid tissue reaction. There is no evidence of malignancy and certainly no evidence of mast cell neoplasia. Lymphoid hyperplasia could be from any type of chronic inflammation in KitKat. Continued evaluation for any type of intra-abdominal inflammation or degeneration is encouraged but metastasis from mast cell disease is not present.

BREED

DSH

SEX

FS

AGE

13yr

WEIGHT

12.19 lbs

HOSPITAL NAME

Creswell Veterinary
Hospital

REFERRING VET

Dr. Furrer

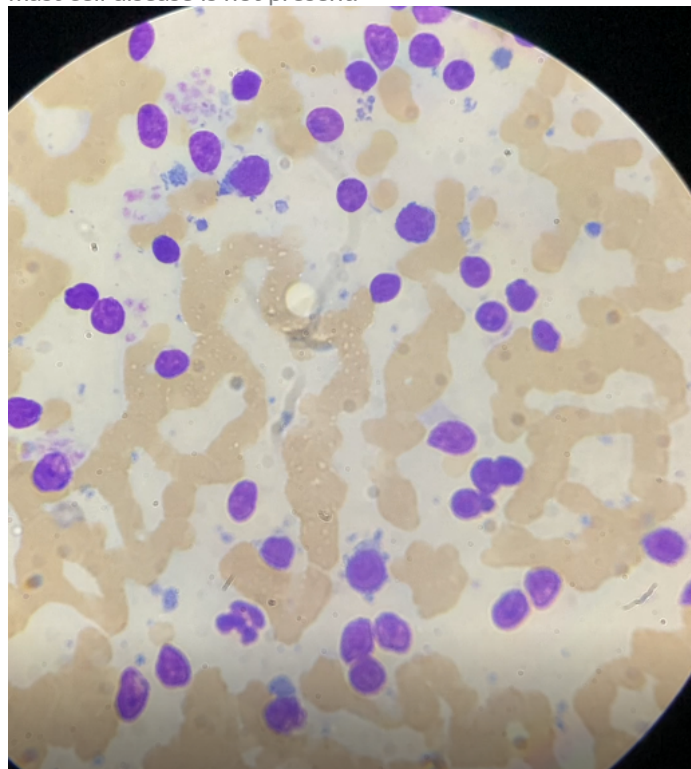


Image shows RBCs and platelets interspersed with small lymphocytes and scattered neutrophils. No mast cells are observed.

INVOICE NUMBER

70436



DATE

12/24/21

The information and recommendations provided are based on the images presented by the referring veterinarian. No evaluation can be communicated regarding pathology that was not visible in the image/video clips provided.

INTERPRETED BY

L.D. McGill, DVM,
Ph.D, DACVP

Thank you for this referral. If the clinical or image interpretation does not parallel your findings or if I can be of any further assistance please contact me.

PATIENT

KitKat Kulink

L.D. McGill, DVM, Ph.D., DACVP

8288 Top of the World Drive
Cottonwood Heights, UT 84121
ldmcgill.vetpath@gmail.com
cell: 801-865-1220

SPECIES

Canine

BREED

DSH

SEX

FS

AGE

13yr

WEIGHT

12.19 lbs

HOSPITAL NAME

Creswell Veterinary
Hospital

REFERRING VET

Dr. Furrer

INVOICE NUMBER

70436