



DATE PRESENTING CLINICAL SIGNS

12/24/21

History: FNA of Mesenteric lymph node mass

CYTOLOGY SUBMISSION

FNA of Mesenteric lymph node mass

INTERPRETED BY

L.D. McGill, DVM,
Ph.D, DACVP

OBSERVATIONS

Lymph node: Submitted are 8 excellent videos of cells collected from the lymph node in Earnst. The cellularity is mixed. This mixed cellularity includes macrophages interspersed with neutrophils, eosinophils and reactive lymphoid cells. Malignant characteristics are not identified. The lymphoid tissue is reactive with some small lymphocytes and a very few larger reactive lymphoid cells interspersed with intermediate lymphocytes. The major process is a chronic inflammatory response including eosinophils.

PATIENT

Earnst Porter

INTERPRETATION OF THE FINDINGS & FURTHER RECOMMENDATIONS

Lymph node - Chronic pyogranulomatous and eosinophilic lymphadenitis.

SPECIES

Feline

COMMENTS

The changes in this lymph node do not support neoplasia. This does not completely rule out the possibility of neoplasia in the intestine. The cellularity is most consistent with a chronic inflammatory process with a mixed cell reaction and eosinophils. This could be due to feline infectious peritonitis or could also be due to some type of chronic enteritis such as eosinophilic enteritis. If problems continue, a follow-up biopsy is suggested. PCR can be applied to these smears to determine whether feline coronavirus is involved in this disease process. A guarded to unfavorable prognosis is warranted. Additional tests for feline coronavirus would be encouraged.

BREED

DLH

SEX

MN

AGE

9y

WEIGHT

7.5 lbs

HOSPITAL NAME

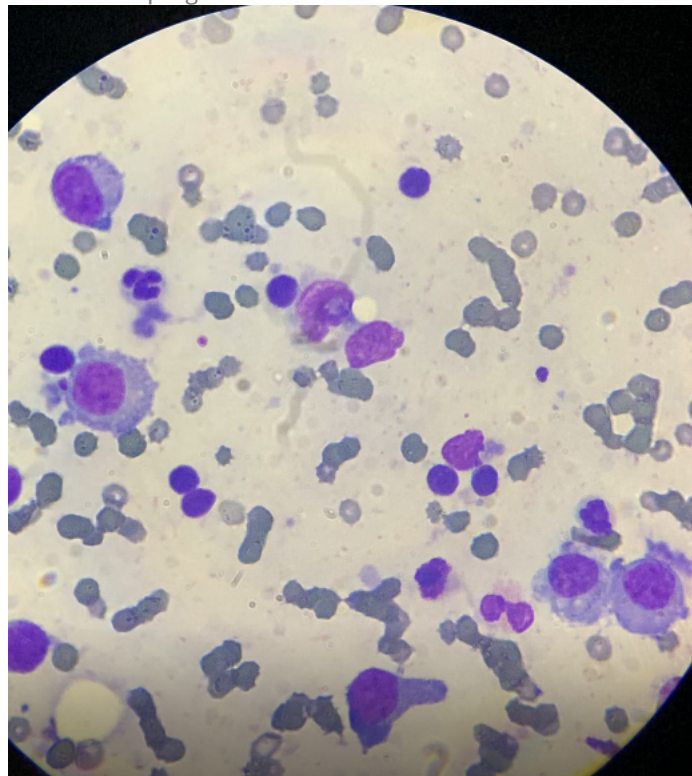
VCA Delta Oaks Animal
Hospital

REFERRING VET

Dr. Schulke and Dr
Lahm

INVOICE NUMBER

70435





DATE 12/24/21
Image shows macrophages interspersed with eosinophils, neutrophils and some mature small lymphocytes collected from Earnst.

INTERPRETED BY L.D. McGill, DVM, Ph.D., DACVP
The information and recommendations provided are based on the images presented by the referring veterinarian. No evaluation can be communicated regarding pathology that was not visible in the image/video clips provided.

Thank you for this referral. If the clinical or image interpretation does not parallel your findings or if I can be of any further assistance please contact me.

PATIENT Earnst Porter
L.D. McGill, DVM, Ph.D., DACVP
8288 Top of the World Drive
Cottonwood Heights, UT 84121
ldmcgill.vetpath@gmail.com
cell: 801-865-1220

SPECIES
Feline

BREED
DLH

SEX
MN

AGE
9y

WEIGHT
7.5 lbs

HOSPITAL NAME
VCA Delta Oaks Animal
Hospital

REFERRING VET
Dr. Schulke and Dr
Lahm

INVOICE NUMBER
70435