



**DATE PRESENTING CLINICAL SIGNS**

12/15/21

History: FNA of colonic mass

**CYTOLOGY SUBMISSION**

FNA of colonic mass

**INTERPRETED BY**

L.D. McGill, DVM,  
Ph.D, DACVP

**OBSERVATIONS**

Colonic mass: Submitted are 5 excellent videos of cells collected from the colonic mass in Lucy. The majority of the cells in the first three videos are neutrophils with necrotic debris and erythrocytes. The second two videos have erythrocytes with a mixture of inflammatory cells including neutrophils, lymphocytes and macrophages. Scattered throughout these videos are larger nuclei with minimal cytoplasm. I am unable to identify a source for those cells. Malignant criteria are not identified in these videos.

**PATIENT**

Lucy Hanes

**INTERPRETATION OF THE FINDINGS & FURTHER RECOMMENDATIONS**

Colonic mass - Pyogranulomatous inflammation with necrosis and scattered irregular large nuclei.

**SPECIES**

Canine

**COMMENTS**

The cellularity in this collection supports a rather severe chronic inflammatory process with associated necrosis. There are some large nuclei that appear to be naked nuclei and thus I am unable to identify their source. The most likely cause for the cellularity in this collection is one of a severe chronic inflammatory process in this region with bacterial infection and secondary necrosis. Another possibility is a carcinoma with extensive inflammation. I cannot confirm this diagnosis since we do not have good aggregates of cells. There are some aggregates of cells but they appear to be normal intestinal lumen cells. If problems continue, then a follow-up exploratory and biopsy of the area is encouraged. Antibiotic therapy to control bacterial infection is certainly in order. A guarded prognosis is warranted since we do not know the primary process in this region.

**BREED**

Dachshund x

**SEX**

Female intact

**AGE**

8y

**WEIGHT**

unknown

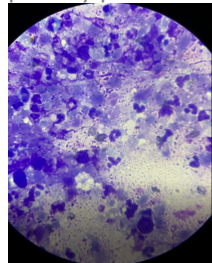


Image shows large numbers of neutrophils with necrotic debris and some bacteria. There are large nuclei in the image with minimal cytoplasm. Their source is a question.

**HOSPITAL NAME**

The Pet Clinic

The information and recommendations provided are based on the images presented by the referring veterinarian. No evaluation can be communicated regarding pathology that was not visible in the image/video clips provided.

**REFERRING VET**

Dr. Genova

Thank you for this referral. If the clinical or image interpretation does not parallel your findings or if I can be of any further assistance please contact me.

**L.D. McGill, DVM, Ph.D., DACVP**

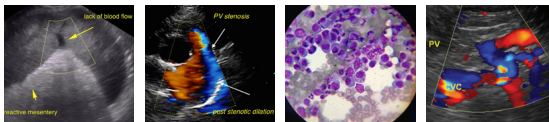
8288 Top of the World Drive  
Cottonwood Heights, UT 84121

ldmcgill.vetpath@gmail.com

cell: 801-865-1220

**INVOICE NUMBER**

70432



**DATE**

12/15/21

**INTERPRETED BY**

L.D. McGill, DVM,  
Ph.D, DACVP

**PATIENT**

Lucy Hanes

**SPECIES**

Canine

**BREED**

Dachshund x

**SEX**

Female intact

**AGE**

8y

**WEIGHT**

unkown

**HOSPITAL NAME**

The Pet Clinic

**REFERRING VET**

Dr. Genova

**INVOICE NUMBER**

70432