

DATE PRESENTING CLINICAL SIGNS
10/6/21 History: FNA of liver mass post U/S

INTERPRETED BY CYTOLOGY SUBMISSION
L.D. McGill, DVM, Ph.D, DACVP FNA of Liver

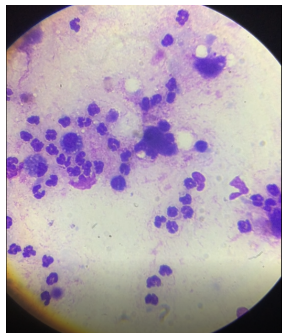
PATIENT OBSERVATIONS
Kenwood Miller Liver: Submitted are 6 excellent videos of cells collected from the liver in Kenwood. There are scattered hepatocytes throughout the collection but the majority of the cells are neutrophils interspersed with macrophages and rare lymphocytes. There are fields of material which include fluid may be mucus or protein and even some aggregates of cells that may be bile duct epithelial cells. The inflammatory process is more prominent in some videos than others. Malignant criteria are not identified.

SPECIES INTERPRETATION OF THE FINDINGS & FURTHER RECOMMENDATIONS
Canine Liver - Focal chronic suppurative hepatitis suggesting an abscess with changes suggestive of biliary cyst formation or adenoma.

BREED COMMENTS
Golden Retriever The changes in these excellent videos support inflammation and fluid buildup. The fluid appears to be mucoid fluid or protein. These could easily be from bile duct cystadenoma. They could also be the result of bile duct cysts. The inflammation which is suppurative could be secondary. I was unable to identify sepsis or neoplasia. Inflammation was present but it appears to be due to nonseptic inflammation such as tissue damage or possibly a low-grade bacterial infection. You know the location of this lesion. You can decide whether surgical intervention and removal is a viable option. Treatment for inflammation is encouraged. Draining the cystic material may be beneficial. A guarded prognosis is warranted since there are still things we do not know about the lesion in Kenwood.

AGE
13 yrs

WEIGHT
85 lbs

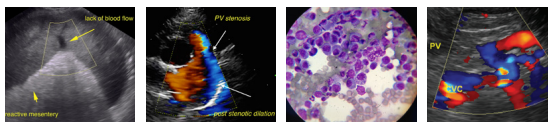


HOSPITAL NAME Image shows a collection of neutrophils with scattered macrophages and apparent individualized hepatocytes collected from Kenwood. The neutrophils appear non toxic.
South Willamette Veterinary Clinic

REFERRING VET The information and recommendations provided are based on the images presented by the referring veterinarian. No evaluation can be communicated regarding pathology that was not visible in the image/video clips provided.

Dr. Willaman Thank you for this referral. If the clinical or image interpretation does not parallel your findings or if I can be of any further assistance please contact me.

INVOICE NUMBER
70416



DATE

10/6/21 **L.D. McGill, DVM, Ph.D., DACVP**

8288 Top of the World Drive
Cottonwood Heights, UT 84121

INTERPRETED BY

ldmcgill.vetpath@gmail.com

L.D. McGill, DVM,
Ph.D., DACVP

cell: 801-865-1220

PATIENT

Kenwood Miller

SPECIES

Canine

BREED

Golden Retriever

SEX

Male Neutered

AGE

13 yrs

WEIGHT

85 lbs

HOSPITAL NAME

South Willamette
Veterinary Clinic

REFERRING VET

Dr. Willaman

INVOICE NUMBER

70416