

**DATE PRESENTING CLINICAL SIGNS**

10/28/22

History: Mild abdominal distention

Pt diagnosed with a liver mass previously with mild serosanguinous abdominal effusion at another clinic

**INTERPRETED BY**

L.D. McGill, DVM,  
Ph.D, DACVP

**CYTOLOGY SUBMISSION**

FNA of Liver

**PATIENT**

Quinn McQuiston

**OBSERVATIONS**

Liver: Submitted are 2 excellent videos of very minimal nucleated cellular collections from the liver in Quinn. There were less than 10 hepatocytes or large nucleated cells. The majority of the fields are red blood cells with scattered inflammatory cells. Specific cellularity is not identified.

**SPECIES**

Canine

**INTERPRETATION OF THE FINDINGS & FURTHER RECOMMENDATIONS**

Liver - Hemorrhagic collection with minimal numbers of cells.

**BREED**

Spitz

**COMMENTS**

The cellularity in this collection is so minimal that interpretation is very difficult. The hemorrhage could be the result of a hemangiosarcoma, but I did not identify any of those types of cells. A hematoma could also be part of the process. The nucleated cells are so few that I can add no further information with respect to interpretation. A re-aspiration or collection of more cells prior to resubmission may be beneficial. Otherwise, surgical excision and biopsy is suggested. A guarded prognosis is warranted since we still do not know what the mass may be.

**SEX**

FS

**AGE**

11y

**WEIGHT**

34.2 lbs

**HOSPITAL NAME**

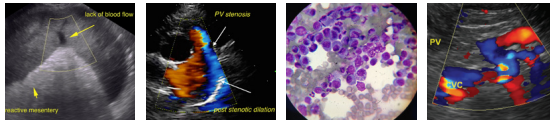
Santa Clara AH

**REFERRING VET**

Dr. Zalauf

**INVOICE NUMBER**

40634



**DATE**

10/28/22

**INTERPRETED BY**

L.D. McGill, DVM,  
Ph.D, DACVP

**PATIENT**

Quinn McQuiston

**SPECIES**

Canine

**BREED**

Spitz

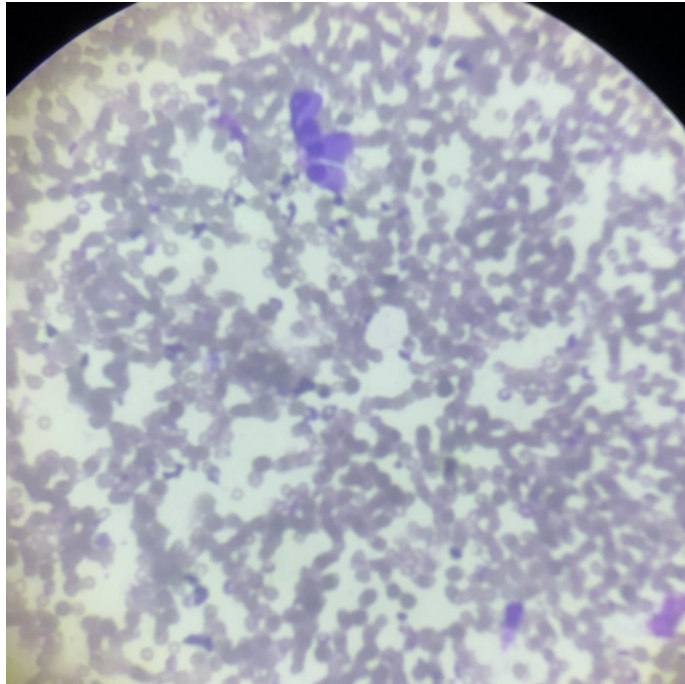


Image shows a clump of cells associated with the large numbers of RBCs collected from Quinn. These cells may be helpful, but they are not identifiable due to the paucity.

**SEX**

FS

The information and recommendations provided are based on the images presented by the referring veterinarian. No evaluation can be communicated regarding pathology that was not visible in the image/video clips provided.

**AGE**

11y

Thank you for this referral. If the clinical or image interpretation does not parallel your findings or if I can be of any further assistance, please contact me.

**WEIGHT**

34.2 lbs

**L.D. McGill, DVM, Ph.D., DACVP**  
8288 Top of the World Drive  
Cottonwood Heights, UT 84121  
ldmcgill.vetpath@gmail.com  
cell: 801-865-1220

**HOSPITAL NAME**

Santa Clara AH

**REFERRING VET**

Dr. Zalauf

**INVOICE NUMBER**

40634