



PATIENT

Colby Stickle

SPECIES

Canine

BREED

Golden Retriever

SEX

Male, neutered

AGE

5.5 Yrs.

WEIGHT

80.2 lbs.

INTERPRETED BY

Andrea Nicastro, DVM,
Diplomate ACVIM
(*Small Animal Internal
Medicine*)

IMAGING PERFORMED BY

Dr. Ken Leal

HOSPITAL NAME

Black River Vet

REFERRING VET

Dr. Hewitt

INVOICE

13365

DATE

12/30/25

PRESENTING CLINICAL SIGNS

History : Colby has been experiencing intermittent episodes of vomiting and diarrhea for several months. The vomiting and diarrhea do not always occur together - he may have diarrhea without vomiting or vice versa. Episodes resolve with chicken and rice diet plus metronidazole treatment, but recur when returned to regular dog food. Recently developed food aversion and refuses to eat regular dog food. Has tried multiple food types including lamb and rice, and sensitive skin/stomach formula, but patient refuses most. Will readily eat chicken, bones, cheese, and human food items like blueberries, banana, and small amounts of table food. Most recent episode occurred after eating wet food mixed with lamb and rice - vomited around 4 AM with projectile vomiting. Patient shows abdominal distension during episodes. Between episodes, patient appears normal with good appetite and energy. Current Medications: prednisone, metronidazole, tums, B12. Thrombocytosis, panhypoproteinemia.

ULTRASONOGRAPHIC EXAMINATION OF THE ABDOMEN

Urinary System

The urinary bladder wall is normal in thickness and the mucosal surface is smooth. The bladder is moderately distended. Luminal contents are anechoic. No cystic calculi are observed. The region of the trigone and the proximal urethra, visible to a depth of 4 cm, are normal.

The prostate is normal in size (1.23 cm in width) and shape. Parenchyma is homogenous. The prostatic urethra appears normal without evidence of dilation or obstruction.

The left kidney is normal in size (6.23 cm in length) with a normal shape, architecture and smooth peripheral margins. There is a normal 1:3 cortex to medulla ratio with minimal loss of corticomedullary distinction. There is no evidence of pyelectasia, nephroliths, infarcts or hydroureter. Renal vasculature is normal.

The right kidney is normal in size (6.69 cm in length) with a normal shape, architecture and smooth peripheral margins. There is a normal 1:3 cortex to medulla ratio with minimal loss of corticomedullary distinction. There is no evidence of pyelectasia, nephroliths, infarcts or hydroureter. Renal vasculature is normal.

Adrenal Glands

The left adrenal gland is normal in size (0.44 cm at cranial pole) (0.62 cm at caudal pole) with a normal shape and homogenous parenchyma. The glandular echogenicity and detail are unremarkable. Capsule, cortex, and medullary definition are normal. The phrenicoabdominal vein and surrounding vasculature are normal.

The right adrenal gland is normal in size (1.32 cm at cranial pole) (0.63 cm at caudal pole) with a normal shape and homogenous parenchyma. The glandular echogenicity and detail are unremarkable. Capsule, cortex, and medullary definition are normal. The phrenicoabdominal vein and surrounding vasculature are normal.

Spleen

The spleen is normal in size (1.90 cm in width at the level of the hilus) with a normal capsular contour. There is appropriate echogenicity and echotexture. No focal lesions are observed. Splenic vasculature is normal.

Liver

The liver is normal to prominent in size with smooth peripheral contours. There is appropriate echogenicity and echotexture. No overt structural evidence of inflammatory, infiltrative, or



PATIENT

Colby Stickle

SPECIES

Canine

BREED

Golden Retriever

SEX

Male, neutered

AGE

5.5 Yrs.

WEIGHT

80.2 lbs.

INTERPRETED BY

Andrea Nicastro, DVM,
Diplomate ACVIM
(*Small Animal Internal
Medicine*)

IMAGING PERFORMED BY

Dr. Ken Leal

HOSPITAL NAME

Black River Vet

REFERRING VET

Dr. Hewitt

INVOICE

13365

DATE

12/30/25

regenerative pathology is evident. Vascular and biliary tracts are of normal volume with no evidence of congestion.

The gall bladder lumen is moderately distended. The wall is thin and smooth. A small to moderate amount of gravity-dependent echogenic debris/sludge is observed within the lumen. The cystic and common bile ducts are normal/not seen.

Gastrointestinal

The gastric lumen is mildly distended with ingesta and irregular shadowing material. The gastric wall is normal in thickness with a normal layering pattern. The small intestinal lumen is segmentally dilated with chyme. The small intestinal wall is normal in thickness with a normal layering pattern and appropriate mural detail. Discreet masses are not identified. The colonic wall is normal.

Pancreas

The region of the pancreas is isoechoic relative to surrounding omental fat. No obvious parenchymal abnormalities are observed. There is no evidence of regional inflammation or effusion.

Lymph nodes

A 1.95 x 0.88 cm mesenteric lymph node is visualized.

Free Abdomen

An area of hyperechoic mesentery is observed in the mid-abdominal region. There is no obvious evidence of free fluid.

ULTRASONOGRAPHIC FINDINGS

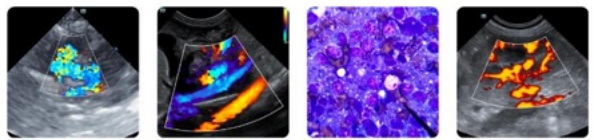
Primary Findings:

- The gastric shadowing material may represent normal ingesta and/or foreign material. It appears non-obstructive at the time of this study.
- The prominent mesenteric lymph node is likely reactive with a lower possibility of emerging neoplasia.
- The hyperechoic mesentery in the mid-abdominal region likely represents focal peritonitis, likely sterile. The origin of the peritonitis is unclear but may be secondary to bowel inflammation, other.

Secondary Findings:

- Equivocal hepatomegaly
- Gallbladder debris/sludge, non-mucocele

*An obvious cause for the patient's clinical signs and panhypoproteinemia is not definitively identified in this study. However, a protein-losing enteropathy is of concern. Top differentials include inflammatory bowel disease, lymphangiectasia, infectious/parasitic disease, occult neoplasia, other. Hypoadrenocorticism can also mimic protein-losing enteropathies. Other causes of hypoalbuminemia (i.e., hepatic insufficiency, renal loss) should also be considered



PATIENT

Colby Stickle

SPECIES

Canine

BREED

Golden Retriever

SEX

Male, neutered

AGE

5.5 Yrs.

WEIGHT

80.2 lbs.

INTERPRETED BY

Andrea Nicastro, DVM,
Diplomate ACVIM
(Small Animal Internal
Medicine)

IMAGING PERFORMED BY

Dr. Ken Leal

HOSPITAL NAME

Black River Vet

REFERRING VET

Dr. Hewitt

INVOICE

13365

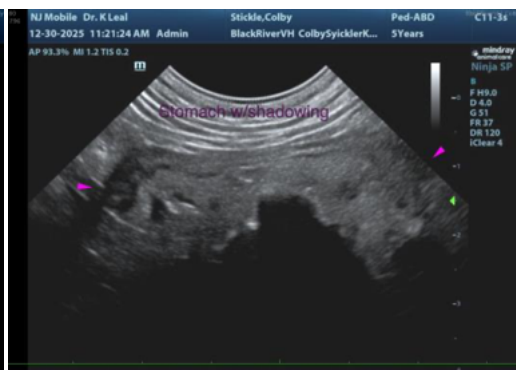
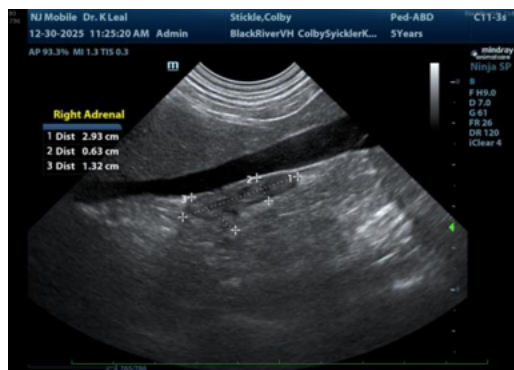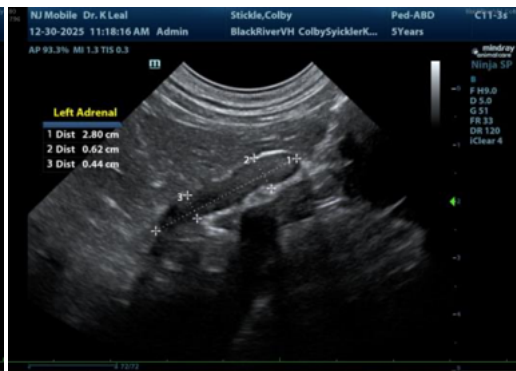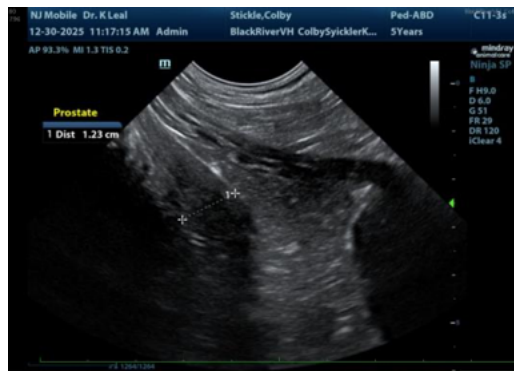DATE

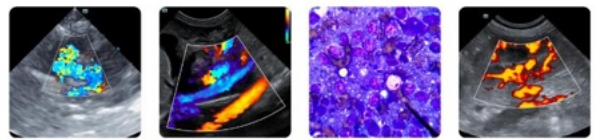
12/30/25

INTERPRETATION OF THE FINDINGS & FURTHER RECOMMENDATIONS

The following diagnostics/treatment recommendations can be considered:

1. Texas GI panel including serum cobalamin, folate, PLI, TLI and resting cortisol level
2. Fecal evaluation for ova/Giardia
3. Prophylactic deworming with Fenbendazole.
4. 3-4 week hypoallergenic or hydrolyzed protein diet trial
5. Initiation of a probiotic with a high colony count +/- fiber supplement (i.e., psyllium).
6. Depending on the results of the above diagnostics/therapeutics, endoscopic or surgical gastrointestinal biopsies may be warranted. Three-view thoracic radiographs should be performed prior to any anesthetic event.
7. To further evaluate for non-GI causes of hypoalbuminemia, consider pre and post-prandial serum bile acids and a UPC (to assess for significant proteinuria), particularly if protein is present on the urine dipstick.





PATIENT

Colby Stickle

SPECIES

Canine

BREED

Golden Retriever

SEX

Male, neutered

AGE

5.5 Yrs.

WEIGHT

80.2 lbs.

INTERPRETED BY

Andrea Nicastro, DVM,
Diplomate ACVIM
(*Small Animal Internal
Medicine*)

IMAGING PERFORMED BY

Dr. Ken Leal

HOSPITAL NAME

Black River Vet

REFERRING VET

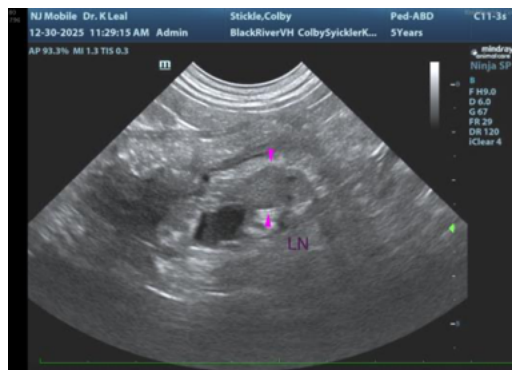
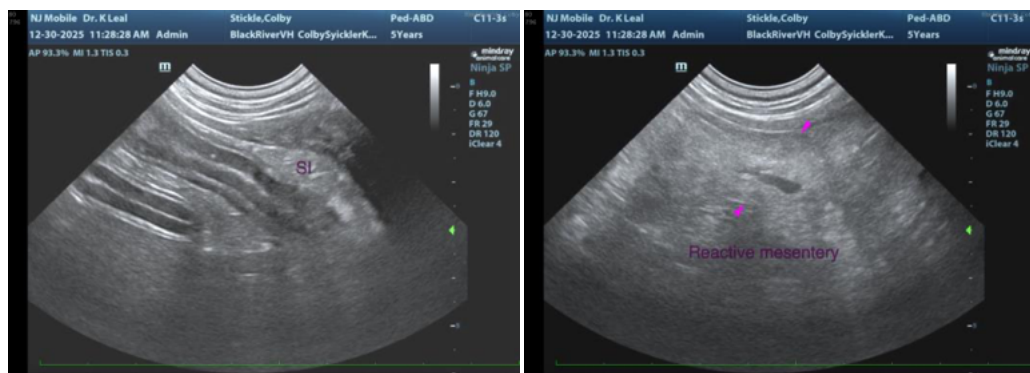
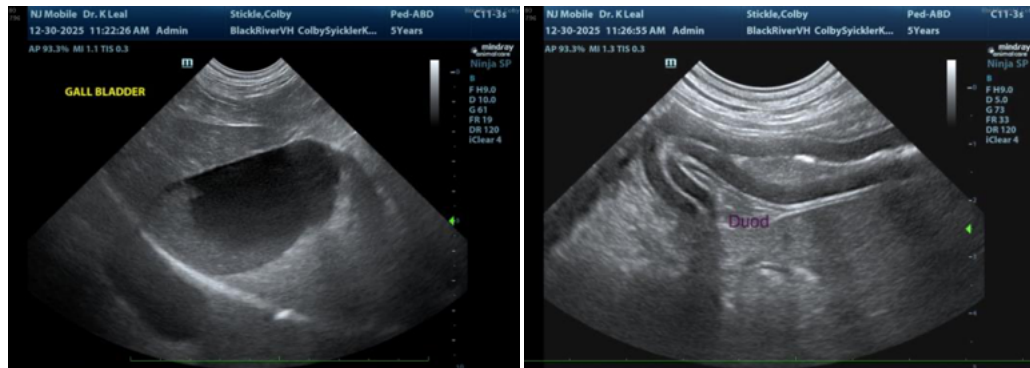
Dr. Hewitt

INVOICE

13365

DATE

12/30/25



The information and recommendations provided are based on the images presented by the referring veterinarian/sonographer. No evaluation can be communicated regarding pathology that was not visible in the image/video clips provided.

Thank you for this referral. If the clinical or image interpretation does not parallel your findings or if I can be of any further assistance please contact me.

Andrea Nicastro, MPH, DVM, Diplomate DACVIM (Small Animal Internal Medicine)
info@SonoPath.com