



PATIENT PRESENTING CLINICAL SIGNS

Duncan Hill
History: waxing and waning lethargy; organomegaly; suspicious mass effect on rads
Abnormal PE/Chem/CBC/UA Results: ALKP 211, trig 351

SPECIES ULTRASONOGRAPHIC EXAMINATION OF THE ABDOMEN

Canine

Urinary System

BREED

Beagle mix

The urinary bladder is moderately distended. The wall is normal in thickness with a smooth mucosal surface. A scant amount of echogenic to mineralized suspended debris is observed within the lumen. No distinct calculi are observed. The region of the trigone and the proximal urethra, visible to a depth of 2 cm, are normal.

SEX

Male, neutered

The prostate is normal in size (0.76 cm in width) and shape. Parenchyma is homogenous. The prostatic urethra appears normal without evidence of dilation or obstruction.

AGE

12 Yrs.

The left kidney is normal in size (6.23 cm in length) with a normal shape, smooth peripheral margins and normal internal architecture. There is minimal loss of corticomedullary distinction. Several hyperechoic shadowing diverticular foci are observed. There is no evidence of pyelectasia, infarcts or hydronephrosis. Renal vasculature is normal.

WEIGHT

38 lbs.

The right kidney is normal in size (7.27 cm in length) with a normal shape, smooth peripheral margins and normal internal architecture. There is minimal loss of corticomedullary distinction. Several hyperechoic shadowing diverticular foci are observed. There is no evidence of pyelectasia, infarcts or hydronephrosis. Renal vasculature is normal.

INTERPRETED BY

Andrea Nicastro, DVM,
Diplomate ACVIM
(*Small Animal Internal
Medicine*)

Adrenal Glands

The left adrenal gland is normal size (0.47 cm at cranial pole) (0.56 cm at caudal pole) (2.25 cm in length); normal shape; homogenous parenchyma. The glandular echogenicity and detail are unremarkable. Capsule, cortex, and medullary definition are normal. The phrenicoabdominal vein and surrounding vasculature are normal.

The right adrenal gland is normal size (1.46 cm at cranial pole) (0.63 cm at caudal pole) (2.74 cm in length); normal shape; homogenous parenchyma. The glandular echogenicity and detail are unremarkable. Capsule, cortex, and medullary definition are normal. The phrenicoabdominal vein and surrounding vasculature are normal.

IMAGING PERFORMED BY

Diane McFadden,
RVT

Spleen

HOSPITAL NAME

Wantage VH

The spleen is normal to prominent in size (2.23 cm in width at the level of the hilus) with normal curvilinear peripheral contours. There is appropriate echogenicity and echotexture. No focal lesions are observed. Splenic vasculature is normal.

REFERRING VET

Dr. Bullock

Liver

The liver is prominent to enlarged with slight rounding of the peripheral contours. There is appropriate echogenicity and echotexture. No overt structural evidence of inflammatory, infiltrative or regenerative pathology is evident. Vascular and biliary tracts are of normal volume with no evidence of congestion. No pathological hepatic lymphadenopathy observed. The gall bladder lumen is moderately distended. The wall is thin and smooth. A moderate amount of aggregated, echogenic suspended sludge is observed within the lumen. The cystic and common bile ducts are normal/not seen.

INVOICE

13954

DATE

9/13/22



PATIENT

Gastrointestinal

Duncan Hill

The gastric lumen is mildly to moderately distended with ingesta. The gastric wall and pylorus are normal in thickness with a normal layering pattern. The pyloric outflow tract is patent. The small intestinal lumen is segmentally dilated with chyme. The small intestinal wall thickness is normal with a normal layering pattern and appropriate mural detail. Discreet masses are not identified. The colonic wall is normal. No obstructive disease is noted.

SPECIES

Canine

Pancreas

BREED

Beagle mix

A portion of the pancreas is obscured by the gastric distention. In the visualized portions, no obvious pathology is seen.

SEX

Male, neutered

Free Abdomen

The peritoneal cavity is normal. There is no evidence of inflammation or effusion. The abdominal lymph nodes are normal/not visible.

AGE

12 Yrs.

ULTRASONOGRAPHIC FINDINGS

WEIGHT

38 lbs.

Primary Findings:

- The diffuse hepatic changes are non-specific and could be consistent with vacuolar hepatopathy, regenerative nodular hyperplasia, and/or age-related remodeling. Inflammatory and infiltrative disease are considered less likely.
- The gallbladder sludge pattern is concerning for a developing mucocele. However, cholestasis cannot be completely excluded. It is unclear whether the gall bladder changes are causing the patient's lethargy or if a concurrent disease process is responsible.
- The mild splenomegaly is most consistent with a benign process (i.e., lymphoid hyperplasia, extramedullary hematopoiesis, splenitis, antigenic stimulation or similar). Alternatively, it may be a normal variant for this patient. Emerging neoplasia is possible but considered less likely.

INTERPRETED BY

Andrea Nicastro, DVM,
Diplomate ACVIM
(*Small Animal Internal
Medicine*)

Secondary Findings:

- Minor age-related renal changes with subtle dystrophic mineralization.

**IMAGING
PERFORMED BY**

Diane McFadden,
RVT

INTERPRETATION OF THE FINDINGS & FURTHER RECOMMENDATIONS

HOSPITAL NAME

Wantage VH

- Given the gall bladder changes, Ursodeoxycholic acid (Ursodiol) at 10-15 mg/kg once a day is recommended. Serial sonographic monitoring (e.g., every 6-8 weeks) of the gall bladder is recommended to assess for progression to a fully formed mucocele.

REFERRING VET

Dr. Bullock

- Regarding the hepatic and splenic changes, fine needle aspirates can be considered (if clotting status is appropriate. 25-gauge needles should be used.
- Given the vague clinical signs, also consider a T4/free T4 by equilibrium dialysis +/- testing for tick borne disease (if clinical suspicion is high).

INVOICE

13954

- Consider testing for hyperadrenocorticism with a low-dose dexamethasone suppression test or ACTH stimulation test if clinical signs (i.e., PU/PD) develop.

DATE

9/13/22



PATIENT

Duncan Hill

SPECIES

Canine

BREED

Beagle mix

SEX

Male, neutered

AGE

12 Yrs.

WEIGHT

38 lbs.

INTERPRETED BY

Andrea Nicastro, DVM,
Diplomate ACVIM
(Small Animal Internal
Medicine)

**IMAGING
PERFORMED BY**

Diane McFadden,
RVT

HOSPITAL NAME

Wantage VH

REFERRING VET

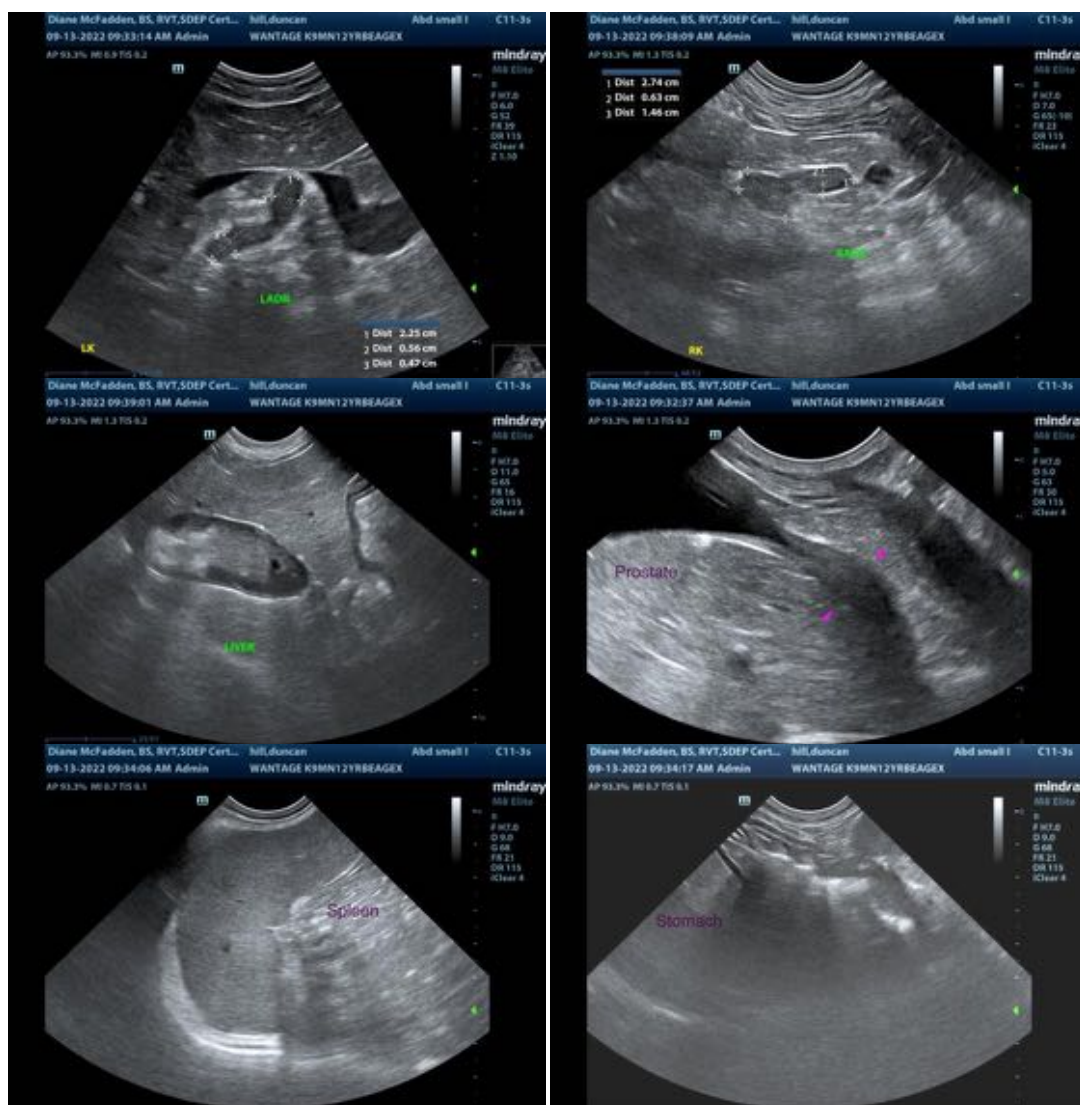
Dr. Bullock

INVOICE

13954

DATE

9/13/22



The information and recommendations provided are based on the images presented by the referring veterinarian/sonographer. No evaluation can be communicated regarding pathology that was not visible in the image/video clips provided.

Thank you for this referral. If the clinical or image interpretation does not parallel your findings or if I can be of any further assistance please contact me.

Andrea Nicastro, MPH, DVM, Diplomate DACVIM (Small Animal Internal Medicine)
info@SonoPath.com