



PATIENT

Brutus Gerbino

SPECIES

Canine

BREED

Boxer

SEX

Male, neutered

AGE

8 Yrs.

WEIGHT

68.4 lbs.

INTERPRETED BY

Andrea Nicastro, DVM,
Diplomate ACVIM
(Small Animal Internal
Medicine)

IMAGING PERFORMED BY

Kelly Vazquez, CVT

HOSPITAL NAME

Ramapo Valley AH

REFERRING VET

Dr. Katara

INVOICE

13831

DATE

8/16/21

PRESENTING CLINICAL SIGNS

History: ADR, recent episode of GI issues, owner wants to make sure not missing anything/concern for neoplasia due to breed and age.

Abnormal PE/Chem/CBC/UA Results: CBC/Chem: WNL as of 8/15/2022.

ULTRASONOGRAPHIC EXAMINATION OF THE ABDOMEN

Urinary System

The urinary bladder wall is normal in thickness and the mucosal surface is smooth. The bladder lumen is mildly distended with anechoic urine. No masses, inflammatory changes or calculi are observed. Ureteral papillae and visualized portion of the proximal urethra, visible to a depth of 2 cm, are normal.

The prostate is normal in size (0.89 cm in width) and shape. Parenchyma is homogenous. The prostatic urethra appears normal without evidence of dilation or obstruction.

The left kidney is normal size (6.74 cm in length); normal shape and architecture with smooth peripheral margins. There is a normal 1:3 cortex to medulla ratio with minimal loss of corticomedullary distinction. There is no evidence of pyelectasia, nephroliths, infarcts or hydronephrosis. Renal vasculature is normal.

The right kidney is normal size (6.62 cm in length); normal shape and architecture with smooth peripheral margins. There is a normal 1:3 cortex to medulla ratio with minimal loss of corticomedullary distinction. There is no evidence of pyelectasia, nephroliths, infarcts or hydronephrosis. Renal vasculature is normal.

Adrenal Glands

The left adrenal gland is normal size (0.56 cm at cranial pole) (0.68 cm at caudal pole) (2.03 cm in length); normal shape; homogenous parenchyma. The glandular echogenicity and detail are unremarkable. Capsule, cortex, and medullary definition are normal. The phrenicoabdominal vein and surrounding vasculature are normal.

The right adrenal gland is normal size (0.78 cm at cranial pole) (0.75 cm at caudal pole) (2.26 cm in length); normal shape; homogenous parenchyma. The glandular echogenicity and detail are unremarkable. Capsule, cortex, and medullary definition are normal. The phrenicoabdominal vein and surrounding vasculature are normal.

Spleen

The spleen is normal in size (2.03 cm in width at the level of the hilus) with a normal capsular contour. The parenchyma is slightly mottled in appearance. No focal lesions are observed. Splenic vasculature is normal.

Liver

The liver is subjectively normal in size with normal contours and structure. There is appropriate echogenicity and echotexture. No overt structural evidence of inflammatory, infiltrative or regenerative pathology is evident. Vascular and biliary tracts are of normal volume with no evidence of congestion. No pathological hepatic lymphadenopathy observed. The gall bladder is not definitively visualized in the available images.

Gastrointestinal



PATIENT

Brutus Gerbino

The gastric lumen is mildly distended with ingesta. The gastric wall is normal in thickness with a normal layering pattern. The small intestinal lumen is segmentally gas distended. The small intestinal wall thickness is normal with a normal layering pattern and appropriate mural detail. Discreet masses are not identified. The colonic wall is normal. No obstructive disease is noted.

SPECIES

Canine

Pancreas

The region of the pancreas is isoechoic relative to surrounding omental fat. No obvious parenchymal abnormalities are observed. There is no evidence of regional inflammation or effusion.

BREED

Boxer

Free Abdomen

The peritoneal cavity is normal. There is no evidence of inflammation or effusion. The abdominal lymph nodes are normal/not visible.

SEX

Male, neutered

AGE

8 Yrs.

- The splenic parenchymal changes are most consistent with a benign process such as lymphoid hyperplasia, extramedullary hematopoiesis, splenitis or antigenic stimulation with a low possibility of infiltrative neoplasia (i.e., lymphoma, mast cell neoplasia).

WEIGHT

68.4 lbs.

*An obvious cause for the patient's GI signs is not definitively identified in this study. Considerations include microscopic gastrointestinal disease (i.e., food allergy/intolerance, inflammatory bowel disease, infectious/parasitic), underlying metabolic issue, low-grade pancreatitis, occult neoplasia, other.

INTERPRETED BY

Andrea Nicastro, DVM,
Diplomate ACVIM
(*Small Animal Internal
Medicine*)

INTERPRETATION OF THE FINDINGS & FURTHER RECOMMENDATIONS

- A fine needle aspirate of the spleen can be considered (if clotting status is appropriate) to further evaluate for round cell neoplasia.
- Other diagnostic considerations include the following:
 - A fecal evaluation for ova/Giardia
 - Malabsorption panel including serum cobalamin, folate, TLI and PLI.
 - A resting cortisol level to screen for hypoadrenocorticism. If resting cortisol level is < 2.0 mcg/dL, an ACTH stimulation test is recommended
 - A limited antigen diet +/- endoscopic or surgical GI biopsies may be warranted. If biopsies are pursued, three-view thoracic radiographs should be performed prior to anesthesia to assess cardiopulmonary status.

IMAGING PERFORMED BY

Kelly Vazquez, CVT

HOSPITAL NAME

Ramapo Valley AH

REFERRING VET

Dr. Katara

INVOICE

13831

DATE

8/16/21



PATIENT

Brutus Gerbino

SPECIES

Canine

BREED

Boxer

SEX

Male, neutered

AGE

8 Yrs.

WEIGHT

68.4 lbs.

INTERPRETED BY

Andrea Nicastro, DVM,
Diplomate ACVIM
(Small Animal Internal
Medicine)

**IMAGING
PERFORMED BY**

Kelly Vazquez, CVT

HOSPITAL NAME

Ramapo Valley AH

REFERRING VET

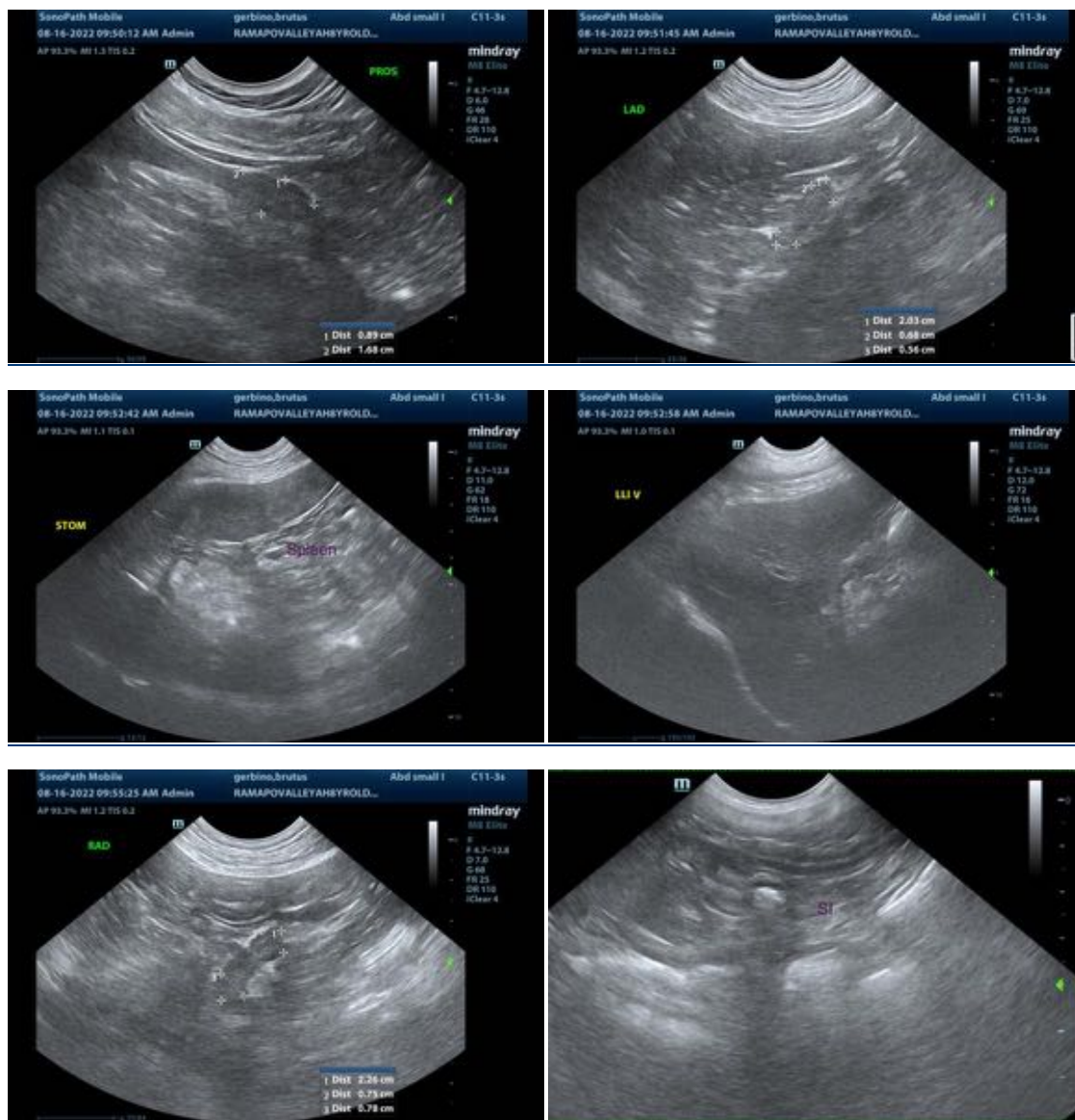
Dr. Katara

INVOICE

13831

DATE

8/16/21



The information and recommendations provided are based on the images presented by the referring veterinarian/sonographer. No evaluation can be communicated regarding pathology that was not visible in the image/video clips provided.

Thank you for this referral. If the clinical or image interpretation does not parallel your findings or if I can be of any further assistance please contact me.

Andrea Nicastro, MPH, DVM, Diplomate DACVIM (Small Animal Internal Medicine)
info@SonoPath.com