



**PATIENT**

Brutus Zierenberg

**SPECIES**

Canine

**BREED**

Australian Cattle dog  
mix

**SEX**

Male, neutered

**AGE**

8 Yrs.

**WEIGHT**

42.13 lbs.

**INTERPRETED BY**

Andrea Nicastro, DVM,  
Diplomate ACVIM  
(*Small Animal Internal  
Medicine*)

**IMAGING  
PERFORMED BY**

Jessica Miller

**HOSPITAL NAME**

Companion AH  
Parsippany

**REFERRING VET**

Dr. Wolf

**INVOICE**

13722

**DATE**

7/12/22

**PRESENTING CLINICAL SIGNS**

History: Check prostate and bladder. Hematuria.

Abnormal PE/Chem/CBC/UA Results: UA: pH 6.5, Blood+++ , Protein trace, RBCs 20-40/HPF, WBCs 5-10/HPF, Bacteria TNTC SG: 1.049

**ULTRASONOGRAPHIC EXAMINATION OF THE ABDOMEN**

*Urinary System*

The urinary bladder wall is moderately distended. The wall is normal in thickness with a smooth mucosal surface. A small to moderate amount of stranding echogenic suspended debris is observed within the lumen. No cystic calculi are observed. The region of the trigone is normal. The pre and post prostatic urethra appear subjectively mildly thickened.

The prostate is enlarged and irregular with a mass effect. The parenchyma is heterogeneous with ill-defined fluid pockets containing echogenic debris. The prostatic urethra is not overtly dilated.

The left kidney is normal size (6.99 cm in length); normal shape and architecture with smooth peripheral margins. There is a normal 1:3 cortex to medulla ratio with minimal to mild loss of corticomedullary distinction. There is no evidence of pyelectasia, nephroliths, infarcts or hydronephrosis. Renal vasculature is normal.

The right kidney is normal size (6.77 cm in length); normal shape and architecture with smooth peripheral margins. There is a normal 1:3 cortex to medulla ratio with minimal to mild loss of corticomedullary distinction. There is no evidence of pyelectasia, nephroliths, infarcts or hydronephrosis. Renal vasculature is normal.

*Adrenal Glands*

The left adrenal gland is normal size (0.42 cm at cranial pole) (0.65 cm at caudal pole) (2.55 cm in length); normal shape; homogenous parenchyma. The glandular echogenicity and detail are unremarkable. Capsule, cortex, and medullary definition are normal. The phrenicoabdominal vein and surrounding vasculature are normal.

The right adrenal gland is normal size (1.06 cm at cranial pole) (0.55 cm at caudal pole) (2.78 cm in length); normal shape; homogenous parenchyma. The glandular echogenicity and detail are unremarkable. Capsule, cortex, and medullary definition are normal. The phrenicoabdominal vein and surrounding vasculature are normal.

*Spleen*

The spleen is normal in size (1.90 cm in width at the level of the hilus) with a normal capsular contour. A light micronodular pattern is observed throughout the organ. No focal lesions are observed. Splenic vasculature is normal.

*Liver*

The liver is subjectively normal in size with normal curvilinear peripheral contours. The parenchyma is slightly mottled in appearance. No distinct focal lesions are observed. Vascular and biliary tracts are of normal volume with no evidence of congestion. The portal vein: caudal vena cava ratio is approximately 1:1. The gall bladder lumen is moderately distended. The wall is thin and smooth. Luminal contents are anechoic. The cystic and common bile ducts are normal/not seen.



**PATIENT**

***Gastrointestinal***

Brutus Zierenberg

The stomach and intestine are free of stasis and exhibit normal peristaltic activity. The gastric lumen is not distended. The gastric wall and pylorus are normal in thickness with a normal layering pattern. The pyloric outflow tract is patent. The small intestinal lumen is not dilated. The small intestinal wall thickness is normal with a normal layering pattern and appropriate mural detail. Discreet masses are not identified. The ileoceccocolic junction and colonic wall are normal. No obstructive disease is noted.

**SPECIES**

Canine

***Pancreas***

The right limb of the pancreas is visible with normal curvilinear peripheral contours. The parenchyma is largely isoechoic relative to surrounding omental fat and slightly mottled in appearance. The pancreatic duct is visible but not overtly dilated. There is no evidence of peripancreatic inflammation or effusion.

**BREED**

Australian Cattle dog mix

**SEX**

Male, neutered

***Free Abdomen***

Trace free fluid is observed. A 1.84 cm medial iliac lymph node is visualized.

**AGE**

8 Yrs.

**ULTRASONOGRAPHIC FINDINGS**

**Primary Findings:**

- Prostatic mass effect. Neoplasia (i.e., adenocarcinoma, transitional cell carcinoma) is considered likely with a lower possibility of benign pathology. There is questionable extension into the pre- and post-prostatic urethra. Necrotic or abscessed areas within the prostatic parenchyma are suspected.
- The prominent medial iliac lymph node may represent reactive lymphadenitis, lymphoid hyperplasia or potentially, early metastatic disease.
- The trace ascites may be secondary to prostatic pathology, low oncotic pressure, increased hydrostatic pressure or increased vascular permeability.

**Secondary Findings:**

- The urinary bladder debris could be consistent with cells, crystals and/or exfoliated material.
- The splenic parenchyma changes are most consistent with a benign process such as lymphoid hyperplasia, extramedullary hematopoiesis or splenitis with a low possibility of infiltrative neoplasia (i.e., lymphoma, mast cell neoplasia).
- The hepatic changes are consistent with age-related parenchymal remodeling and are not considered clinically significant at this time.
- The pancreatic changes are most consistent with age-related parenchymal remodeling, potentially secondary to a prior inflammatory episode, early fibrosis or chronic pancreatitis.

**INTERPRETED BY**

Andrea Nicastro, DVM,  
Diplomate ACVIM  
(*Small Animal Internal  
Medicine*)

**IMAGING PERFORMED BY**

Jessica Miller

**HOSPITAL NAME**

Companion AH  
Parsippany

**REFERRING VET**

Dr. Wolf

**INTERPRETATION OF THE FINDINGS & FURTHER RECOMMENDATIONS**

- Three-view thoracic radiographs are recommended to assess for pulmonary metastases.
- Consider a urine BRAF test to further assess for lower urinary tract neoplasia. It should be noted, however, that a negative BRAF test does not exclude the possibility of cancer. Therefore,

**INVOICE**

13722

**DATE**

7/12/22



**PATIENT**

Brutus Zierenberg

if a negative result is obtained, consider further testing (i.e., traumatic urethral catheterization or prostatic biopsy).

**SPECIES**

Canine

**BREED**

Australian Cattle dog mix

**SEX**

Male, neutered

**AGE**

8 Yrs.

**WEIGHT**

42.13 lbs.

**INTERPRETED BY**

Andrea Nicastro, DVM,  
Diplomate ACVIM  
(Small Animal Internal  
Medicine)

**IMAGING PERFORMED BY**

Jessica Miller

**HOSPITAL NAME**

Companion AH  
Parsippany

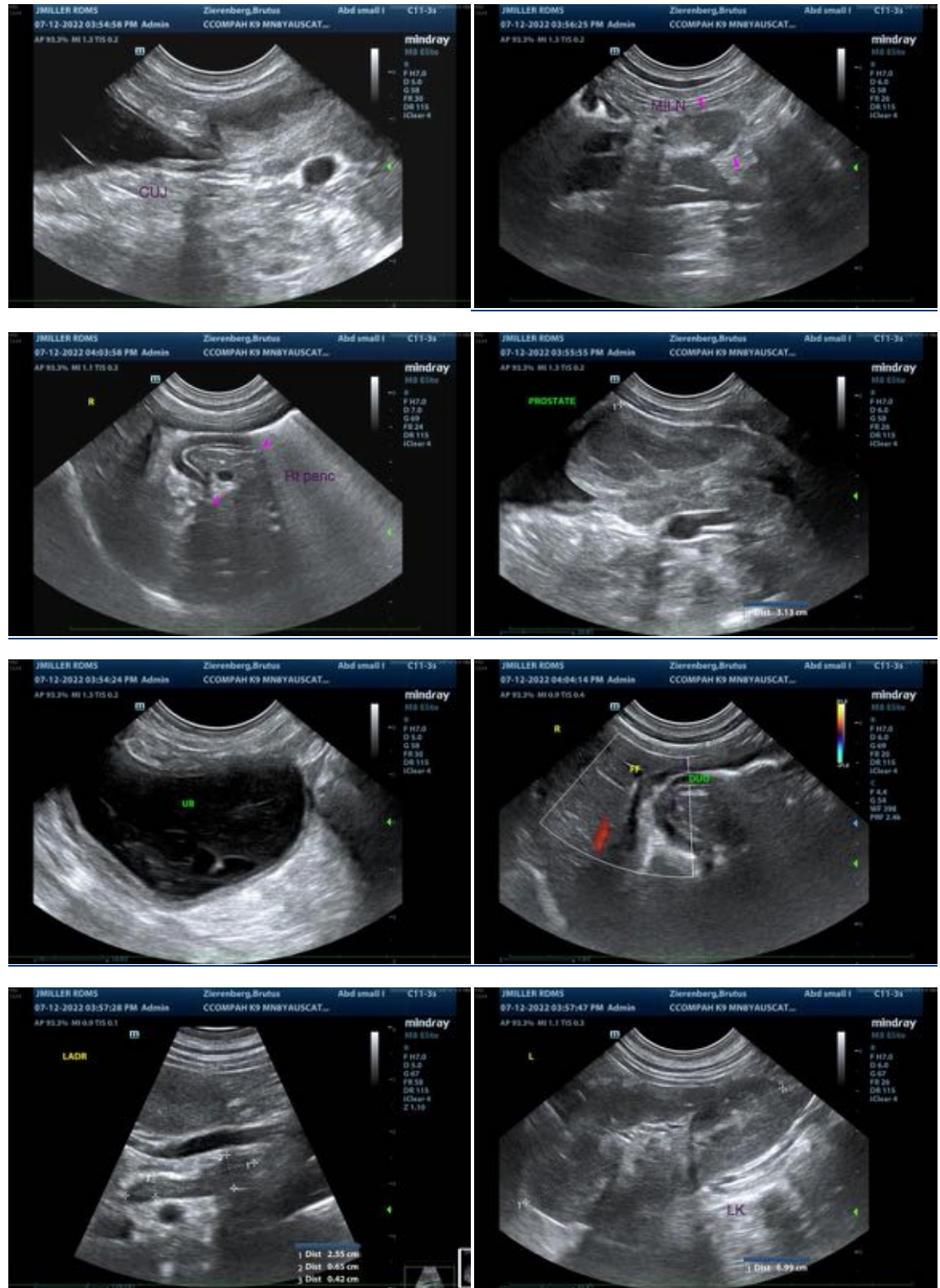
**REFERRING VET**

Dr. Wolf

**INVOICE**

13722

**DATE**  
7/12/22





**PATIENT**

Brutus Zierenberg

**SPECIES**

Canine

**BREED**

Australian Cattle dog  
mix

**SEX**

Male, neutered

**AGE**

8 Yrs.

**WEIGHT**

42.13 lbs.

**INTERPRETED BY**

Andrea Nicastro, DVM,  
Diplomate ACVIM  
(*Small Animal Internal  
Medicine*)

**IMAGING  
PERFORMED BY**

Jessica Miller

**HOSPITAL NAME**

Companion AH  
Parsippany

**REFERRING VET**

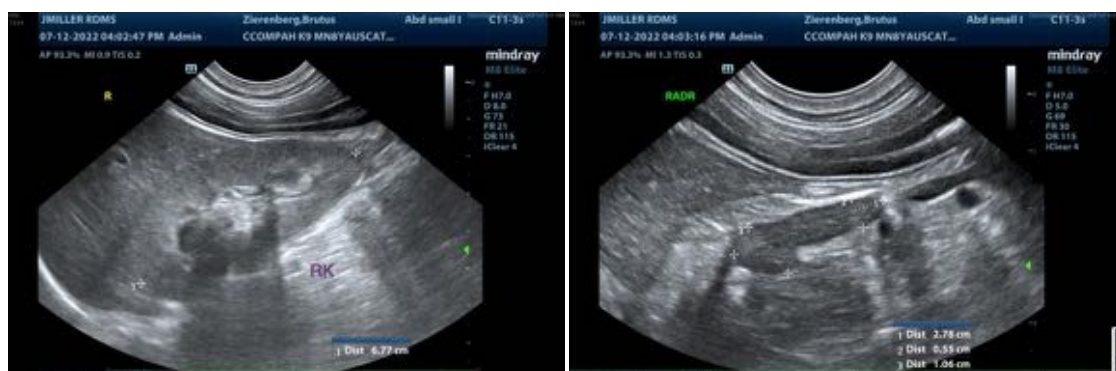
Dr. Wolf

**INVOICE**

13722

**DATE**

7/12/22



The information and recommendations provided are based on the images presented by the referring veterinarian/sonographer. No evaluation can be communicated regarding pathology that was not visible in the image/video clips provided.

Thank you for this referral. If the clinical or image interpretation does not parallel your findings or if I can be of any further assistance please contact me.

Andrea Nicastro, DVM, Diplomate ACVIM (*Small Animal Internal Medicine*)

Andrea.nicastro@sonopath.com