



PATIENT

Walter Paloma

PRESENTING CLINICAL SIGNS

History: Patient presents for hematuria, stranguria, and urgency. No current meds.
Abnormal PE/Chem/CBC/UA Results: CBC/Chem: WNL. U/A: hematuria, negative culture.

SPECIES

Canine

ULTRASONOGRAPHIC EXAMINATION OF THE ABDOMEN

Urinary System

The urinary bladder is mildly to moderately distended. In the region of the apex and ventral aspect, the wall is severely thickened (up to 2.11 cm), irregular in appearance with loss of the normal layering pattern at the dorsoapical aspect. The remaining bladder wall is normal in thickness with a smooth mucosal surface. A scant amount of echogenic debris is observed within the lumen. The region of the trigone and the proximal urethra, visible to a depth of 4-5 cm, are normal.

BREED

Labrador Retriever

SEX

Male, neutered

The prostate is not definitively visualized due to its pelvic location.

AGE

7 Yrs.

The left kidney is normal size (6.74 cm in length); normal shape and architecture with smooth peripheral margins. There is a normal 1:3 cortex to medulla ratio with minimal loss of corticomedullary distinction. There is no evidence of pyelectasia, nephroliths, infarcts or hydronephrosis. Renal vasculature is normal.

WEIGHT

87 lbs.

The right kidney is normal size (6.27 cm in length); normal shape and architecture with smooth peripheral margins. There is a normal 1:3 cortex to medulla ratio with minimal loss of corticomedullary distinction. There is no evidence of pyelectasia, nephroliths, infarcts or hydronephrosis. Renal vasculature is normal.

Adrenal Glands

INTERPRETED BY

Andrea Nicastro, DVM,
Diplomate ACVIM
(Small Animal Internal
Medicine)

The left adrenal gland is normal size (0.67 cm at cranial pole) (0.68 cm at caudal pole) (2.43 cm in length); normal shape; homogenous parenchyma. The glandular echogenicity and detail are unremarkable. Capsule, cortex, and medullary definition are normal. The phrenicoabdominal vein and surrounding vasculature are normal.

The right adrenal gland is normal size (1.31 cm at cranial pole) (0.85 cm at caudal pole) (2.99 cm in length); normal shape; homogenous parenchyma. The glandular echogenicity and detail are unremarkable. Capsule, cortex, and medullary definition are normal. The phrenicoabdominal vein and surrounding vasculature are normal.

IMAGING PERFORMED BY

Kelly Vazquez, CVT

Spleen

HOSPITAL NAME

Cresskill AH

The spleen is subjectively normal in size (2.26 cm in width at the level of the hilus) with normal curvilinear peripheral contours. The parenchyma is diffusely and severely mottled in appearance. A 2.06 x 1.77 cm irregular heterogeneous slightly cavitated nodule/mass is observed at the cranial aspect. Splenic vasculature appears normal with no evidence of thrombosis.

REFERRING VET

Dr. Joe Khodari

Liver

The liver is subjectively normal in size with normal contours and structure. There is appropriate echogenicity and echotexture. No overt structural evidence of inflammatory, infiltrative or regenerative pathology is evident. Vascular and biliary tracts are of normal volume with no evidence of congestion. No pathological hepatic lymphadenopathy observed. The gall bladder lumen is moderately distended. The wall is thin and smooth. Luminal contents are anechoic. The cystic and common bile ducts are normal/not seen.

INVOICE

13445

DATE

5/31/22



PATIENT

Gastrointestinal

Walter Paloma

The stomach and intestine are free of stasis and exhibit normal peristaltic activity. The gastric lumen is not distended. The gastric wall and pylorus are normal in thickness with a normal layering pattern. The pyloric outflow tract is patent. The small intestinal lumen is not dilated. The small intestinal wall thickness is normal with a normal layering pattern and appropriate mural detail. Discreet masses are not identified. The colonic wall is normal. No obstructive disease is noted.

SPECIES

Canine

Pancreas

The region of the pancreas is isoechoic relative to surrounding omental fat. No obvious parenchymal abnormalities are observed. There is no evidence of regional inflammation or effusion.

BREED

Labrador Retriever

SEX

Male, neutered

Free Abdomen

The peritoneal cavity is normal. There is no evidence of inflammation or effusion. The abdominal lymph nodes are normal/not visible.

AGE

7 Yrs.

ULTRASONOGRAPHIC FINDINGS

WEIGHT

87 lbs.

- The urinary bladder wall changes are concerning for infiltrative neoplasia (i.e., transitional cell carcinoma). However, severe cystitis cannot be completely excluded.
- The splenic nodule/mass could be consistent with neoplasia (i.e., hemangioma, hemangiosarcoma). Alternatively, a benign process (i.e., multi-septated cystic area) cannot be completely excluded. The diffuse splenic parenchymal changes could be consistent with infiltrative neoplasia (i.e., round cell tumor) or a benign process (i.e., lymphoid hyperplasia, extramedullary hematopoiesis or similar).

INTERPRETED BY

Andrea Nicastro, DVM,
Diplomate ACVIM
(*Small Animal Internal
Medicine*)

INTERPRETATION OF THE FINDINGS & FURTHER RECOMMENDATIONS

- Three-view thoracic radiographs are recommended to assess for pulmonary metastases.
- A urine BRAF test is recommended to further evaluate for lower urinary tract neoplasia. However, it should be noted that a negative BRAF test does not rule out the possibility of cancer. If a negative test result is obtained, a urinary bladder wall biopsy may be necessary to get a definitive diagnosis.
- Regarding the splenic nodule, consider a splenectomy with submission of the spleen for histopathology. If a more conservative approach is desired, consider a repeat ultrasound in 3-4 weeks to assess for progression of the nodule/mass. A fine needle aspirate of the mottled portion of the spleen can also be considered if clotting status is appropriate. The cystic nodule should be avoided when performing the aspiration due to the risk of iatrogenic hemorrhage.

**IMAGING
PERFORMED BY**

Kelly Vazquez, CVT

HOSPITAL NAME

Cresskill AH

REFERRING VET

Dr. Joe Khodari

INVOICE

13445

DATE

5/31/22



PATIENT

Walter Paloma

SPECIES

Canine

BREED

Labrador Retriever

SEX

Male, neutered

AGE

7 Yrs.

WEIGHT

87 lbs.

INTERPRETED BY

Andrea Nicastro, DVM,
Diplomate ACVIM
(Small Animal Internal
Medicine)

**IMAGING
PERFORMED BY**

Kelly Vazquez, CVT

HOSPITAL NAME

Cresskill AH

REFERRING VET

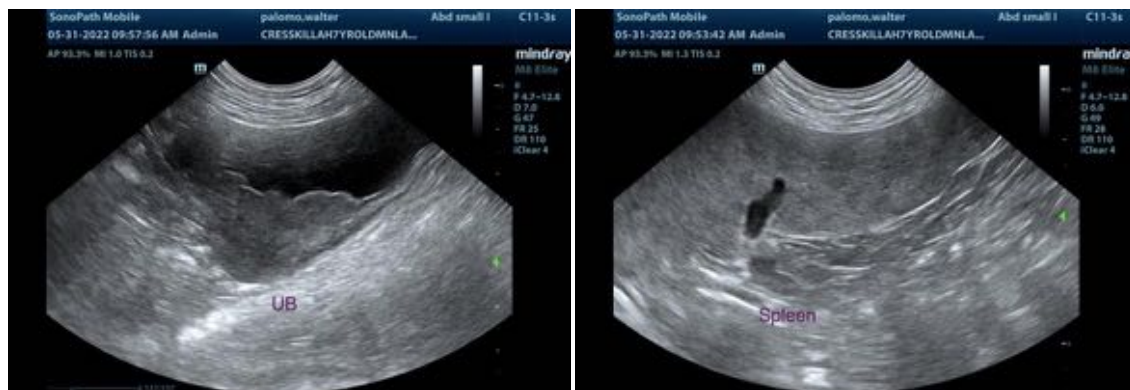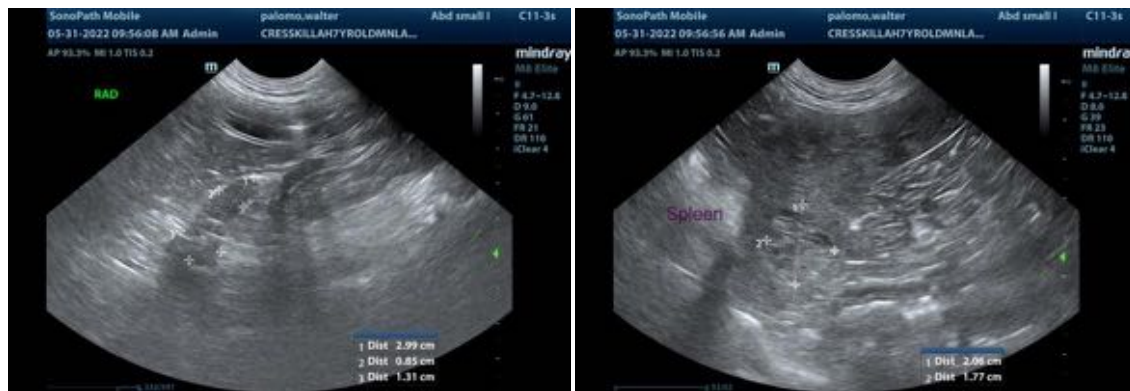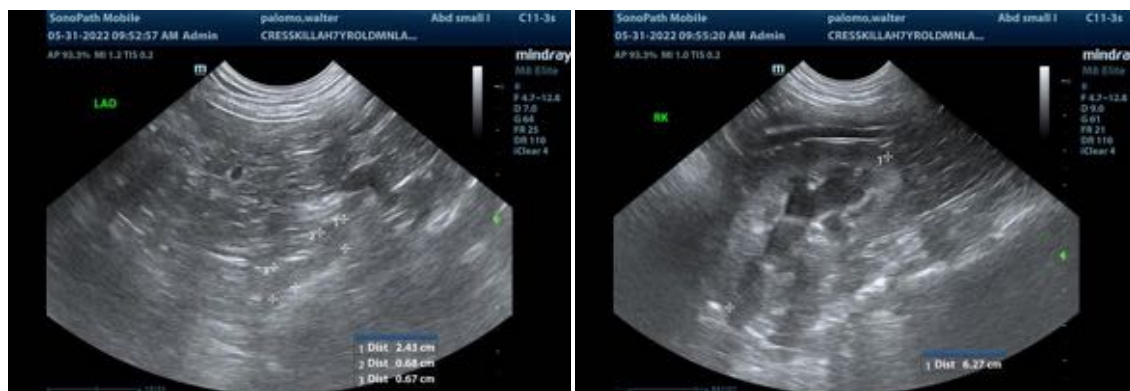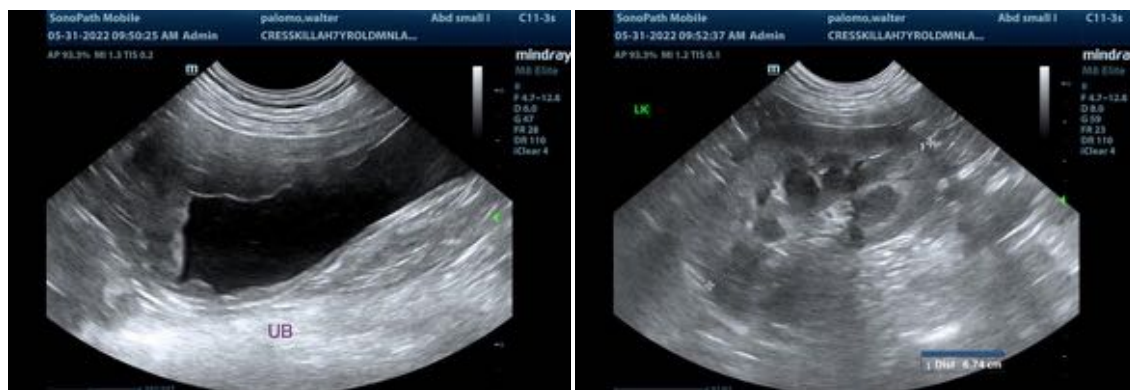
Dr. Joe Khodari

INVOICE

13445

DATE

5/31/22





PATIENT

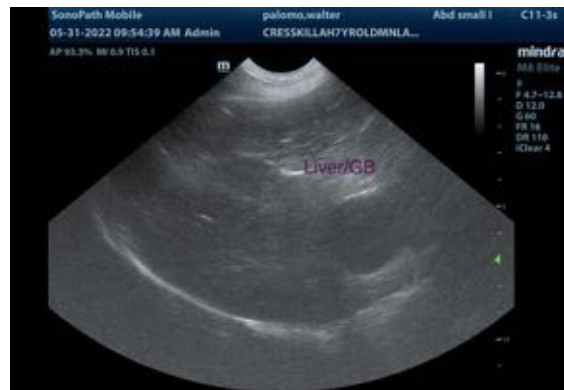Walter Paloma

SPECIES

Canine

BREED

Labrador Retriever



SEX

Male, neutered

AGE

7 Yrs.

WEIGHT

87 lbs.

INTERPRETED BY

Andrea Nicastro, DVM,
Diplomate ACVIM
(*Small Animal Internal
Medicine*)

**IMAGING
PERFORMED BY**

Kelly Vazquez, CVT

HOSPITAL NAME

Cresskill AH

REFERRING VET

Dr. Joe Khodari

INVOICE

13445

DATE

5/31/22

The information and recommendations provided are based on the images presented by the referring veterinarian/sonographer. No evaluation can be communicated regarding pathology that was not visible in the image/video clips provided.

Thank you for this referral. If the clinical or image interpretation does not parallel your findings or if I can be of any further assistance please contact me.

Andrea Nicastro, DVM, Diplomate ACVIM (*Small Animal Internal Medicine*)

Andrea.nicastro@sonopath.com