SonoPath

Clinical Sonography & Telecytology

EDUCATIONAL TELECONSULTATION SERVICES™

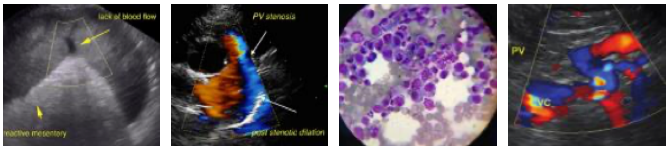

SonoPath.com™

1-800-838-4268 info@sonopath.com

PATIENT

Finnegan Lansey

SPECIES

Canine

BREED

Chihuahua mix

SEX

Male, neutered

AGE

3 Yrs.

WEIGHT

23.5 lbs.

INTERPRETED BY

Andrea Nicastro, DVM, Diplomate ACVIM (*Small Animal Internal Medicine*)

IMAGING PERFORMED BY

Kelly Vazquez , CVT

HOSPITAL NAME

Ramapo Valley AH

REFERRING VET

Dr. Katara

INVOICE

13415

DATE

5/24/22

PRESENTING CLINICAL SIGNS

History: History of chronic diarrhea since young, soft stool, hematochezia and intermittent vomiting.
Current meds: Tylan powder, Cerenia (as needed).
Abnormal PE/Chem/CBC/UA Results: EOS 2205, albumin 2.5, SDMA 16.9 as of 5/5/22.

ULTRASONOGRAPHIC EXAMINATION OF THE ABDOMEN

Urinary System

The urinary bladder, trigone, and pelvic urethra are normal in thickness and the mucosal surface is smooth. The bladder lumen is mildly distended. A scant amount of echogenic debris is observed within the lumen. No masses, inflammatory changes or calculi are observed. The region of the trigone and the visible portion of the proximal urethra are normal.

The prostate is normal in size (1.06 cm in length; 0.71 cm in width) and shape. Parenchyma is homogenous. The prostatic urethra appears normal without evidence of dilation or obstruction.

The left kidney is normal size (5.09 cm in length); normal shape and architecture with smooth peripheral margins. There is a normal 1:3 cortex to medulla ratio with normal corticomedullary distinction. There is no evidence of pyelectasia, nephroliths, infarcts or hydroureter. Renal vasculature is normal.

The right kidney is normal size (4.08 cm in length); normal shape and architecture with smooth peripheral margins. There is a normal 1:3 cortex to medulla ratio with normal corticomedullary distinction. There is no evidence of pyelectasia, nephroliths, infarcts or hydroureter. Renal vasculature is normal.

Adrenal Glands

The left adrenal gland is normal size (0.41 cm at cranial pole) (0.31 cm at caudal pole) (0.99 cm in length); normal shape; homogenous parenchyma. The glandular echogenicity and detail are unremarkable. Capsule, cortex, and medullary definition are normal. The phrenicoabdominal vein and surrounding vasculature are normal.

The right adrenal gland is normal size (0.40 cm at cranial pole) (0.39 cm at caudal pole) (1.38 cm in length); normal shape; homogenous parenchyma. The glandular echogenicity and detail are unremarkable. Capsule, cortex, and medullary definition are normal. The phrenicoabdominal vein and surrounding vasculature are normal.

Spleen

The spleen is normal in size with a normal capsular contour. There is appropriate echogenicity and echotexture. No focal lesions are observed. Splenic vasculature is normal.

Liver

The liver is subjectively normal in size with normal contours and structure. There is appropriate echogenicity and echotexture. No overt structural evidence of inflammatory, infiltrative or regenerative pathology is evident. Vascular and biliary tracts are of normal volume with no evidence of congestion. No pathological hepatic lymphadenopathy observed. The gall bladder lumen is moderately distended. The wall is thin and smooth. Luminal contents are anechoic. The cystic and common bile ducts are normal/not seen.

Gastrointestinal

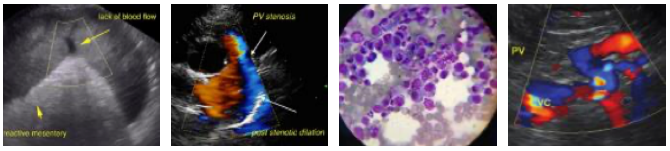

SonoPath.com
1-800-838-4268 info@sonopath.com

PATIENT

Finnegan Lansey

SPECIES

Canine

BREED

Chihuahua mix

SEX

Male, neutered

AGE

3 Yrs.

WEIGHT

23.5 lbs.

INTERPRETED BY

Andrea Nicastro, DVM, Diplomate ACVIM (*Small Animal Internal Medicine*)

IMAGING PERFORMED BY

Kelly Vazquez , CVT

HOSPITAL NAME

Ramapo Valley AH

REFERRING VET

Dr. Katara

INVOICE

13415

DATE

5/24/22

The gastric lumen is mildly distended with ingesta. The gastric wall and pylorus are normal in thickness with a normal layering pattern. The pyloric outflow tract is patent. The small intestinal lumen is not dilated. The small intestinal wall is diffusely thickened (up to 0.50 cm) with retention of the normal layering pattern. There is disruption in the normal 1:3 muscularis: mucosal ratio with a 1:1 ratio in some segments. Discreet masses are not identified. The ileocecal colic junction and colonic wall are normal. No obstructive disease is noted.

Pancreas

The region of the pancreas is isoechoic relative to surrounding omental fat. No obvious parenchymal abnormalities are observed. There is no evidence of regional inflammation or effusion.

Free Abdomen

The peritoneal cavity is normal. There is no evidence of inflammation or effusion. 1-2 mesenteric lymph nodes are visible, the largest measuring 1.55 cm in length.

ULTRASONOGRAPHIC FINDINGS

- The clinical history, in conjunction with the small intestinal wall changes, are most concerning for inflammatory bowel disease. However, emerging neoplasia (i.e., lymphoma) cannot be completely excluded.
- The lymph node changes are most consistent with reactive lymphadenitis or lymphoid hyperplasia.

INTERPRETATION OF THE FINDINGS & FURTHER RECOMMENDATIONS

- Given the eosinophilia, a fecal evaluation for ova and giardia, prophylactic deworming with Fenbendazole and an ACTH stimulation test (to assess for hypoadrenocorticism) are recommended.
- A malabsorption panel including serum cobalamin folate, TLI and PLI should also be considered.
- A 6-week limited antigen diet trial to assess for food allergies.
- Ultimately, endoscopic or surgical gastrointestinal biopsies may be necessary to get a definitive diagnosis.
- To further assess for concurrent causes of hypoalbuminemia, consider pre and post prandial serum bile acids and a UPC (if proteinuria is present).

SonoPath

Clinical Sonography & Telecytology

EDUCATIONAL TELECONSULTATION SERVICES™

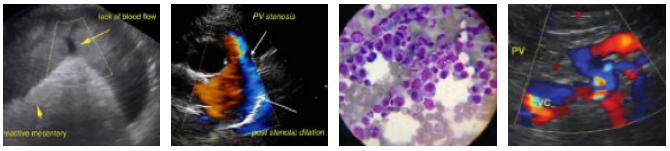

SonoPath.com™

1-800-838-4268 info@sonopath.com

PATIENT

Finnegan Lansey

SPECIES

Canine

BREED

Chihuahua mix

SEX

Male, neutered

AGE

3 Yrs.

WEIGHT

23.5 lbs.

INTERPRETED BY

Andrea Nicastro, DVM, Diplomate ACVIM (*Small Animal Internal Medicine*)

IMAGING PERFORMED BY

Kelly Vazquez , CVT

HOSPITAL NAME

Ramapo Valley AH

REFERRING VET

Dr. Katara

INVOICE

13415

DATE

5/24/22

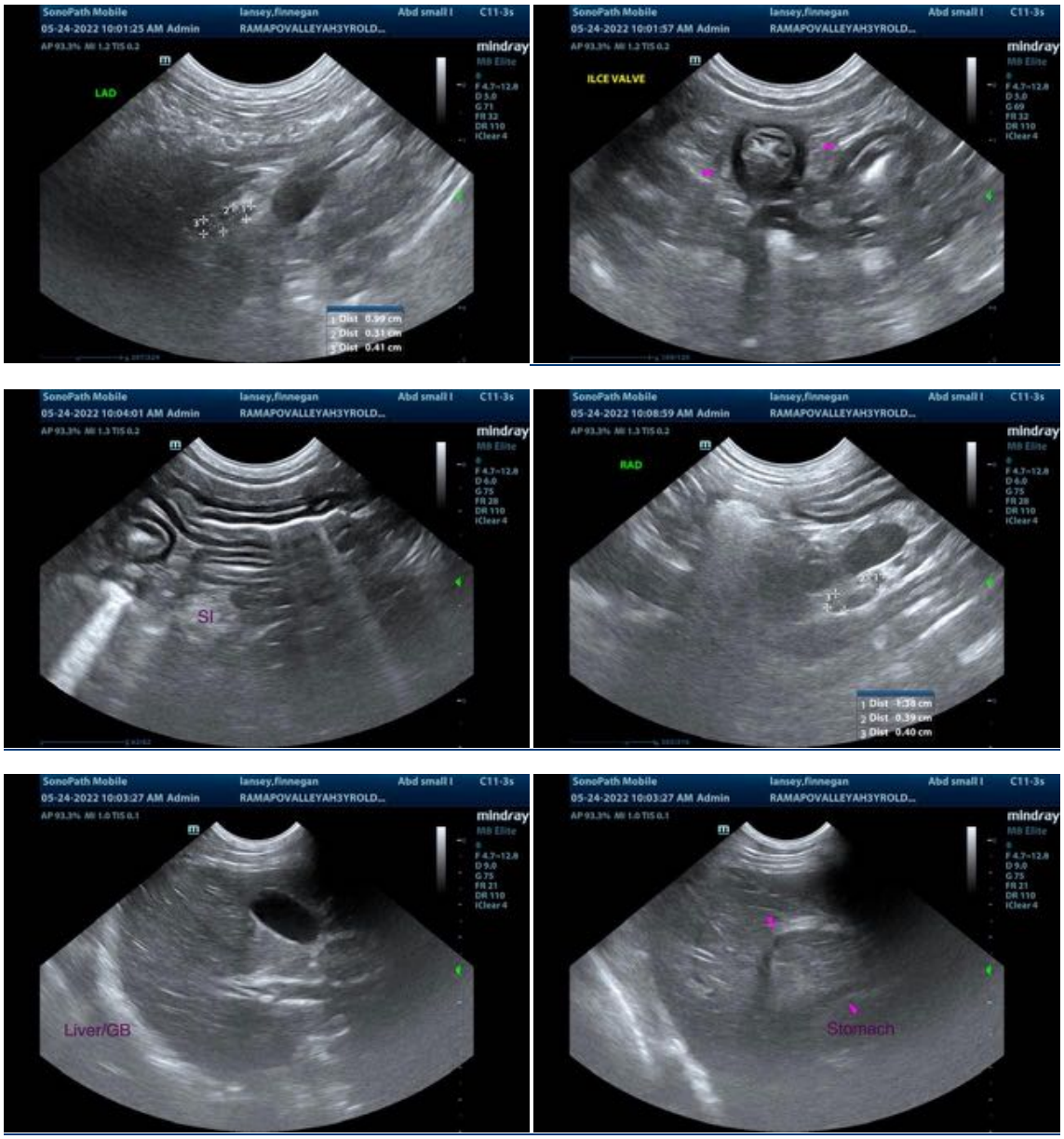

The information and recommendations provided are based on the images presented by the referring veterinarian/sonographer. No evaluation can be communicated regarding pathology that was not visible in the image/video clips provided.

Thank you for this referral. If the clinical or image interpretation does not parallel your findings or if I can be of any further assistance please contact me.

Andrea Nicastro, DVM, Diplomate ACVIM (*Small Animal Internal Medicine*)

Andrea.nicastro@sonopath.com