



PATIENT PRESENTING CLINICAL SIGNS

Jax Rankin History: Chronic progressing elevation in liver values since 2/5/22. Has been on ursodial for the past 6 months
Abnormal PE/Chem/CBC/UA Results: ALKP: 2/5/22 486, 7/9/22 511, 10/4/22 928, 2/11/23 1385. pre and post bile acids wnl, ACTH wnl.

SPECIES

Canine

ULTRASONOGRAPHIC EXAMINATION OF THE ABDOMEN

BREED

Urinary System

Pit bull

The urinary bladder and visible portion of the pelvic urethra are normal for the degree of luminal distension. The urine is anechoic with no evidence of debris. Cystic calculi and discrete masses are not observed. The region of the trigone and the proximal urethra, visible to a depth of 2-3 cm, are normal.

SEX

Male, neutered

The prostate is normal in size (0.84 cm in width) and shape. Parenchyma is homogenous. The prostatic urethra appears normal without evidence of dilation or obstruction.

AGE

9 Yrs.

The left kidney is normal size (6.08 cm in length); normal shape and architecture with smooth peripheral margins. There is a normal 1:3 cortex to medulla ratio with minimal to mild loss of corticomedullary distinction. There is no evidence of pyelectasia, nephroliths, infarcts or hydroureter. Renal vasculature is normal.

WEIGHT

The right kidney is normal size (6.49 cm in length); normal shape and architecture with smooth peripheral margins. There is a normal 1:3 cortex to medulla ratio with minimal to mild loss of corticomedullary distinction. There is no evidence of pyelectasia, nephroliths, infarcts or hydroureter. Renal vasculature is normal.

INTERPRETED BY

Adrenal Glands

Andrea Nicastro, DVM,
Diplomate ACVIM
(Small Animal Internal
Medicine)

The left adrenal gland is normal size (0.90 cm at cranial pole) (0.60 cm at caudal pole) (2.78 cm in length); normal shape; homogenous parenchyma. The glandular echogenicity and detail are unremarkable. Capsule, cortex, and medullary definition are normal. The phrenicoabdominal vein and surrounding vasculature are normal.

IMAGING PERFORMED BY

Diane McFadden,
RVT

The right adrenal gland is mildly enlarged (1.40 cm at cranial pole) (1.02 cm at caudal pole) (2.18 cm in length) with a slightly irregular shape. The glandular echogenicity and detail are unremarkable. Capsule, cortex, and medullary definition are normal. The phrenicoabdominal vein and surrounding vasculature are normal.

HOSPITAL NAME

Denville AH

Spleen

The spleen is normal in size (1.95 cm in width at the level of the hilus) with a normal capsular contour. There is appropriate echogenicity and echotexture. No focal lesions are observed. Splenic vasculature is normal.

REFERRING VET

Dr. Reddy

Liver

The liver is subjectively normal in size with normal curvilinear peripheral contours. The parenchyma is isoechoic relative to the spleen and diffusely homogeneous in appearance. No distinct focal lesions are observed. Vascular and biliary tracts are of normal volume with no evidence of congestion. The gall bladder lumen is moderately distended. The wall is thin and smooth. A scant amount of gravity-dependent echogenic debris is observed within the lumen. The cystic and common bile ducts are normal/not seen.

INVOICE

14600

DATE

2/20/23



PATIENT

Gastrointestinal

Jax Rankin

The gastric lumen is mildly distended with ingesta. The gastric wall is normal in thickness with a normal layering pattern. The small intestinal lumen is not dilated. The small intestinal wall thickness is normal with a normal layering pattern and appropriate mural detail. Discreet masses are not identified. The colonic wall is normal. There is no evidence of an obstructive pattern.

SPECIES

Canine

Pancreas

BREED

Pit bull

The region of the pancreas is isoechoic relative to surrounding omental fat. No obvious parenchymal abnormalities are observed. There is no evidence of regional inflammation or effusion.

SEX

Male, neutered

Free Abdomen

The peritoneal cavity is normal. There is no evidence of inflammation or effusion. A 1.59 cm medial iliac lymph node is visualized. The node is normal in shape and echogenicity.

AGE

9 Yrs.

ULTRASONOGRAPHIC FINDINGS

WEIGHT

- The hepatic parenchymal changes are non-specific and are most consistent with a benign hepatopathy. Vacuolar hepatopathy (i.e., idiopathic, endocrine) is the top differential. In light of the normal ALT, inflammatory disease is considered less likely. Infiltrative neoplasia is possible but also considered unlikely given the sonographic appearance of the liver.
- The mild right adrenomegaly may be a normal variant for this patient or may represent early hyperplastic change.

INTERPRETED BY

Andrea Nicastro, DVM,
Diplomate ACVIM
(*Small Animal Internal
Medicine*)

INTERPRETATION OF THE FINDINGS & FURTHER RECOMMENDATIONS

- Hepatic tissue sampling (i.e., fine needle aspirate or biopsy) can be considered at this time. A more conservative approach would be to recheck liver values every 3 months. If values continue to increase, consider a repeat ultrasound +/- hepatic tissue sampling at that time.
- Consider testing for hyperadrenocorticism with a low-dose dexamethasone suppression test or ACTH stimulation test if clinical signs (i.e., PU/PD) develop in the future.

**IMAGING
PERFORMED BY**

Diane McFadden,
RVT

HOSPITAL NAME

Denville AH

REFERRING VET

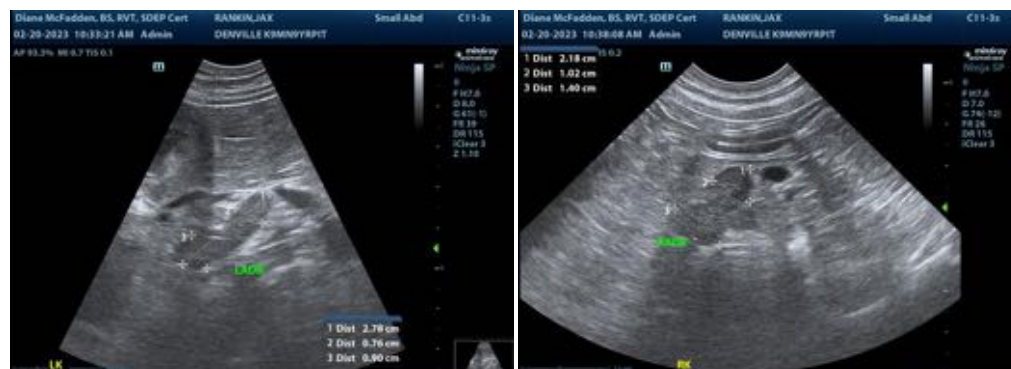Dr. Reddy

INVOICE

14600

DATE

2/20/23





PATIENT

Jax Rankin

SPECIES

Canine

BREED

Pit bull

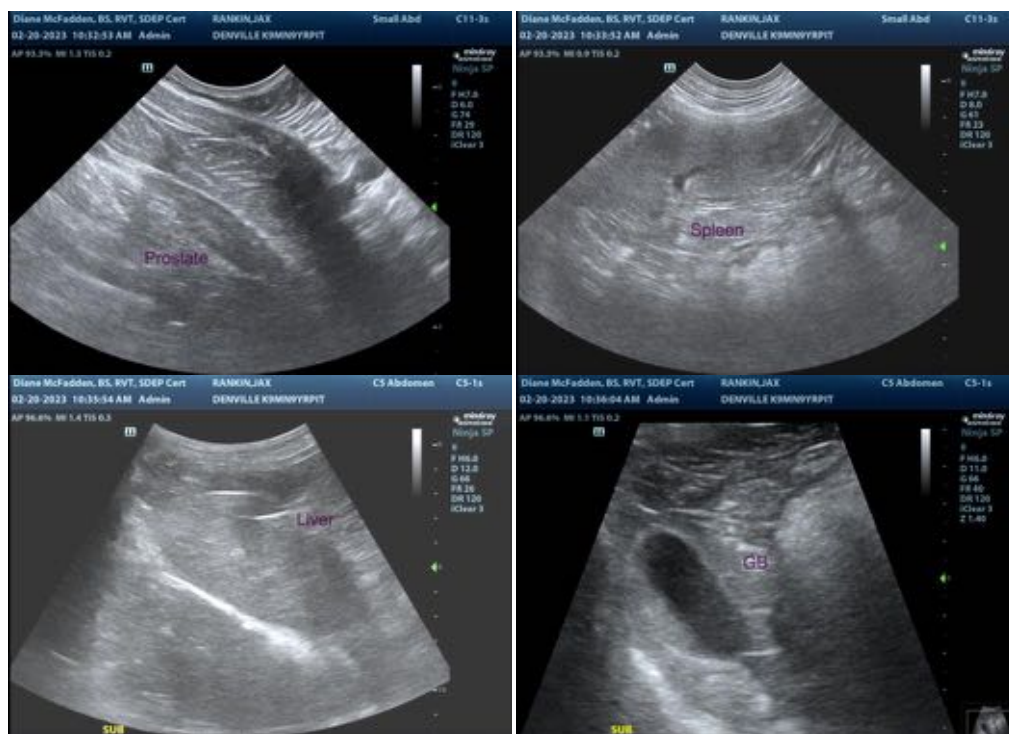
SEX

Male, neutered

AGE

9 Yrs.

WEIGHT



INTERPRETED BY

Andrea Nicastro, DVM,
Diplomate ACVIM
(Small Animal Internal
Medicine)

The information and recommendations provided are based on the images presented by the referring veterinarian/sonographer. No evaluation can be communicated regarding pathology that was not visible in the image/video clips provided.

Thank you for this referral. If the clinical or image interpretation does not parallel your findings or if I can be of any further assistance please contact me.

Andrea Nicastro, MPH, DVM, Diplomate DACVIM (Small Animal Internal Medicine)
info@SonoPath.com

IMAGING PERFORMED BY

Diane McFadden,
RVT

HOSPITAL NAME

Denville AH

REFERRING VET

Dr. Reddy

INVOICE

14600

DATE

2/20/23