



PATIENT

Mason Lombardy

PRESENTING CLINICAL SIGNS

History: Check for bladder stones, check bladder.

SPECIES

Canine

BREED

Terrier

SEX

Male, neutered

AGE

11 Yrs.

WEIGHT

21.5 lbs.

INTERPRETED BY

Andrea Nicastro, DVM,
Diplomate ACVIM
(*Small Animal Internal
Medicine*)

**IMAGING
PERFORMED BY**

Jessica Miller

HOSPITAL NAME

Willowbrook AC

REFERRING VET

Dr. Palescandolo

INVOICE

14525

DATE

1/31/23

ULTRASONOGRAPHIC EXAMINATION OF THE ABDOMEN

Urinary System

The urinary bladder is mildly distended. A 2.29 cm irregular mineralized vascular mass is observed in the region of the trigone. The remaining urinary bladder wall is of appropriate thickness for the level of repletion. The mucosal surface in the region of the apex is irregular. A scant amount of echogenic debris is observed within the lumen. No cystic calculi are observed. The visible portion of the proximal urethra appears normal.

The prostate is normal in size (1.08 cm in width) and shape. Parenchyma is homogenous. The prostatic urethra appears normal without evidence of dilation or obstruction.

The left kidney is normal in size (5.01 cm in length) with a normal shape, smooth peripheral margins and normal internal architecture. There is mild loss of corticomedullary distinction. Several hyperechoic shadowing diverticular foci are observed. There is no evidence of pyelectasia, infarcts or hydronephrosis. Renal vasculature is normal.

The right kidney is normal size (4.62 cm in length) with a normal shape, smooth peripheral margins and normal internal architecture. There is mild loss of corticomedullary distinction. Several hyperechoic shadowing diverticular foci are observed. A few cortical cysts are seen, the largest measuring 0.74 cm in diameter at the medial aspect. There is no evidence of pyelectasia, infarcts or hydronephrosis. Renal vasculature is normal.

Adrenal Glands

The left adrenal gland is normal size (0.47 cm at cranial pole) (0.56 cm at caudal pole) (1.60 cm in length); normal shape; homogenous parenchyma. The glandular echogenicity and detail are unremarkable. Capsule, cortex, and medullary definition are normal. The phrenicoabdominal vein and surrounding vasculature are normal.

The right adrenal gland is normal size (0.47 cm at cranial pole) (0.52 cm at caudal pole) (1.72 cm in length); normal shape; homogenous parenchyma. The glandular echogenicity and detail are unremarkable. Capsule, cortex, and medullary definition are normal. The phrenicoabdominal vein and surrounding vasculature are normal.

Spleen

The spleen is normal in size (1.26 cm in width at the level of the hilus) with a normal capsular contour. The parenchyma is subtly mottled in appearance. A few small myelolipomas are visualized in the region of the hilus. Splenic vasculature is normal.

Liver

The liver is subjectively normal in size with normal curvilinear peripheral contours. The parenchyma is hypoechoic relative to the spleen with minor changes consistent with age-related remodeling. No focal lesions are observed. Hepatic vasculature and biliary tracts are of normal volume with no evidence of congestion. The portal vein to caudal vena cava ratio is approximately 1:1. The gallbladder is of normal contours and contains some dependent echogenic debris. The wall is normal in thickness. No choleliths are observed. The cystic and common bile ducts are normal.

Gastrointestinal



PATIENT

Mason Lombardy

The stomach and intestine are free of stasis and exhibit normal peristaltic activity. The gastric lumen is not distended. The gastric wall and pylorus are normal in thickness with a normal layering pattern. The pyloric outflow tract is patent. The small intestinal lumen is not dilated. The small intestinal wall thickness is normal with a normal layering pattern and appropriate mural detail. Discreet masses are not identified. The ileocecolic junction and colonic wall are normal. No obstructive disease is noted.

SPECIES

Canine

Pancreas

The base and limbs of the pancreas are normal in size with normal curvilinear peripheral contours. The parenchyma is largely isoechoic relative to surrounding omental fat and slightly mottled in appearance. The pancreatic duct is visible but not overtly dilated. There is no evidence of peripancreatic inflammation or effusion.

BREED

Terrier

SEX

Male, neutered

Free Abdomen

The peritoneal cavity is normal. There is no evidence of inflammation or effusion. In the right cranial quadrant, a 1.90 x 0.99 cm irregular cystic structure, suspected to be a lymph node, is visualized. In addition, a 0.61 cm lymph node is observed in the mid to caudal abdomen.

AGE

11 Yrs.

ULTRASONOGRAPHIC FINDINGS

WEIGHT

21.5 lbs.

Primary Findings:

- Urinary bladder mass in the region of the trigone. Neoplasia (i.e., transitional cell carcinoma) is the top differential with a lower possibility of a focal inflammatory process.

Secondary Findings:

- Minor, age-related renal and hepatic changes.
- The pancreatic changes are most consistent with age-related parenchymal remodeling, potentially secondary to a prior inflammatory episode, early fibrosis or chronic pancreatitis.
- The splenic parenchymal changes are most consistent with a benign process such as lymphoid hyperplasia, extramedullary hematopoiesis, splenitis or antigenic stimulation with a low possibility of infiltrative neoplasia (i.e., lymphoma, mast cell neoplasia).
- The significance of the cystic lymph node in the right cranial quadrant is unclear. It may represent a reactive node, benign cysts or less likely, an emerging tumor.

INTERPRETED BY

Andrea Nicastro, DVM,
Diplomate ACVIM
(*Small Animal Internal
Medicine*)

**IMAGING
PERFORMED BY**

Jessica Miller

HOSPITAL NAME

Willowbrook AC

INTERPRETATION OF THE FINDINGS & FURTHER RECOMMENDATIONS

- Three-view thoracic radiographs are recommended to assess for pulmonary metastases.
- A urine BRAF test is recommended to further evaluate for lower urinary tract neoplasia. It should be noted, however, that a negative result does not rule out the possibility of neoplasia. If a negative result is obtained, additional testing (i.e., biopsies) may be necessary to get a definitive diagnosis.
- If urinary bladder neoplasia is confirmed, consider initiation of Piroxicam +/- Misoprostol (as a gastric protectant). Also consider consultation with a board-certified oncologist for further diagnostic/treatment recommendations.

REFERRING VET

Dr. Palescandolo

INVOICE

14525

DATE

1/31/23



PATIENT

Mason Lombardy

SPECIES

Canine

BREED

Terrier

SEX

Male, neutered

AGE

11 Yrs.

WEIGHT

21.5 lbs.

INTERPRETED BY

Andrea Nicastro, DVM,
Diplomate ACVIM
(Small Animal Internal
Medicine)

IMAGING PERFORMED BY

Jessica Miller

HOSPITAL NAME

Willowbrook AC

REFERRING VET

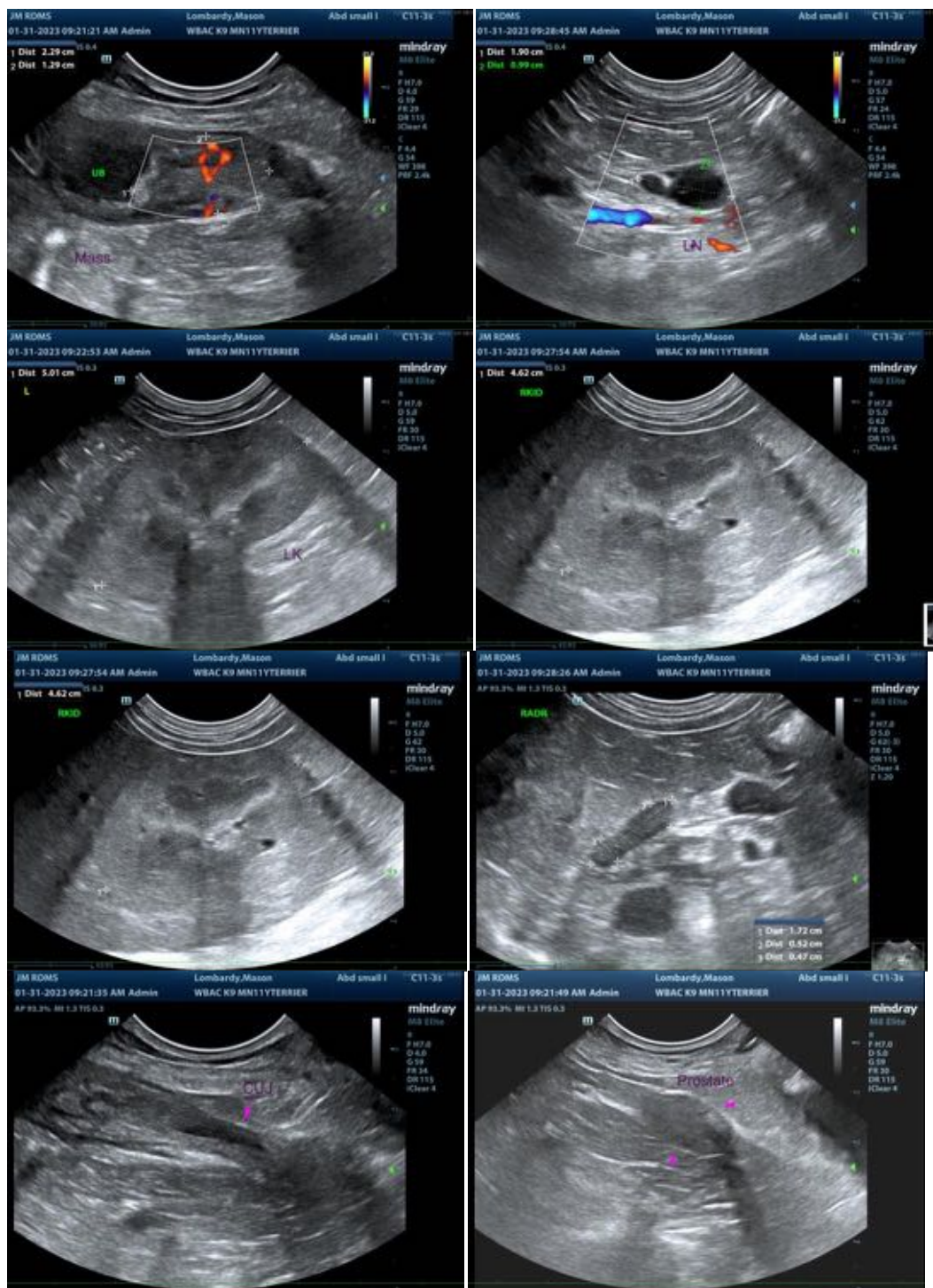
Dr. Palescandolo

INVOICE

14525

DATE

1/31/23





PATIENT

Mason Lombardy

SPECIES

Canine

BREED

Terrier

SEX

Male, neutered

AGE

11 Yrs.

WEIGHT

21.5 lbs.

INTERPRETED BY

Andrea Nicastro, DVM,
Diplomate ACVIM
(Small Animal Internal
Medicine)

**IMAGING
PERFORMED BY**

Jessica Miller

HOSPITAL NAME

Willowbrook AC

REFERRING VET

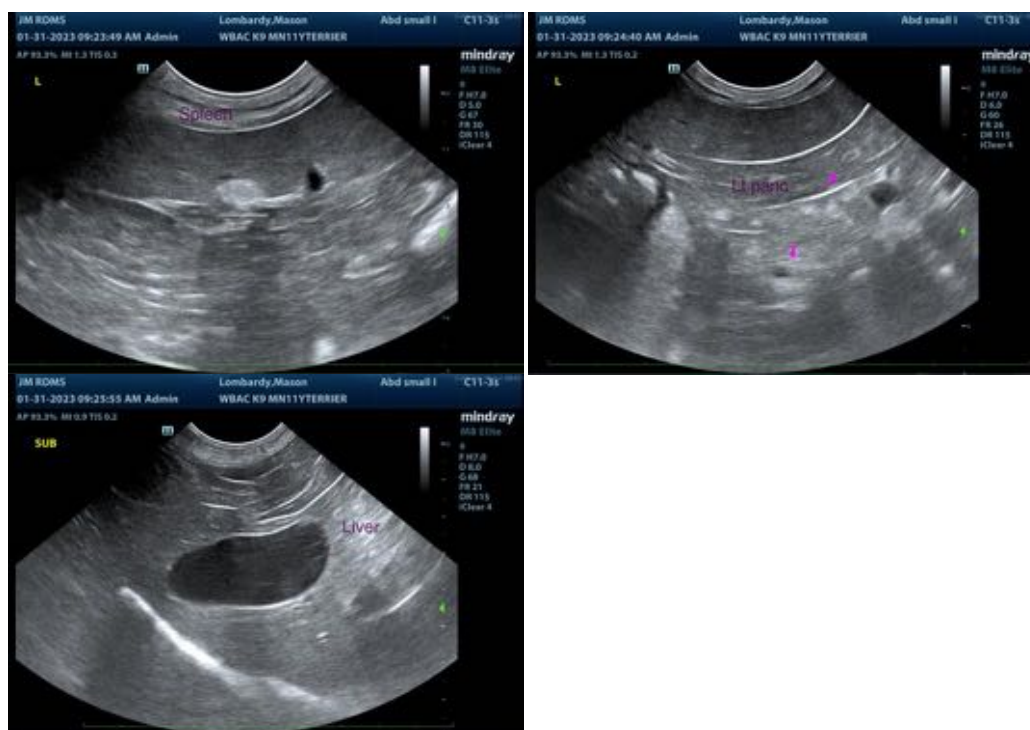
Dr. Palescandolo

INVOICE

14525

DATE

1/31/23



The information and recommendations provided are based on the images presented by the referring veterinarian/sonographer. No evaluation can be communicated regarding pathology that was not visible in the image/video clips provided.

Thank you for this referral. If the clinical or image interpretation does not parallel your findings or if I can be of any further assistance please contact me.

Andrea Nicastro, MPH, DVM, Diplomate DACVIM (Small Animal Internal Medicine)
info@SonoPath.com