

PATIENT PRESENTING CLINICAL SIGNS

Milo Avalos

History:

- 2/3/26 - was scheduled for dental; pre-op x-rays revealed FB. Exploratory was performed and folded rubber mat in stomach removed.
- Since sx, as per O, bump under right caudal ribs. Unable to palpate w/ O in room.

SPECIES

Canine

BREED

Shih Tzu

Abnormal PE/Chem/CBC/UA Results: Day of sx chem WNL. RBC 5.33, WBC 4.41, Lymph 0.82, MPV 13.4

ULTRASONOGRAPHIC EXAMINATION OF THE ABDOMEN

SEX

Male, neutered

Urinary System

The urinary bladder wall is normal in thickness and the mucosal surface is smooth. The bladder is moderately distended. A scant amount of suspended echogenic debris is observed within the lumen. No cystic calculi are observed. The region of the trigone and the proximal urethra, visible to a depth of 2.5 cm, are normal.

AGE

11 Yrs.

The prostate is mildly enlarged (1.43 cm in width) with smooth peripheral contours. The parenchyma is homogeneous. The prostatic urethra is not overtly dilated.

WEIGHT

21.8 lbs.

The left kidney is normal in size (4.28 cm in length) with a normal shape, architecture and smooth peripheral margins. There is a normal 1:3 cortex to medulla ratio with mild loss of corticomedullary distinction. An ill-defined hyperechoic medullary band is observed at the corticomedullary junction. There is no evidence of pyelectasia, nephroliths, infarcts or hydroureter. Renal vasculature is normal.

INTERPRETED BY

Andrea Nicastro, DVM,
 Diplomate ACVIM
 (Small Animal Internal
 Medicine)

The right kidney is normal in size (4.28 cm in length) with a normal shape, architecture and smooth peripheral margins. There is a normal 1:3 cortex to medulla ratio with mild loss of corticomedullary distinction. An ill-defined hyperechoic medullary band is observed at the corticomedullary junction. There is no evidence of pyelectasia, nephroliths, infarcts or hydroureter. Renal vasculature is normal.

Adrenal Glands

The left adrenal gland is normal in size (0.39 cm at cranial pole) (0.50 cm at caudal pole) with a normal shape and homogenous parenchyma. The glandular echogenicity and detail are unremarkable. Capsule, cortex, and medullary definition are normal. The phrenicoabdominal vein and surrounding vasculature are normal.

IMAGING PERFORMED BY

Vincetn Ravancho

The region of the right adrenal gland is evaluated. No obvious pathology is observed in this region.

HOSPITAL NAME

Whippany VH

Spleen

The spleen is normal in size (1.72 cm in width at the level of the hilus) with a normal capsular contour. There is appropriate echogenicity and echotexture. No focal lesions are observed. Splenic vasculature is normal.

REFERRING VET

Dr. Cordero

Liver

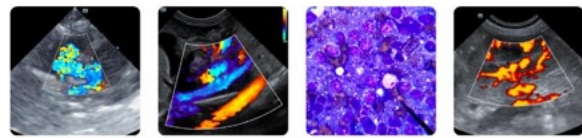
The liver is subjectively normal in size with normal contours and structure. There is appropriate echogenicity and echotexture. No overt structural evidence of inflammatory, infiltrative, or regenerative pathology is evident. Vascular and biliary tracts are of normal volume with no evidence of congestion.

INVOICE

13637

DATE
 3/24/26

The gall bladder lumen is moderately distended. The wall is thin and smooth. A small amount of aggregated hyperechoic debris is observed within the lumen. The cystic and common bile ducts are normal/not seen.



PATIENT

Milo Avalos

SPECIES

Canine

BREED

Shih Tzu

SEX

Male, neutered

AGE

11 Yrs.

WEIGHT

21.8 lbs.

INTERPRETED BY

Andrea Nicastro, DVM,
Diplomate ACVIM
(Small Animal Internal
Medicine)

IMAGING PERFORMED BY

Vincetn Ravancho

HOSPITAL NAME

Whippany VH

REFERRING VET

Dr. Cordero

INVOICE

13637

DATE

3/24/26

Gastrointestinal

The gastric lumen contains a scant amount of shadowing material. The gastric wall is normal in thickness with a normal layering pattern. The small intestinal lumen is not dilated. The small intestinal wall thickness is normal with a normal layering pattern and appropriate mural detail. Discreet masses are not identified. The colonic wall is normal. There is no evidence of an obstructive pattern.

Pancreas

The region of the pancreas is isoechoic relative to surrounding omental fat. No obvious parenchymal abnormalities are observed. There is no evidence of regional inflammation or effusion.

Lymph nodes

The abdominal lymph nodes are normal/not visible.

Free Abdomen

The peritoneal cavity is normal. There is no evidence of inflammation or effusion.

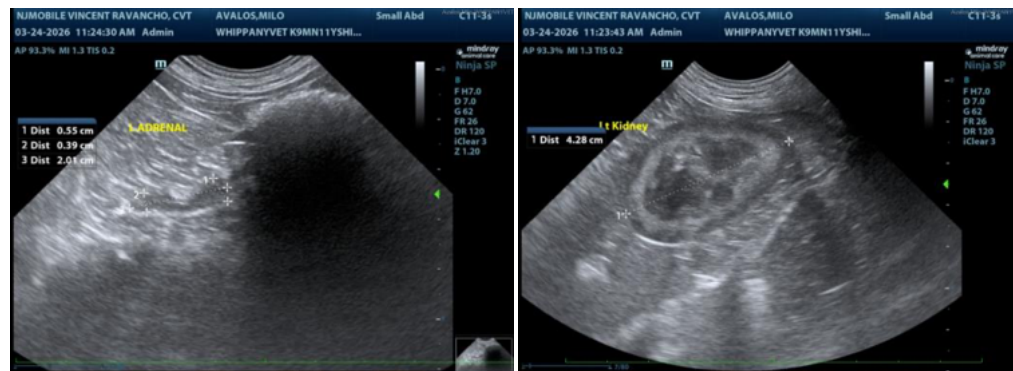
ULTRASONOGRAPHIC FINDINGS

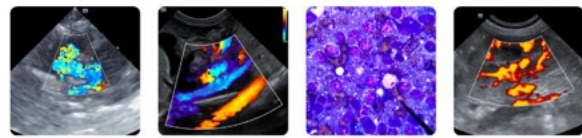
- Mild bilateral nonspecific, age-related renal changes
- The scant shadowing material within the gastric lumen may represent normal ingesta and/or foreign material. It appears non-obstructive at the time of this study.
- Mild prostatomegaly. This may be a normal variant for this patient or could be secondary to late-in-live neutering (if applicable), prostatitis, emerging neoplasia, other.

*An obvious source for the bump under the right caudal ribs is not identified in this study.

INTERPRETATION OF THE FINDINGS & FURTHER RECOMMENDATIONS

1. Monitoring of the area in question is recommended.
2. Regarding the mild prostatomegaly, consider a urine BRAF test to further evaluate for lower urinary tract neoplasia, particularly if clinical suspicion for disease is high.





PATIENT

Milo Avalos

SPECIES

Canine

BREED

Shih Tzu

SEX

Male, neutered

AGE

11 Yrs.

WEIGHT

21.8 lbs.

INTERPRETED BY

Andrea Nicastro, DVM,
 Diplomate ACVIM
 (Small Animal Internal
 Medicine)

**IMAGING
 PERFORMED BY**

Vincetn Ravancho

HOSPITAL NAME

Whippany VH

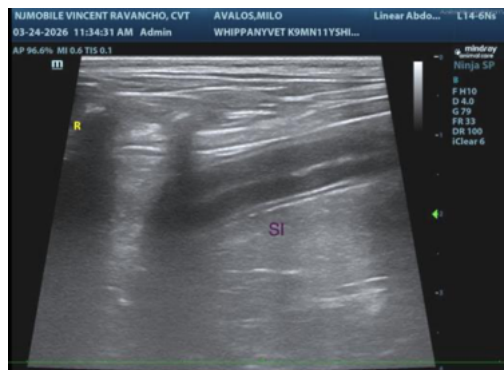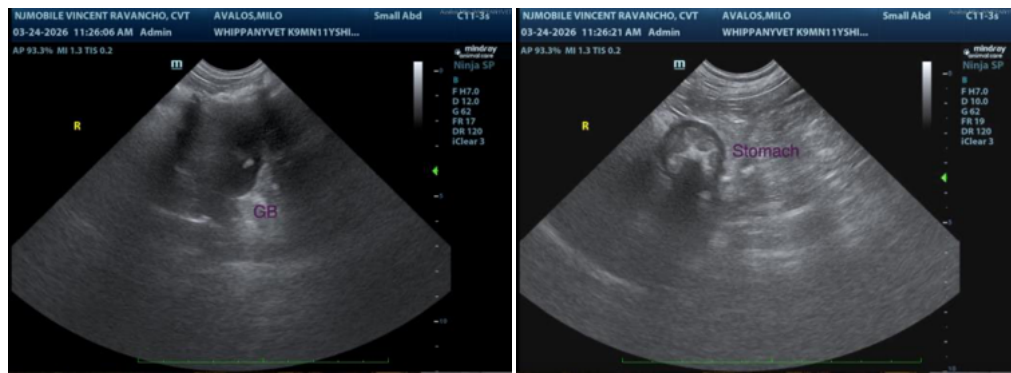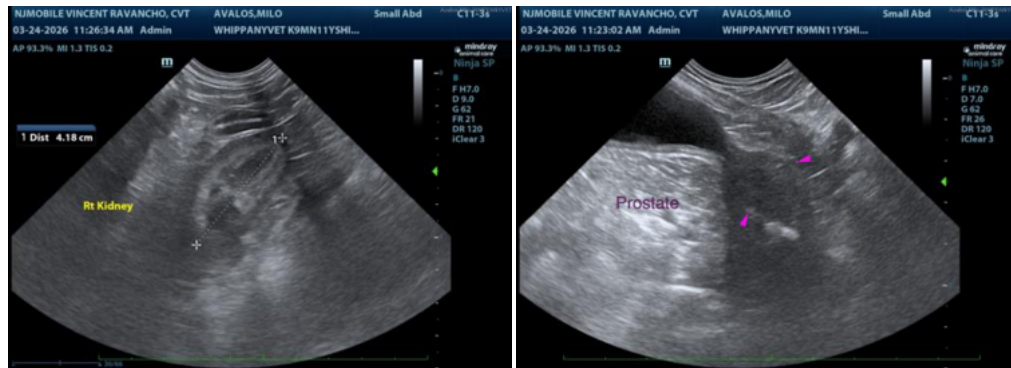
REFERRING VET

Dr. Cordero

INVOICE

13637

DATE
 3/24/26



The information and recommendations provided are based on the images presented by the referring veterinarian/sonographer. No evaluation can be communicated regarding pathology that was not visible in the image/video clips provided.

Thank you for this referral. If the clinical or image interpretation does not parallel your findings or if I can be of any further assistance please contact me.

Andrea Nicastro, MPH, DVM, Diplomate DACVIM (Small Animal Internal Medicine)
info@SonoPath.com