

**PATIENT**

Mufassa Hulshouser

**SPECIES**

Feline

**BREED**

Domestic shorthair

**SEX**

Male, neutered

**AGE**

14.5 Yrs.

**WEIGHT**

9 lbs.

**INTERPRETED BY**

Andrea Nicastro, DVM,  
Diplomate ACVIM  
(*Small Animal Internal  
Medicine*)

**IMAGING  
PERFORMED BY**

Shari Reffi

**HOSPITAL NAME**

William Penn VH

**REFERRING VET**

Dr. Mahmoud

**INVOICE**

13356

**DATE**

11/18/25

**PRESENTING CLINICAL SIGNS**

History: Not defecating. Thickened intestines, mesenteric lymphadenopathy found on previous u/s from 8/2024 (report attached) Abnormal PE/Chem/CBC/UA Results: Elevated ALT

**ULTRASONOGRAPHIC EXAMINATION OF THE ABDOMEN**

**Urinary System**

The urinary bladder wall is normal in thickness and the mucosal surface is smooth. The bladder is moderately distended. Luminal contents are anechoic. No cystic calculi are observed. The region of the trigone and the visible portion of the proximal urethra are normal.

The left kidney is normal in size (3.64 cm in length) with a normal shape, architecture and smooth peripheral margins. There is a normal 1:3 cortex to medulla ratio with mild to moderate loss of corticomedullary distinction. There is no evidence of pyelectasia, nephroliths, infarcts or hydroureter. Renal vasculature is normal.

The right kidney is normal in size (3.66 cm in length) with a normal shape, architecture and smooth peripheral margins. There is a normal 1:3 cortex to medulla ratio with mild to moderate loss of corticomedullary distinction. There is no evidence of pyelectasia, nephroliths, infarcts or hydroureter. Renal vasculature is normal.

**Adrenal Glands**

The left adrenal gland is normal size (0.45 cm width). Normal shape and glandular echogenicity. The phrenicoabdominal vein and surrounding vasculature are normal.

The right adrenal gland is normal size (0.44 cm width). Normal shape and glandular echogenicity. The phrenicoabdominal vein and surrounding vasculature are normal.

**Spleen**

The spleen is normal in size (0.81 cm in width at the level of the hilus) with a normal capsular contour. There is appropriate echogenicity and echotexture. No focal lesions are observed. Splenic vasculature is normal.

**Liver**

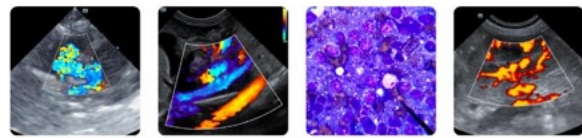
The liver is subjectively normal in size with normal peripheral contours. The parenchyma is isoechoic relative to the spleen. A 0.70 x 0.51 cm irregular hypoechoic nodule is observed at the caudal aspect approximately mid-liver. The remaining parenchyma is homogeneous. Vascular and biliary tracts are of normal volume with no evidence of congestion.

The gall bladder lumen is moderately distended. The wall is thin and smooth. Luminal contents are mostly anechoic. The cystic and common bile ducts are normal/not seen.

**Gastrointestinal**

The stomach and intestine are free of stasis and exhibit normal peristaltic activity. The gastric lumen is mildly distended with ingesta and gas. The gastric wall and pylorus are normal in thickness with a normal layering pattern. The pyloric outflow tract is patent. The small intestinal lumen is segmentally dilated with chyme. The small intestinal wall is normal to mildly thickened (up to 0.32 cm). There is disruption in the normal 1:3 muscularis: mucosal ratio in most segments. Discreet masses are not identified. The ileocecal colic junction and colonic wall are normal. The colonic lumen contains some granular appearing fecal material. No obvious obstructive disease is noted.

**Pancreas**



**PATIENT**

Mufassa Hulshouser

**SPECIES**

Feline

**BREED**

Domestic shorthair

**SEX**

Male, neutered

**AGE**

14.5 Yrs.

**WEIGHT**

9 lbs.

**INTERPRETED BY**

Andrea Nicastro, DVM,  
Diplomate ACVIM  
(Small Animal Internal  
Medicine)

**IMAGING PERFORMED BY**

Shari Reffi

**HOSPITAL NAME**

William Penn VH

**REFERRING VET**

Dr. Mahmoud

**INVOICE**

13356

**DATE**  
11/18/25

The left limb of the pancreas is visible with normal curvilinear peripheral contours. The parenchyma is slightly hypoechoic relative to surrounding omental fat and slightly mottled in appearance. The pancreatic duct is visible but not overtly dilated. There is no evidence of peripancreatic inflammation or effusion.

**Lymph nodes**

A few prominent mesenteric lymph nodes are visualized, one of the nodes measuring 1.22 x 0.94 cm. Surrounding mesentery is hyperechoic.

**Free Abdomen**

There is no obvious evidence of free fluid.

**ULTRASONOGRAPHIC FINDINGS**

**Primary Findings:**

- The small intestinal wall changes could be consistent with inflammatory bowel disease or emerging small cell lymphoma.
- The prominent abdominal lymph nodes are most consistent with reactive lymphadenitis or lymphoid hyperplasia. Neoplastic infiltration is considered less likely.
- The pancreatic changes are most consistent with age-related parenchymal remodeling, potentially secondary to a prior inflammatory episode, early fibrosis or chronic pancreatitis.
- An obvious cause for the elevated liver enzymes is not identified in the study. However, a microscopic hepatopathy (i.e., bacterial cholangiohepatitis, lymphoplasmacytic hepatitis, hepatic lipidosis, infiltrative neoplasia (less likely) should be considered. The hypoechoic hepatic nodule at the caudal aspect could be consistent with a benign focus (i.e., inflammatory, other) or an emerging tumor.

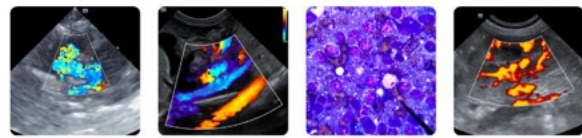
**Secondary Findings:**

- Bilateral nonspecific age-related renal changes.

\*Overall, the small intestinal and lymph node changes appear to be similar to the previous sonogram.

**INTERPRETATION OF THE FINDINGS & FURTHER RECOMMENDATIONS**

- If the patient is overtly constipated, this issue should be addressed with enemas and stool softeners as needed.
- Regarding the bowel changes, consider the following:
  1. Fecal evaluation for ova and Giardia
  2. GI panel including serum cobalamin, folate, TLI and PLI
  3. Limited antigen or hydrolyzed protein diet
  4. +/- endoscopic or surgical GI biopsies
- Regarding the elevated ALT, pre and post-prandial serum bile acids can be considered. Ultimately, liver aspirates or biopsies along with aerobic and anaerobic bile cultures may be necessary to get a definitive diagnosis. If a conservative approach is desired, consider empirical treatment for bacterial cholangiohepatitis (amoxicillin-clavulanic acid, Denamarin). If no improvement in the liver values is seen within 7-10 days of initiating therapy, antibiotics should



**PATIENT**

be discontinued, and hepatic tissue sampling reconsidered. If liver values improve, continue therapy for at least 3-4 weeks and 1 week beyond normalization of the liver values.

Mufassa Hulshouser

**SPECIES**

Feline

**BREED**

Domestic shorthair

**SEX**

Male, neutered

**AGE**

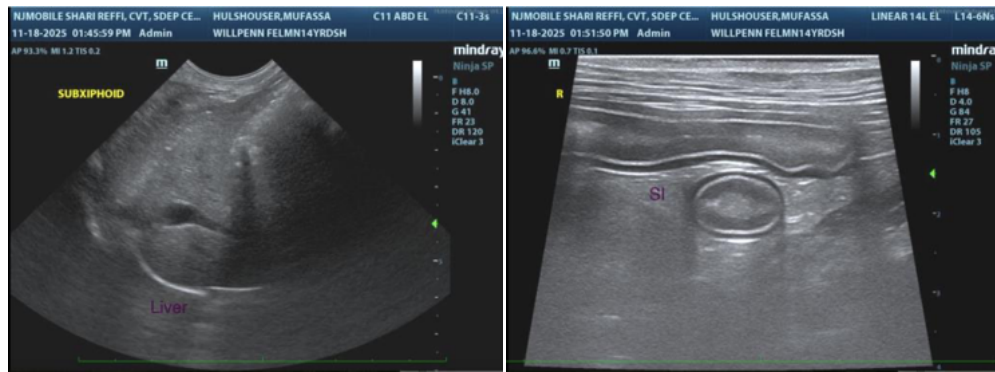
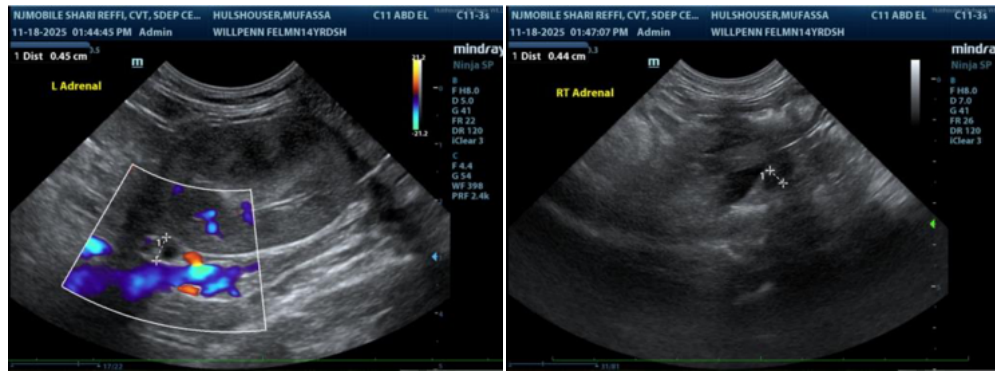
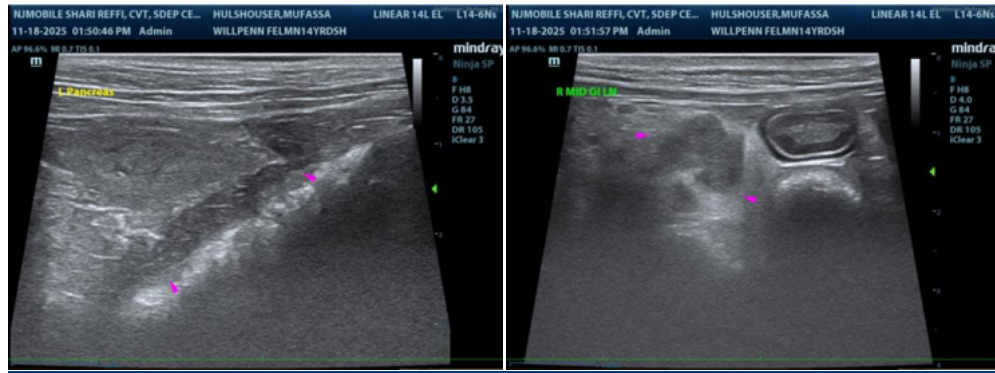
14.5 Yrs.

**WEIGHT**

9 lbs.

**INTERPRETED BY**

Andrea Nicastro, DVM,  
 Diplomate ACVIM  
 (Small Animal Internal  
 Medicine)



**IMAGING PERFORMED BY**

Shari Reffi

**HOSPITAL NAME**

William Penn VH

**REFERRING VET**

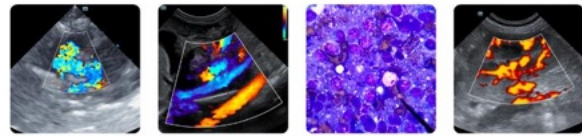
Dr. Mahmoud

**INVOICE**

13356

**DATE**

11/18/25



**PATIENT**

Mufassa Hulshouser

**SPECIES**

Feline

**BREED**

Domestic shorthair

**SEX**

Male, neutered

**AGE**

14.5 Yrs.

**WEIGHT**

9 lbs.

**INTERPRETED BY**

Andrea Nicastro, DVM,  
 Diplomate ACVIM  
 (Small Animal Internal  
 Medicine)

**IMAGING PERFORMED BY**

Shari Reffi

**HOSPITAL NAME**

William Penn VH

**REFERRING VET**

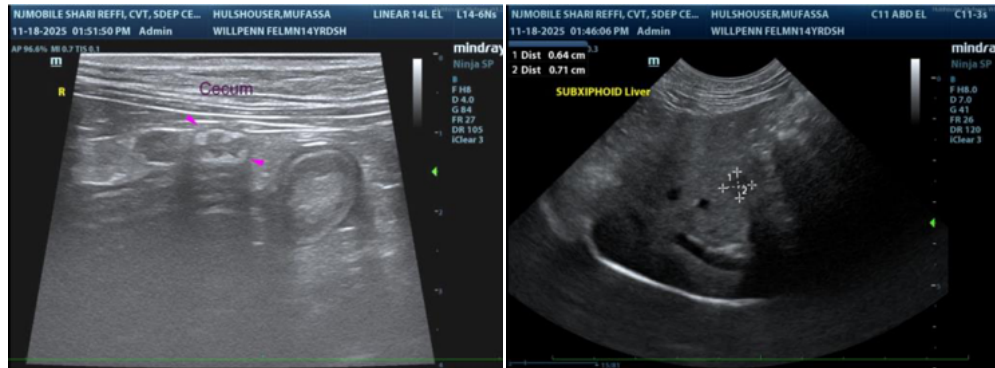
Dr. Mahmoud

**INVOICE**

13356

**DATE**

11/18/25



The information and recommendations provided are based on the images presented by the referring veterinarian/sonographer. No evaluation can be communicated regarding pathology that was not visible in the image/video clips provided.

Thank you for this referral. If the clinical or image interpretation does not parallel your findings or if I can be of any further assistance please contact me.

Andrea Nicastro, MPH, DVM, Diplomate DACVIM (Small Animal Internal Medicine)  
[info@SonoPath.com](mailto:info@SonoPath.com)