

PATIENT PRESENTING CLINICAL SIGNS

Gucci Simmons

SPECIES

Feline

BREED

Domestic shorthair

SEX

Male, neutered

AGE

7 Yrs.

WEIGHT

5.16 kg.

INTERPRETED BY

Andrea Nicastro, DVM,
Diplomate ACVIM
(Small Animal Internal
Medicine)

IMAGING PERFORMED BY

Kelly Reshny, RVT

HOSPITAL NAME

Hamilton Region
Veterinary Emergency
Clinic

REFERRING VET

Dr. Codrington

INVOICE

12025

DATE

9/7/21

History: Gucci ran away after leaving the rDVM 40 days ago and has been missing for approx 40 days. - went to rDVM on Saturday 9/5/2021. At that time, P had bladder expressed with a small stream and penis was purple in colour and swollen. UO suspected. BW at rDVM: CBC NSF, CHEM: mod/severe azotemia, concern for increased liver values ~ 2* elevation in ALP, ALT and GGT (see below). See attached. Abd X-rays were performed and apparently revealed bilateral renoliths but none in bladder (No x-rays attached in files sent). Large distended bladder. No oblique performed. -Blood and cocci found in urinalysis (Specific Gravity 1.012, pH 6.5) - O elected outpatient tx and went home with oral medications: - chart exact time that - scheudle Since then P is still lethargic and ADR Weakness/lethargy Has been shaky, weak and falling down Vomiting: 2 x Sunday 9/5/2021 at 6 am and 9:30 am, foamy stomach bile and few kibbles E/D? decreased since coming home - small amount to eat/drink (only drank 2-3mL) when returned. -Hasn't had BM or urination since being home Saturday - concentrated/partial obstruction? -P also has mild eye discharge No other c.signs - Prev medical history: Kidney/Liver disease - unsure if P had before P bolted. Urinary issues potentially prior to bolting. currently on: Cerenia 1mg/kg IV SID, ampicillin 22mg/kg IV TID, Buprenorphine 0.02mg/kg IV TID, Prazosin 1mg/kg PO TID

Abnormal PE/Chem/CBC/UA Results: rDVM BW results IDEXX SDMA 87 (0 - 14 µg/dL) H Creatinine 680 (71 - 212 µmol/L) H Urea (BUN) 35.9 (5.7 - 12.9 mmol/L) H ALT 493 (12 - 130 U/L) H ALP 311 (14 - 111) U/L H GGT 8 (0 - 4) U/L Addendum Re-check creat 619. lactate WNL ISTAT: NSF

ULTRASONOGRAPHIC EXAMINATION OF THE ABDOMEN

Urinary System

The urinary bladder is contracted/empty. The wall is of appropriate thickness for the level of repletion. No distinct calculi are observed. Mineralized sand is observed within the proximal urethra.

The left kidney is normal size (3.45 cm in length) with a slightly irregular shape. The cortex is variably thickened and irregular and there is moderately loss of corticomedullary distinction. Hyperechoic shadowing diverticular foci are visualized. There is no evidence of pyelectasia or hydroureter. Renal vasculature is normal.

The right kidney is normal size (3.81 cm in length) with a slightly irregular shape. The cortex is variably thickened and irregular and there is moderately loss of corticomedullary distinction. Hyperechoic shadowing diverticular foci are visualized. Trace pyelectasia is present. There is no evidence of hydroureter. Renal vasculature is normal.

Adrenal Glands

The region of the left adrenal gland is evaluated. No obvious pathology is observed.

The right adrenal gland is normal in size (0.33 cm width). Normal shape and glandular echogenicity. The phrenicoabdominal vein and surrounding vasculature are normal.

Spleen

The spleen is normal in size (0.85 cm in width at the level of the hilus) with a normal capsular contour. There is appropriate echogenicity and echotexture. No focal lesions are observed. Splenic vasculature is normal.

Liver

The liver is subjectively prominent in size with normal curvilinear peripheral contours. The parenchyma is isoechoic relative to the spleen and diffusely homogeneous in appearance. No focal lesions are observed. Vascular and biliary tracts are of normal volume with no evidence of congestion. The gall bladder lumen is moderately distended. The wall is thin and smooth. Luminal contents are anechoic. The cystic and common bile ducts are normal/not seen.

Gastrointestinal



PATIENT

Gucci Simmons

SPECIES

Feline

BREED

Domestic shorthair

SEX

Male, neutered

AGE

7 Yrs.

WEIGHT

5.16 kg.

INTERPRETED BY

Andrea Nicastro, DVM,
Diplomate ACVIM
(Small Animal Internal
Medicine)

**IMAGING
PERFORMED BY**

Kelly Reshny, RVT

HOSPITAL NAME

Hamilton Region
Veterinary Emergency
Clinic

REFERRING VET

Dr. Codrington

INVOICE

12025

DATE

9/7/21

The stomach and intestine are free of stasis and exhibit normal peristaltic activity. The gastric lumen is not distended. The gastric wall and pylorus are normal in thickness with a normal layering pattern. The pyloric outflow tract is patent. The small intestinal lumen is not dilated. The small intestinal wall thickness is normal with a normal layering pattern and appropriate mural detail. There is disruption in the normal 1:3 muscularis:mucosal ratio in some segments. Discreet masses are not identified. The ileocecal colic junction and colonic wall are normal. No obstructive disease is noted.

Pancreas

The region of the pancreas is isoechoic relative to surrounding omental fat. No obvious parenchymal abnormalities are observed. There is no evidence of regional inflammation or effusion.

Free Abdomen

The peritoneal cavity is normal. There is no evidence of inflammation or effusion. The abdominal lymph nodes are normal/not visible.

ULTRASONOGRAPHIC FINDINGS

- The bilateral renal changes are most consistent with chronic interstitial nephrosis/nephritis with dystrophic mineralization.
- Hepatic changes are non-specific and could be consistent with hepatic lipidosis, inflammatory/infectious disease, infiltrative neoplasia, or other hepatopathy.
- Urethral sand

INTERPRETATION OF THE FINDINGS & FURTHER RECOMMENDATIONS

- Given the azotemia, the following diagnostics/treatments can be considered:
 1. Urine culture and sensitivity.
 2. UPC (if proteinuria is present) without evidence of infection.
 3. Baseline blood pressure measurement for transition to a prescription renal diet if patient will tolerate it.
- Given the elevated liver enzymes, consider the following:
 1. Fine needle aspirate of the liver can be considered (if clotting status is appropriate). A 25-gauge needle should be used.
 2. If a more conservative approach is desired, consider empirical treatment for bacterial cholangiohepatitis. If no improvement in the liver values is seen within 7-10 days of initiating therapy, discontinue antibiotics and consider further diagnostics (i.e., hepatic tissue sampling such as FNA or biopsy).
 3. Adequate nutritional support is also strongly recommended to help prevent/treat hepatic lipidosis.
- Three-view thoracic radiographs are also recommended to assess cardiopulmonary status.



PATIENT

Gucci Simmons

SPECIES

Feline

BREED

Domestic shorthair

SEX

Male, neutered

AGE

7 Yrs.

WEIGHT

5.16 kg.

INTERPRETED BY

Andrea Nicastro, DVM,
Diplomate ACVIM
(Small Animal Internal
Medicine)

**IMAGING
PERFORMED BY**

Kelly Reshny, RVT

HOSPITAL NAME

Hamilton Region
Veterinary Emergency
Clinic

REFERRING VET

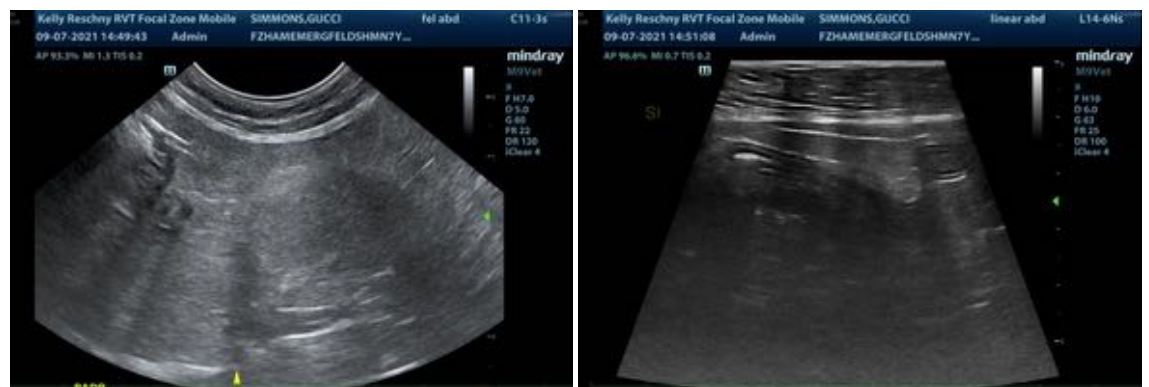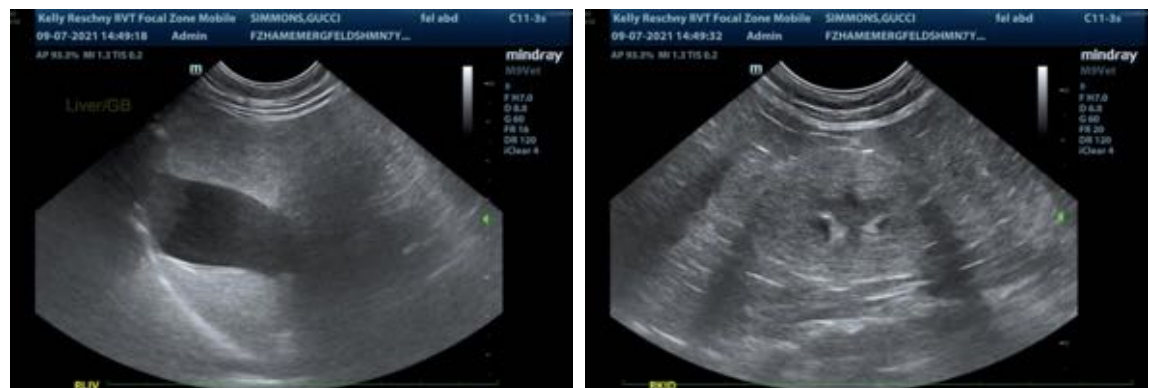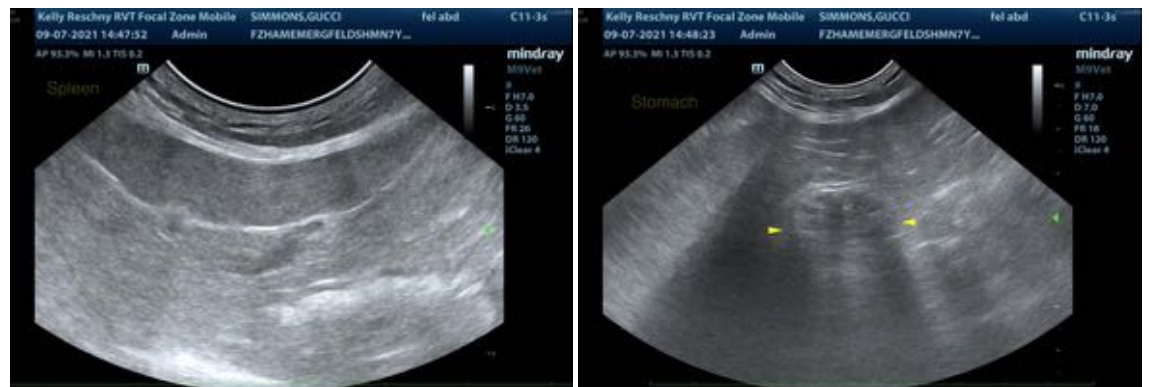
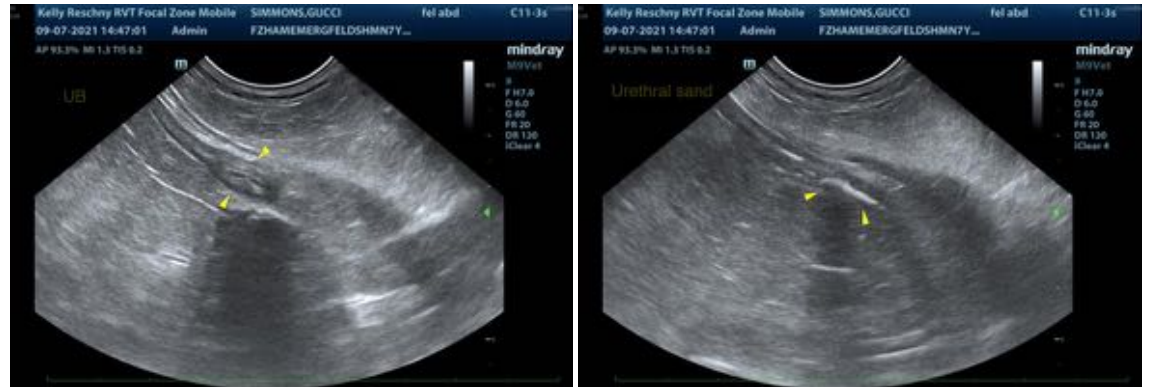Dr. Codrington

INVOICE

12025

DATE

9/7/21





PATIENT

Gucci Simmons

SPECIES

Feline

BREED

Domestic shorthair

SEX

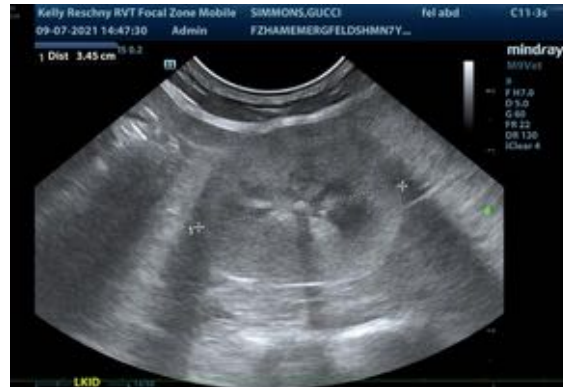Male, neutered

AGE

7 Yrs.

WEIGHT

5.16 kg.



The information and recommendations provided are based on the images presented by the referring veterinarian. No evaluation can be communicated regarding pathology that was not visible in the image/video clips provided.

Thank you for this referral. If the clinical or image interpretation does not parallel your findings or if I can be of any further assistance please contact me.

Andrea Nicastro, DVM, Diplomate ACVIM (*Small Animal Internal Medicine*)

Andrea.nicastro@sonopath.com

INTERPRETED BY

Andrea Nicastro, DVM,
Diplomate ACVIM
(*Small Animal Internal
Medicine*)

**IMAGING
PERFORMED BY**

Kelly Reshny, RVT

HOSPITAL NAME

Hamilton Region
Veterinary Emergency
Clinic

REFERRING VET

Dr. Codrington

INVOICE

12025

DATE

9/7/21