


PATIENT

Denny Crane-Scime

PRESENTING CLINICAL SIGNS

History: elevated ALT on routine BW

SPECIES

Canine

BREED

Lab Mix

SEX

Male Neutered

AGE

12 Years

WEIGHT

30 kgs.

INTERPRETED BY

 Andrea Nicastro, DVM,
 Diplomate ACVIM
 (Small Animal Internal
 Medicine)

**IMAGING
 PERFORMED BY**

Kelly Reshny, RVT

HOSPITAL NAME

Grand River VH

REFERRING VET

Dr. Robinson

**INVOICE
 12028**
**DATE
 9/7/21**
ULTRASONOGRAPHIC EXAMINATION OF THE ABDOMEN
Urinary System

The urinary bladder, trigone, and pelvic urethra are normal in thickness and the mucosal surface is smooth. The bladder lumen is mildly distended. A small amount of suspended echogenic debris is observed in the lumen. No masses, inflammatory changes or calculi are observed. Ureteral papillae and visualized portion of the proximal urethra, visible to a depth of 2 cm, are normal.

The prostate is normal in size (1.38 cm in width) and shape. Parenchyma is homogenous. The prostatic urethra appears normal without evidence of dilation or obstruction.

The left kidney is normal size (7.89 cm in length); normal shape and architecture with smooth peripheral margins. There is a normal 1:3 cortex to medulla ratio with minimal loss of corticomedullary distinction. There is no evidence of pyelectasia, nephroliths, infarcts or hydroureter. Renal vasculature is normal.

The right kidney is normal size (7.96 cm in length); normal shape and architecture with smooth peripheral margins. There is a normal 1:3 cortex to medulla ratio with minimal loss of corticomedullary distinction. There is no evidence of pyelectasia, nephroliths, infarcts or hydroureter. Renal vasculature is normal.

Adrenal Glands

The left adrenal gland is normal size (0.78 cm at cranial pole) (0.81 cm at caudal pole) (2.68 cm in length); normal shape; homogenous parenchyma. The glandular echogenicity and detail are unremarkable. Capsule, cortex, and medullary definition are normal. The phrenicoabdominal vein and surrounding vasculature are normal.

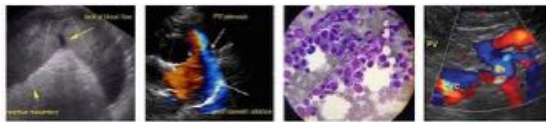
The right adrenal gland is normal size (1.44 cm at cranial pole) (0.66 cm at caudal pole) (2.16 cm in length); normal shape; homogenous parenchyma. The glandular echogenicity and detail are unremarkable. Capsule, cortex, and medullary definition are normal. The phrenicoabdominal vein and surrounding vasculature are normal.

Spleen

A 4.00 x 3.61 cm heterogeneous vascular mass is arising from the medial aspect. In the remainder of the spleen the peripheral contours are curvilinear and the parenchyma is slightly mottled in appearance. Splenic vasculature appears normal with no evidence of thrombosis.

Liver

The liver is subjectively enlarged with rounded contours on the left side. The parenchyma is isoechoic relative to the spleen. A >13 cm swelling/mass effect is observed on the left. Within this region, the parenchyma exhibits subtle heterogeneity and a few small ill-defined cavitated areas. In the remainder of the liver, the parenchyma is homogeneous and the contours are curvilinear. Vascular and biliary tracts are of normal volume with no evidence of congestion. The gall bladder lumen is cranially displaced by the hepatic mass effect. The wall is normal in thickness. Luminal contents are anechoic. The cystic and common bile ducts are normal/not seen.


PATIENT
Gastrointestinal

Denny Crane-Scime

The gastric lumen is mildly distended with ingesta. The gastric wall is normal in thickness with a normal layering pattern. The small intestinal lumen is segmentally dilated with chyme. The small intestinal wall thickness is normal with a normal layering pattern and appropriate mural detail. Discreet masses are not identified. The colonic wall is normal. No obstructive disease is noted.

SPECIES

Canine

Pancreas

A portion of the pancreas is obscured by the hepatic mass effect. In the visualized portions, no obvious pathology is visualized.

BREED

Lab Mix

Free Abdomen

The peritoneal cavity is normal. There is no evidence of inflammation or effusion. The abdominal lymph nodes are normal/not visible.

SEX

Male Neutered

Other

A brief echocardiogram reveals no evidence of pericardial effusion or obvious right atrial/auricular mass.

AGE

12 Years

ULTRASONOGRAPHIC FINDINGS
WEIGHT

30 kgs.

Primary Findings:

- Left hepatic mass effect. Differentials include neoplasia (i.e., adenoma, adenocarcinoma, round cell tumor) with a lower possibility of benign pathology (i.e., vacuolar hepatopathy, regenerative nodular hyperplasia).
- Splenic mass. Differentials include a benign process (i.e., myelolipoma) vs neoplasia (i.e., sarcoma).

Secondary Findings:

- Minor age-related renal pathology.

INTERPRETATION OF THE FINDINGS & FURTHER RECOMMENDATIONS

- Three-view thoracic radiographs are recommended to assess for pulmonary metastases.
- Consider fine needle aspirates of the left hepatic mass effect and splenic mass (if clotting status is appropriate). 25-gauge needles should be used. If cytologic evaluations are inconclusive, consider abdominal exploratory with splenectomy and liver biopsy or mass removal.

INTERPRETED BY

 Andrea Nicastro, DVM,
 Diplomate ACVIM
 (Small Animal Internal
 Medicine)

IMAGING PERFORMED BY

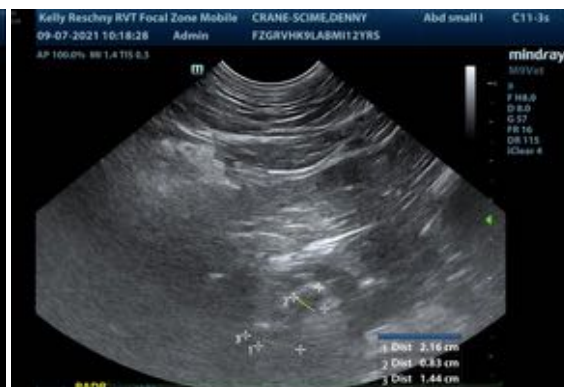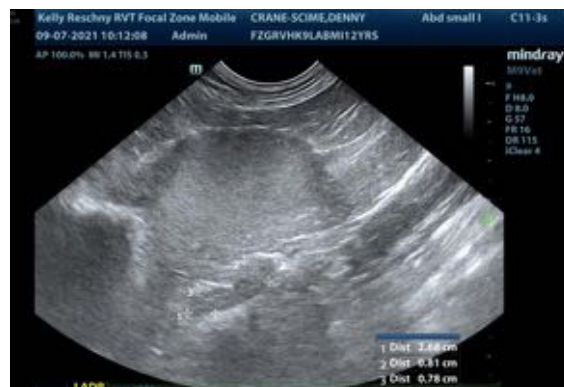Kelly Reshny, RVT

HOSPITAL NAME

Grand River VH

REFERRING VET

Dr. Robinson

**INVOICE
 12028**
DATE
 9/7/21




PATIENT

Denny Crane-Scime

SPECIES

Canine

BREED

Lab Mix

SEX

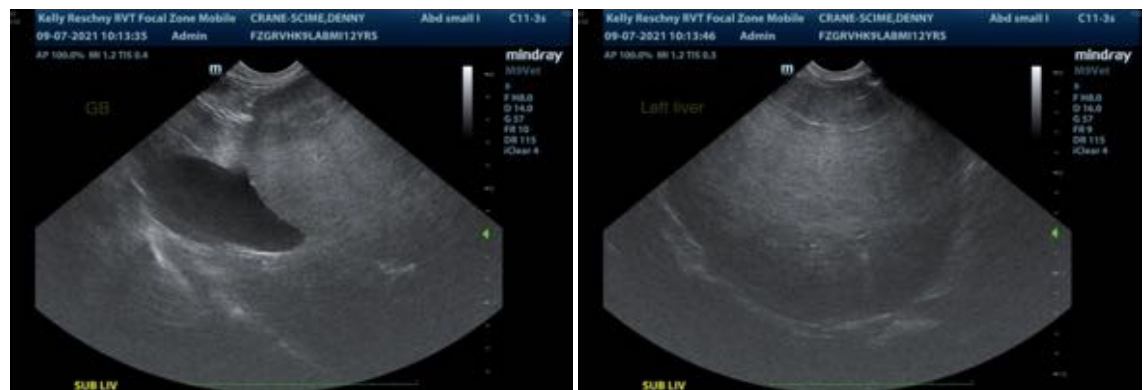
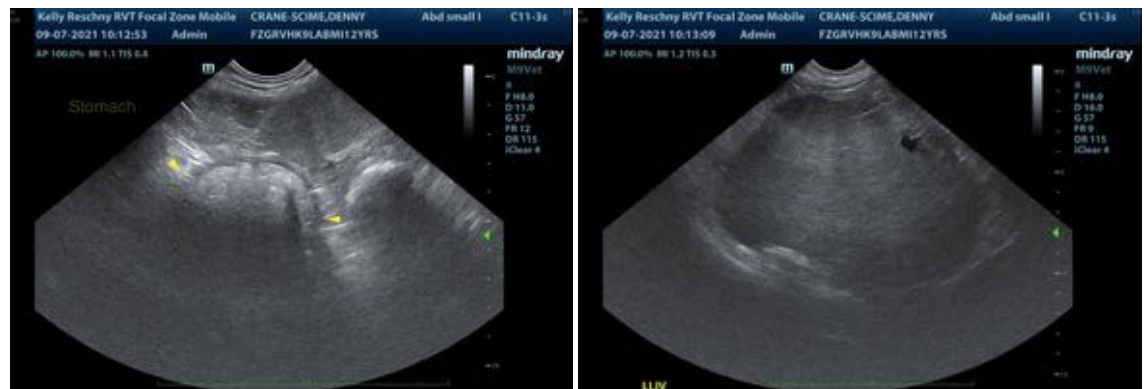
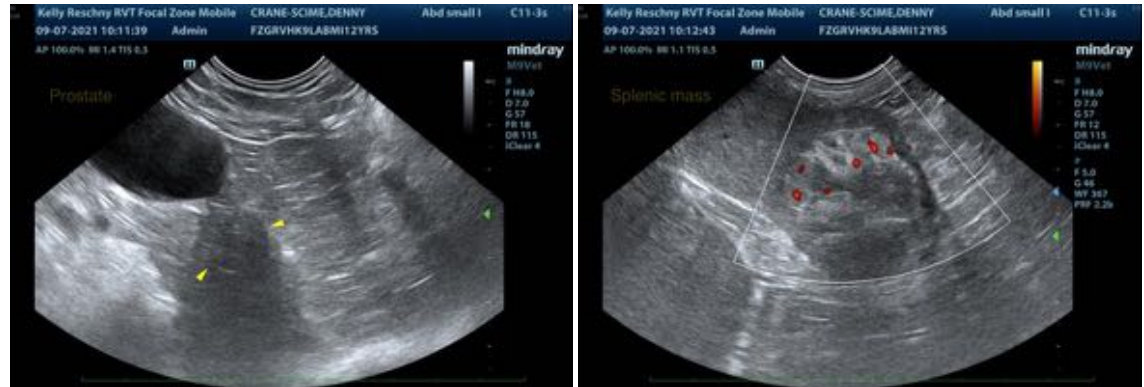Male Neutered

AGE

12 Years

WEIGHT

30 kgs.



INTERPRETED BY

Andrea Nicastro, DVM,
Diplomate ACVIM
(Small Animal Internal
Medicine)

**IMAGING
PERFORMED BY**

Kelly Reshny, RVT

HOSPITAL NAME

Grand River VH

REFERRING VET

Dr. Robinson

**INVOICE
12028**

**DATE
9/7/21**

The information and recommendations provided are based on the images presented by the referring veterinarian. No evaluation can be communicated regarding pathology that was not visible in the image/video clips provided.

Thank you for this referral. If the clinical or image interpretation does not parallel your findings or if I can be of any further assistance, please contact me.

Andrea Nicastro, DVM, Diplomate ACVIM (Small Animal Internal Medicine)
Andrea.nicastro@sonopath.com