


PATIENT

Bramble Chong

PRESENTING CLINICAL SIGNS

History: PUPD

SPECIES

Canine

Abnormal PE/Chem/CBC/UA Results: LDDST suggested of HAC, pre 52, 4 hour 101, 8 hour 51 UCCR 148

BREED

Basset Hound

ULTRASONOGRAPHIC EXAMINATION OF THE ABDOMEN
Urinary System

The urinary bladder, trigone, and pelvic urethra are normal in thickness and the mucosal surface is smooth. The bladder lumen is moderately distended with anechoic urine. No masses, inflammatory changes or calculi are observed. Ureteral papillae and visualized portion of the proximal urethra, visible to a depth of 2 cm, are normal.

SEX

Male Neutered

The prostate is normal in size (1.39 cm in width) and shape. Parenchyma is homogenous. The prostatic urethra appears normal without evidence of dilation or obstruction.

AGE

10 Years

The left kidney is normal size (7.47 cm in length); normal shape and architecture with smooth peripheral margins. There is a normal 1:3 cortex to medulla ratio with minimal to mild loss of corticomedullary distinction. There is no evidence of pyelectasia, nephroliths, infarcts or hydronephrosis. Renal vasculature is normal.

WEIGHT

59 lbs.

The right kidney is normal size (7.46 cm in length); normal shape and architecture with smooth peripheral margins. There is a normal 1:3 cortex to medulla ratio with minimal to mild loss of corticomedullary distinction. There is no evidence of pyelectasia, nephroliths, infarcts or hydronephrosis. Renal vasculature is normal.

INTERPRETED BY

 Andrea Nicastro, DVM,
 Diplomate ACVIM
 (*Small Animal Internal
 Medicine*)

Adrenal Glands

The left adrenal gland is mildly enlarged (0.93 cm at cranial pole) (0.92 cm at caudal pole) (2.74 cm in length); normal shape; homogenous parenchyma. The glandular echogenicity and detail are unremarkable. Capsule, cortex, and medullary definition are normal. The phrenicoabdominal vein and surrounding vasculature are normal.

IMAGING PERFORMED BY

Kelly Reshny, RVT

The right adrenal gland is enlarged (1.18 cm at cranial pole) (1.22 cm at caudal pole) (2.15 cm in length); normal shape; homogenous parenchyma. The glandular echogenicity and detail are unremarkable. Capsule, cortex, and medullary definition are normal. The phrenicoabdominal vein and surrounding vasculature are normal.

HOSPITAL NAME

Dundas AH

Spleen

The spleen is normal in size (1.97 cm in width at the level of the hilus) with a normal capsular contour. There is appropriate echogenicity and echotexture. No focal lesions are observed. Splenic vasculature is normal.

REFERRING VET

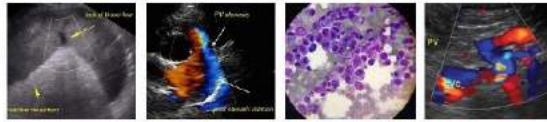
Dr. Foster

Liver

The liver is subjectively normal in size with normal curvilinear peripheral contours. The parenchyma is isoechoic relative to the spleen and exhibits mild heterogeneity. No distinct focal lesions are observed. Hepatic vasculature and biliary tracts are of normal volume with no evidence of congestion. The gall bladder lumen is moderately distended. The wall is thin and smooth. A small amount of adherent debris is observed within the lumen. The cystic and common bile ducts are normal/not seen.

INVOICE
 11912kk

DATE
 9/28/21



PATIENT

Gastrointestinal

Bramble Chong

The stomach and intestine are free of stasis and exhibit normal peristaltic activity. The gastric lumen is gas-distended. The gastric wall and pylorus are normal in thickness with a normal layering pattern. The pyloric outflow tract is patent. The small intestinal lumen is not dilated. The small intestinal wall thickness is normal with a normal layering pattern and appropriate mural detail. Discreet masses are not identified. The colonic wall is normal. No obstructive disease is noted.

SPECIES

Canine

Pancreas

BREED

Basset Hound

The region of the pancreas is isoechoic relative to surrounding omental fat. No obvious parenchymal abnormalities are observed. There is no evidence of regional inflammation or effusion.

Free Abdomen

SEX

Male Neutered

The peritoneal cavity is normal. There is no evidence of inflammation or effusion. The abdominal lymph nodes are normal/not visible.

ULTRASONOGRAPHIC FINDINGS

Primary Findings:

AGE

10 Years

- Bilateral adrenomegaly, consistent with pituitary-dependent, hyperadrenocorticism.
- The diffuse hepatic changes are non-specific and could be consistent with vacuolar hepatopathy, regenerative nodular hyperplasia, and/or age-related remodeling. Inflammatory and infiltrative disease are considered less likely.

WEIGHT

59 lbs.

Secondary Findings:

- Bilateral, age-related renal changes.

INTERPRETED BY

Andrea Nicastro, DVM,
Diplomate ACVIM
(Small Animal Internal
Medicine)

INTERPRETATION OF THE FINDINGS & FURTHER RECOMMENDATIONS

- If the clinical picture supports a diagnosis of Cushing's disease, including the baseline lab work, consider initiation of medical therapy (i.e., Trilostane).
- A baseline blood pressure measurement and UPC (if proteinuria is present) are also recommended.

IMAGING PERFORMED BY

Kelly Reshny, RVT

HOSPITAL NAME

Dundas AH

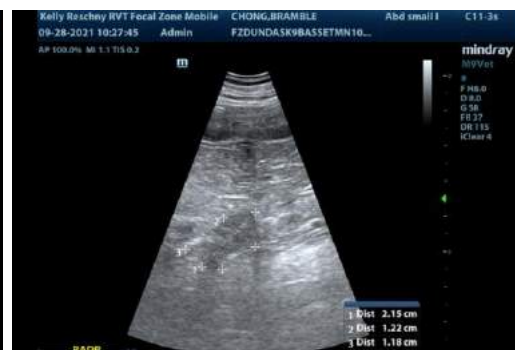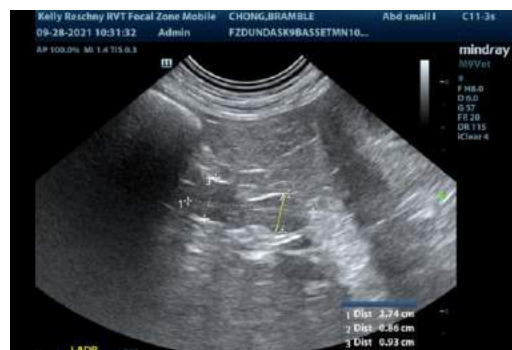REFERRING VET

Dr. Foster

INVOICE
11912kk

DATE

9/28/21





PATIENT

Bramble Chong

SPECIES

Canine

BREED

Basset Hound

SEX

Male Neutered

AGE

10 Years

WEIGHT

59 lbs.

INTERPRETED BY

Andrea Nicastro, DVM,
Diplomate ACVIM
(Small Animal Internal
Medicine)

**IMAGING
PERFORMED BY**

Kelly Reshny, RVT

HOSPITAL NAME

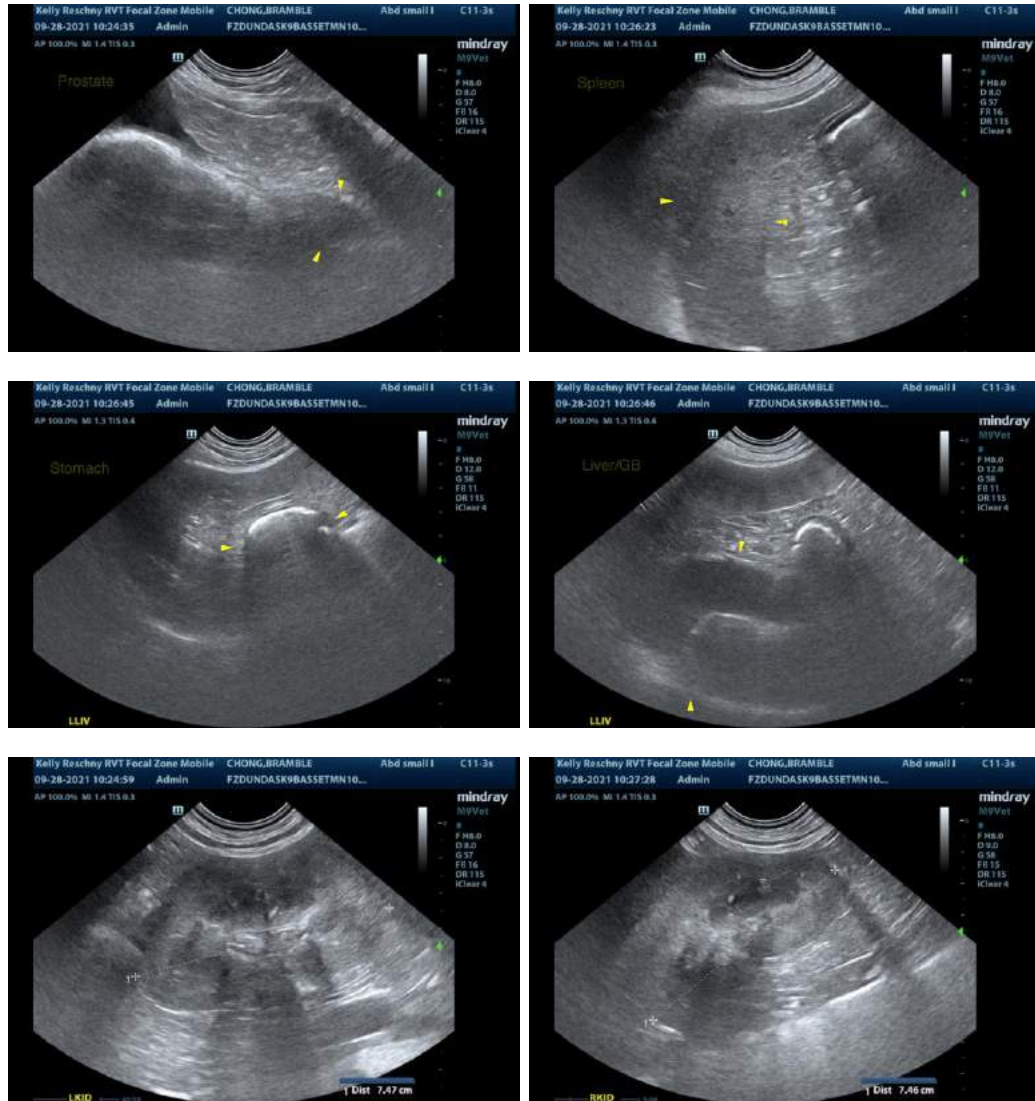
Dundas AH

REFERRING VET

Dr. Foster

INVOICE
11912kk

DATE
9/28/21



The information and recommendations provided are based on the images presented by the referring veterinarian. No evaluation can be communicated regarding pathology that was not visible in the image/video clips provided.

Thank you for this referral. If the clinical or image interpretation does not parallel your findings or if I can be of any further assistance, please contact me.

Andrea Nicastro, DVM, Diplomate ACVIM (Small Animal Internal Medicine)
Andrea.nicastro@sonopath.com