


PATIENT

Bella Fisher-Hastings

SPECIES

Canine

BREED

Havanese

SEX

Female Spayed

AGE

11 Years

WEIGHT

6.6 kgs.

INTERPRETED BY

 Andrea Nicastro, DVM,
 Diplomate ACVIM
 (*Small Animal Internal
 Medicine*)

**IMAGING
 PERFORMED BY**

Kelly Reshny, RVT

HOSPITAL NAME

Graham AH

REFERRING VET

Dr. Malatestinic

INVOICE

11812kk

DATE

9/14/21

PRESENTING CLINICAL SIGNS

History: Seen as dental appt 06/04/21 and on pre-op blood work found elevated liver parameters but NAF on exam including no HM -at post dental recheck 2 months later suddenly Grade 4/6 bilateral pan systolic HM present currently on Zentonil advanced. The patient is also having an echo performed today.

ULTRASONOGRAPHIC EXAMINATION OF THE ABDOMEN
Urinary System

The urinary bladder is mildly distended. The wall is of appropriate thickness for the level of repletion. A scant amount of echogenic debris is observed within the lumen. No cystic calculi are observed. The region of the trigone and the visible portion of the proximal urethra are normal.

The left kidney is normal size (4.67 cm in length); normal shape and architecture with smooth peripheral margins. There is a normal 1:3 cortex to medulla ratio with minimal loss of corticomedullary distinction. There is no evidence of pyelectasia, nephroliths, infarcts or hydroureter. Renal vasculature is normal.

The right kidney is normal size (4.52 cm in length); normal shape and architecture with smooth peripheral margins. There is a normal 1:3 cortex to medulla ratio with minimal loss of corticomedullary distinction. There is no evidence of pyelectasia, nephroliths, infarcts or hydroureter. Renal vasculature is normal.

Adrenal Glands

The left adrenal gland is mildly enlarged (0.66 cm at cranial pole) (0.71 cm at caudal pole) (2.47 cm in length) with a normal shape. A 1.09 x 0.39 cm ill-defined, hyperechoic nodule/area is observed at the cranial aspect. Glandular echogenicity and detail at the caudal aspect are normal. The phrenicoabdominal vein and surrounding vasculature are normal.

The right adrenal gland is mildly enlarged (0.92 cm at cranial pole) (0.66 cm at caudal pole) (1.92 cm in length); normal shape; homogenous parenchyma. The glandular echogenicity and detail are unremarkable. Capsule, cortex, and medullary definition are normal. The phrenicoabdominal vein and surrounding vasculature are normal.

Spleen

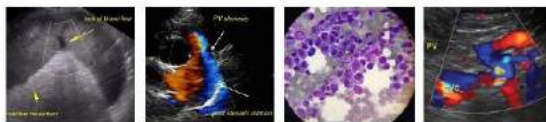
The spleen is normal in size (0.66 cm in width at the level of the hilus) with a normal capsular contour. There is appropriate echogenicity and echotexture. No focal lesions are observed. Splenic vasculature is normal.

Liver

The liver is subjectively prominent in size with swollen curvilinear peripheral contours. The parenchyma is isoechoic relative to the spleen and exhibits mild heterogeneity. No distinct focal lesions are observed. Hepatic vasculature and biliary tracts are of normal volume with no evidence of congestion. The gall bladder is moderately distended. The walls are normal in thickness. Aggregated, echogenic debris is adhered to the luminal wall circumferentially. The cystic and common bile ducts are normal/not seen.

Gastrointestinal

The stomach and intestine are free of stasis and exhibit normal peristaltic activity. The gastric lumen is mildly distended with ingesta. The gastric wall and pylorus are normal in thickness with a normal



PATIENT

Bella Fisher-Hastings

layering pattern. The pyloric outflow tract is patent. The small intestinal lumen is not dilated. The small intestinal wall thickness is normal with a normal layering pattern and appropriate mural detail. Discreet masses are not identified. The colonic wall is normal. No obstructive disease is noted.

SPECIES

Canine

Pancreas

The right limb of the pancreas is visible with normal curvilinear peripheral contours. The parenchyma is largely isoechoic relative to surrounding omental fat and slightly mottled in appearance. The pancreatic duct is visible but not overtly dilated. There is no evidence of peripancreatic inflammation or effusion.

BREED

Havanese

Free Abdomen

The peritoneal cavity is normal. There is no evidence of inflammation or effusion. The abdominal lymph nodes are normal/not visible.

SEX

Female Spayed

ULTRASONOGRAPHIC FINDINGS

Primary Findings:

AGE

11 Years

- The diffuse hepatic changes are non-specific and could be consistent with vacuolar hepatopathy, regenerative nodular hyperplasia, and/or age-related remodeling. Inflammatory and infiltrative disease are considered less likely. However, correlation with the patient's liver enzyme pattern is recommended.

WEIGHT

6.6 kgs.

- The gall bladder sludge pattern could be consistent with a developing mucocele or cholestasis.

Secondary Findings:

- Mild bilateral adrenomegaly with the left adrenal nodule could be consistent with nodular hyperplasia or less likely an early neoplastic process.
- Minor, age-related renal changes.

INTERPRETED BY

Andrea Nicastro, DVM,
Diplomate ACVIM
(Small Animal Internal
Medicine)

INTERPRETATION OF THE FINDINGS & FURTHER RECOMMENDATIONS

IMAGING PERFORMED BY

Kelly Reshny, RVT

- If the ALT is substantially elevated, further diagnostics (i.e., pre- and post-prandial serum bile acids, Leptospirosis testing, +/- hepatic tissue sampling) may be warranted. If the ALP is elevated with a normal or only slightly elevated ALT, consider serial monitoring of the patient's blood work (i.e., every 3-4 months) with possible repeat abdominal imaging if liver values progress.
- Consider initiation of Ursodiol therapy for the gall bladder changes. Alternatively, a repeat ultrasound of the gall bladder can be considered in 2-3 weeks, preferably two hours post meal (to allow for gall bladder contraction). If findings are similar to today's scan, Ursodiol therapy can be initiated at that time.
- Consider testing for hyperadrenocorticism with a low-dose dexamethasone suppression test or ACTH stimulation test if clinical signs (i.e., PU/PD) develop.
- Three-view thoracic radiographs are also recommended if not already performed to assess cardiopulmonary status.

HOSPITAL NAME

Graham AH

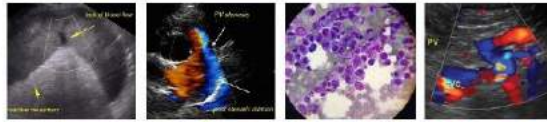
REFERRING VET

Dr. Malatestinic

INVOICE
11812kk

DATE

9/14/21



PATIENT

Bella Fisher-Hastings

SPECIES

Canine

BREED

Havanese

SEX

Female Spayed

AGE

11 Years

WEIGHT

6.6 kgs.

INTERPRETED BY

Andrea Nicastro, DVM,
Diplomate ACVIM
(Small Animal Internal
Medicine)

**IMAGING
PERFORMED BY**

Kelly Reshny, RVT

HOSPITAL NAME

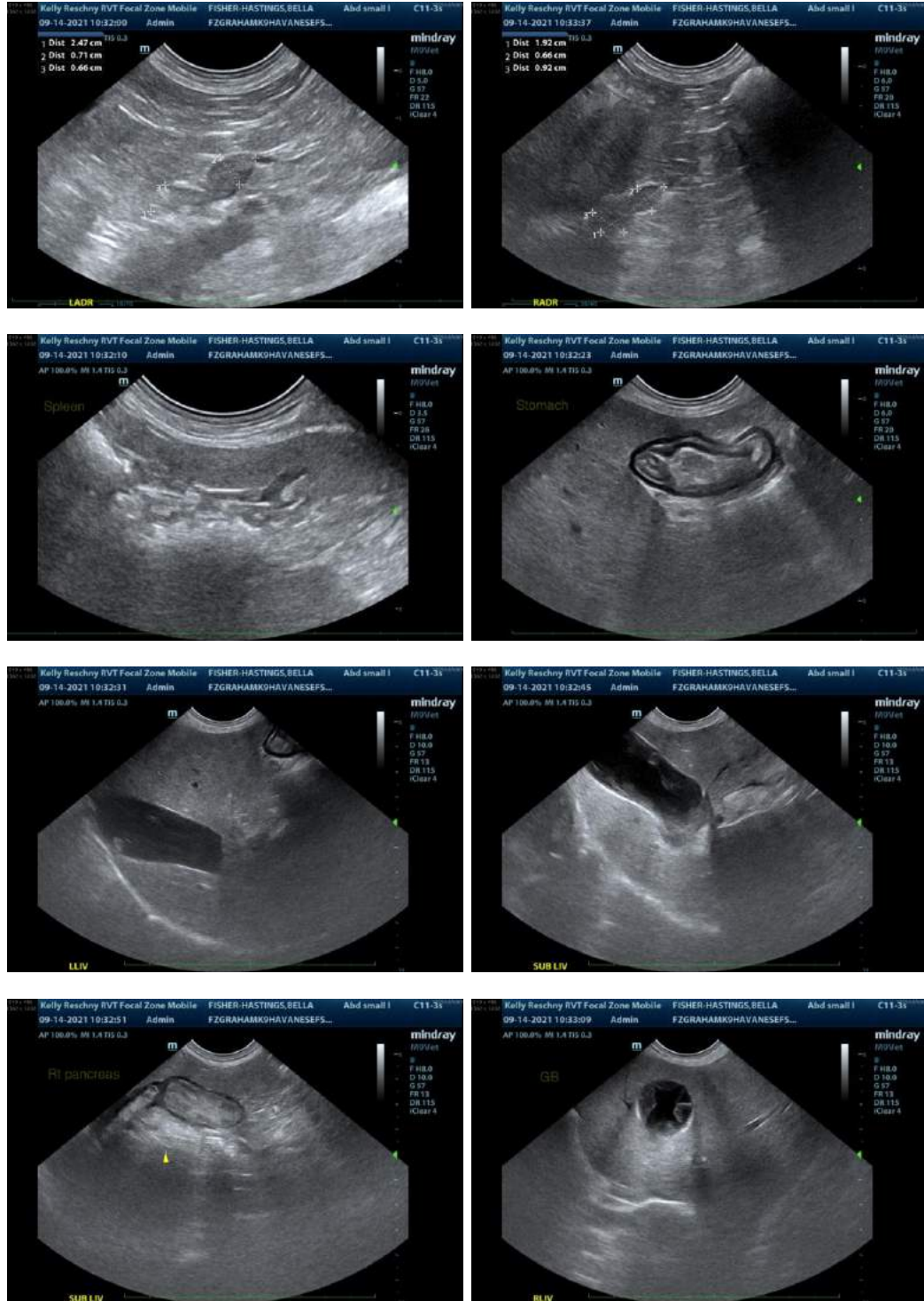
Graham AH

REFERRING VET

Dr. Malatestinic

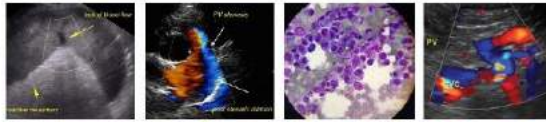
INVOICE
11812kk

DATE
9/14/21



The information and recommendations provided are based on the images presented by the referring veterinarian. No evaluation can be communicated regarding pathology that was not visible in the image/video clips provided.

Thank you for this referral. If the clinical or image interpretation does not parallel your findings or if I can be of any further assistance, please contact me.



PATIENT

Bella Fisher-Hastings

Andrea Nicastro, DVM, Diplomate ACVIM (*Small Animal Internal Medicine*)
Andrea.nicastro@sonopath.com

SPECIES

Canine

BREED

Havanese

SEX

Female Spayed

AGE

11 Years

WEIGHT

6.6 kgs.

INTERPRETED BY

Andrea Nicastro, DVM,
Diplomate ACVIM
(*Small Animal Internal
Medicine*)

**IMAGING
PERFORMED BY**

Kelly Reshny, RVT

HOSPITAL NAME

Graham AH

REFERRING VET

Dr. Malatestinic

INVOICE

11812kk

DATE

9/14/21