


**PATIENT PRESENTING CLINICAL SIGNS**

Rocky Rao History: concern for possible FB meds: pantoprazole 0.7mg/kg IV q24hrs, cerenia 1mg/kg IV q24hours

**SPECIES** Abnormal PE/Chem/CBC/UA Results: - mild increased neutrophilia, mild lymphopenia, mild eosinopenia - normal cPL rads: ABDOMEN: August 22, 2022: 4 images are provided. Images were acquired a different point in time.

Canine

**ULTRASONOGRAPHIC EXAMINATION OF THE ABDOMEN**
**BREED** *Urinary System*

Rottweiler The urinary bladder wall is normal in thickness and the mucosal surface is smooth. The bladder lumen is mildly to moderately distended. A small amount of suspended echogenic debris is observed within the lumen. No masses, inflammatory changes or calculi are observed. Ureteral papillae and visualized portion of the proximal urethra, visible to a depth of 2 cm, are normal.

**SEX**

Male, neutered

The prostate is normal in size (1.39 cm in width) and shape. Parenchyma is homogenous. The prostatic urethra appears normal without evidence of dilation or obstruction.

**AGE**

7 Yrs.

The left kidney is normal size (7.16 cm in length); normal shape and architecture with smooth peripheral margins. There is a normal 1:3 cortex to medulla ratio with minimal loss of corticomedullary distinction. There is no evidence of pyelectasia, nephroliths, infarcts or hydroureter. Renal vasculature is normal.

**WEIGHT**

35 kg.

The right kidney is normal size (7.22 cm in length); normal shape and architecture with smooth peripheral margins. There is a normal 1:3 cortex to medulla ratio with minimal loss of corticomedullary distinction. There is no evidence of pyelectasia, nephroliths, infarcts or hydroureter. Renal vasculature is normal.

**INTERPRETED BY**

Andrea Nicastro, DVM,  
 Diplomate ACVIM  
 (*Small Animal Internal  
 Medicine*)

**Adrenal Glands**

The left adrenal gland is normal size (0.57 cm at cranial pole) (0.56 cm at caudal pole) (2.84 cm in length); normal shape; homogenous parenchyma. The glandular echogenicity and detail are unremarkable. Capsule, cortex, and medullary definition are normal. The phrenicoabdominal vein and surrounding vasculature are normal.

**IMAGING PERFORMED BY**

Kelly Reschny

The right adrenal gland is normal size (1.96 cm at cranial pole) (0.40 cm at caudal pole) (2.31 cm in length); normal shape; homogenous parenchyma. The glandular echogenicity and detail are unremarkable. Capsule, cortex, and medullary definition are normal. The phrenicoabdominal vein and surrounding vasculature are normal.

**HOSPITAL NAME**

Hamilton Region  
 Veterinary Emergency  
 Clinic

**Spleen**

The spleen is normal in size (2.64 cm in width at the level of the hilus) with a normal capsular contour. The parenchyma is subtly mottled in appearance. A 2.44 x 2.22 cm hypoechoic to slightly heterogeneous, slightly cavitated mass is observed approximately mid-spleen. In addition, a 0.82 cm hypoechoic nodule is observed at the cranial aspect. Splenic vasculature is normal.

**REFERRING VET**

Dr. Vercaigne

**Liver**

The liver is subjectively normal in size with normal contours and structure. The parenchyma is hypoechoic relative to the spleen with minor changes consistent with age-related remodeling. There is an increase in portal markings. No distinct focal lesions are observed. Vascular is of normal volume with no evidence of thrombosis. The gall bladder lumen is moderately distended. The wall is thin and smooth. Luminal contents are anechoic. The cystic and common bile ducts are normal/not seen.

**DATE**  
 13868


**PATIENT** *Gastrointestinal*

Rocky Rao The gastric lumen is not distended. The gastric wall is normal in thickness with a normal layering pattern. The small intestinal lumen is not dilated. The small intestinal wall thickness is normal with a normal layering pattern and appropriate mural detail. Discreet masses are not identified. The colonic wall is normal. No obstructive disease is noted.

**SPECIES**

Canine

*Pancreas*

The region of the pancreas is isoechoic relative to surrounding omental fat. No obvious parenchymal abnormalities are observed. There is no evidence of regional inflammation or effusion.

**BREED**

Rottweiler

*Free Abdomen*
**SEX**

Male, neutered

The peritoneal cavity is normal. There is no evidence of inflammation or effusion. The abdominal lymph nodes are normal/not visible.

*Other*
**AGE**

7 Yrs.

A brief echocardiogram reveals no evidence of pericardial effusion or obvious right atrial/auricular mass.

**WEIGHT**

35 kg.

**ULTRASONOGRAPHIC FINDINGS**
**Primary Findings:**

- Splenic mass. Neoplasia (i.e., sarcoma, round cell tumor) is of primary concern. However, a benign process (i.e., focus of lymphoid hyperplasia, extramedullary hematopoiesis or similar) cannot be completely excluded.
- The diffuse splenic parenchymal changes trend more toward the benign (i.e., extramedullary hematopoiesis or lymphoid hyperplasia). However, infiltrative neoplasias is also possible.

**Secondary Findings:**

- The increase in hepatic portal markings is suggestive of an inflammatory hepatopathy. However, correlation with the patient's liver values is recommended.

\*There is no obvious evidence of a GI foreign body/obstruction. A partial obstruction cannot be completely excluded but is conserved unlikely.

**INTERPRETED BY**

Andrea Nicastro, DVM,  
 Diplomate ACVIM  
 (*Small Animal Internal  
 Medicine*)

**IMAGING  
 PERFORMED BY**

Kelly Reschny

**HOSPITAL NAME**

Hamilton Region  
 Veterinary Emergency  
 Clinic

**REFERRING VET**

Drd. Vercaigne

**INTERPRETATION OF THE FINDINGS & FURTHER RECOMMENDATIONS**

- Given the splenic mass, three-view thoracic radiographs are recommended to assess for pulmonary metastatic disease. A fine needle aspirate of the splenic mass can be considered if clotting status is appropriate. However, there is some risk of iatrogenic hemorrhage associated with aspiration. If pursued, the patient should be monitored sonographically for at least 5-10 minutes post procedure to assess for bleeding. Alternatively, a splenectomy with submission of the spleen for histopathology can be considered. If surgery is pursued, a liver biopsy should also be obtained to assess for micrometastatic disease.
- If the patient continues to exhibit gastrointestinal signs, a more advanced GI workup may be warranted.

**DATE**  
 13868



**PATIENT**

Rocky Rao

**SPECIES**

Canine

**BREED**

Rottweiler

**SEX**

Male, neutered

**AGE**

7 Yrs.

**WEIGHT**

35 kg.

**INTERPRETED BY**

Andrea Nicastrò, DVM,  
Diplomate ACVIM  
(Small Animal Internal  
Medicine)

**IMAGING  
PERFORMED BY**

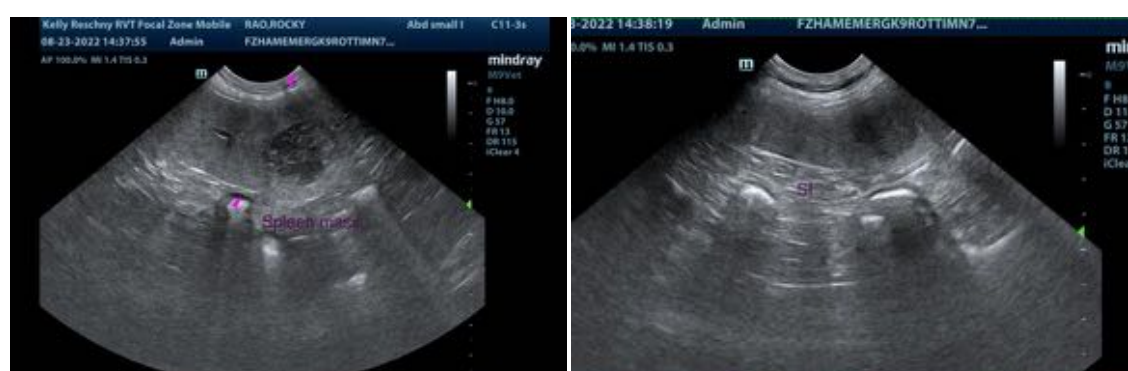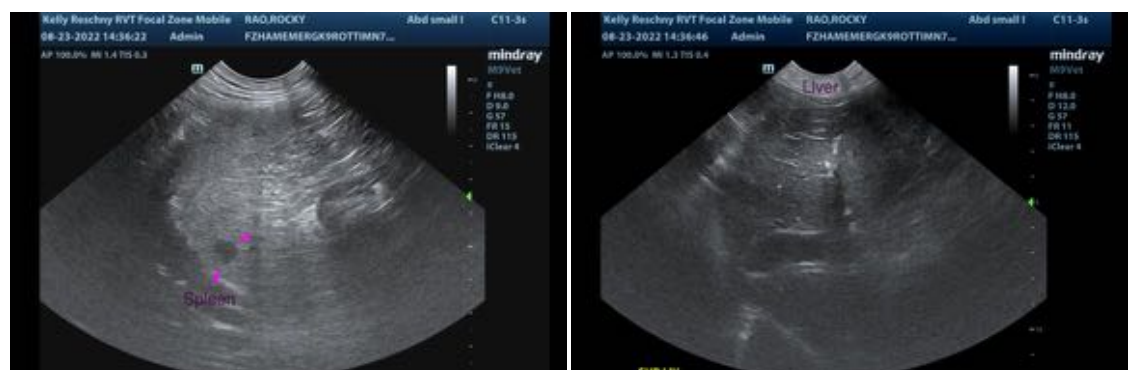
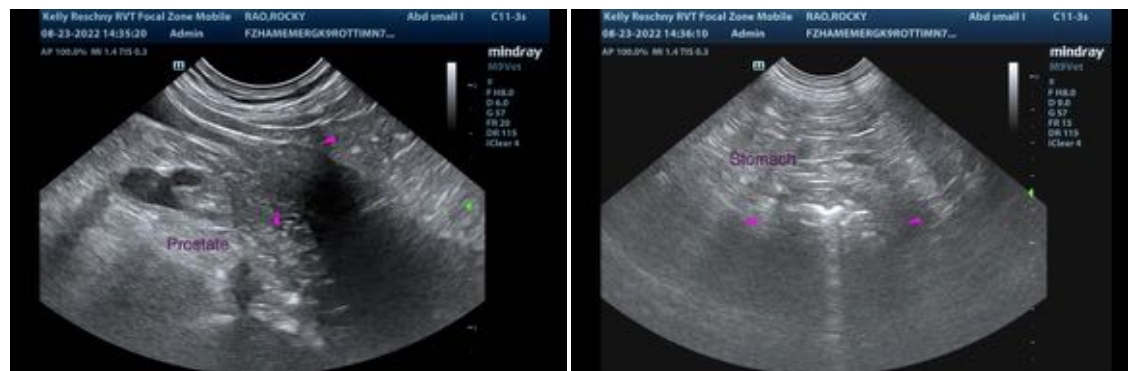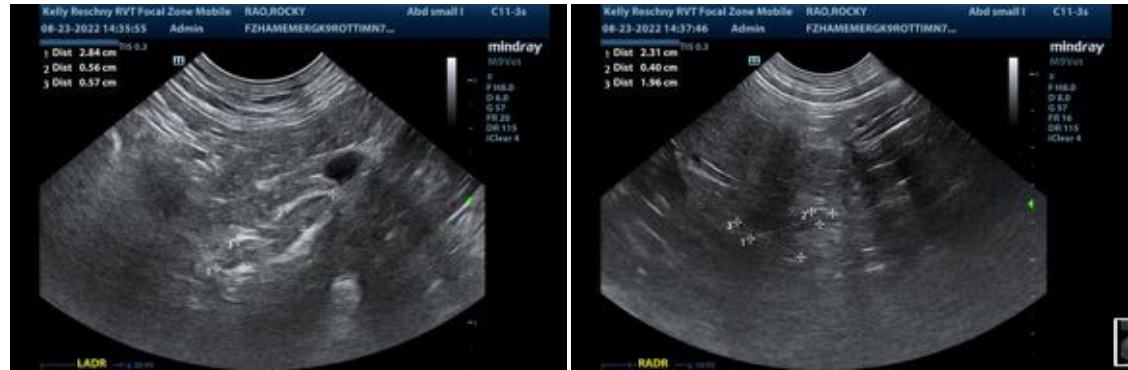Kelly Reschny

**HOSPITAL NAME**

Hamilton Region  
Veterinary Emergency  
Clinic

**REFERRING VET**

Drd. Vercaigne



The information and recommendations provided are based on the images presented by the referring veterinarian/sonographer. No evaluation can be communicated regarding pathology that was not visible

**DATE**  
13868



**PATIENT** in the image/video clips provided.

Rocky Rao Thank you for this referral. If the clinical or image interpretation does not parallel your findings or if I can be of any further assistance please contact me.

**SPECIES**

Canine

Andrea Nicastro, MPH, DVM, Diplomate DACVIM (Small Animal Internal Medicine)  
[info@SonoPath.com](mailto:info@SonoPath.com)

**BREED**

Rottweiler

**SEX**

Male, neutered

**AGE**

7 Yrs.

**WEIGHT**

35 kg.

**INTERPRETED BY**

Andrea Nicastro, DVM,  
Diplomate ACVIM  
(*Small Animal Internal  
Medicine*)

**IMAGING  
PERFORMED BY**

Kelly Reschny

**HOSPITAL NAME**

Hamilton Region  
Veterinary Emergency  
Clinic

**REFERRING VET**

Drd. Vercaigne

**DATE**  
13868