


PATIENT PRESENTING CLINICAL SIGNS

Molly Correia History: Ultrasound performed by focal zone April 2021 - following up 1 year later - benign hepatopathy noted at that time has several fatty lumps meds: omeprazole, zentoni, sulcrate, cytopoint
 Abnormal PE/Chem/CBC/UA Results: ALP has come back into normal range, ALT continues to be elevated

SPECIES

Canine

ULTRASONOGRAPHIC EXAMINATION OF THE ABDOMEN
Urinary System

The urinary bladder is moderately distended. The wall is normal in thickness with a smooth mucosal surface. A small amount of aggregated mineralized debris +/- tiny calculi is observed within the lumen. The region of the trigone and the visible portion of the proximal urethra are normal.

SEX

Female, spayed

The left kidney is normal size (4.50 cm in length); normal shape and architecture with smooth peripheral margins. There is a normal 1:3 cortex to medulla ratio with mild to moderate loss of corticomedullary distinction. There is no evidence of pyelectasia, nephroliths, infarcts or hydronephrosis. Renal vasculature is normal.

AGE

10 Yrs.

The right kidney is normal size (4.46 cm in length); normal shape and architecture with smooth peripheral margins. There is a normal 1:3 cortex to medulla ratio with mild to moderate loss of corticomedullary distinction. There is no evidence of pyelectasia, nephroliths, infarcts or hydronephrosis. Renal vasculature is normal.

WEIGHT

8.35 kg.

Adrenal Glands

The left adrenal gland is normal size (0.47 cm at cranial pole) (0.49 cm at caudal pole) (1.73 cm in length); normal shape; homogenous parenchyma. The glandular echogenicity and detail are unremarkable. Capsule, cortex, and medullary definition are normal. The phrenicoabdominal vein and surrounding vasculature are normal.

The right adrenal gland is mildly enlarged (1.00 cm at cranial pole) (0.68 cm at caudal pole) (1.71 cm in length); normal shape; homogenous parenchyma. The glandular echogenicity and detail are unremarkable. Capsule, cortex, and medullary definition are normal. The phrenicoabdominal vein and surrounding vasculature are normal.

INTERPRETED BY

Andrea Nicastro, DVM,
 Diplomate ACVIM
 (Small Animal Internal
 Medicine)

IMAGING PERFORMED BY

Kelly Reshny, RVT

Spleen

The spleen is normal in size (1.22 cm in width at the level of the hilus) with a normal capsular contour. There is appropriate echogenicity and echotexture. No focal lesions are observed. Splenic vasculature is normal.

HOSPITAL NAME

Oxford Co VC

Liver

The liver is subjectively prominent in size with swollen curvilinear peripheral contours. The parenchyma is isoechoic relative to the spleen and exhibits mild heterogeneity. No distinct focal lesions are observed. Hepatic vasculature and biliary tracts are of normal volume with no evidence of congestion. The gall bladder lumen is moderately distended. The wall is thin and smooth. Luminal contents are anechoic. The cystic and common bile ducts are normal/not seen.

REFERRING VET

Dr. Halfon

Gastrointestinal

The gastric lumen is mildly distended with ingesta and gas. The gastric wall is normal in thickness with a normal layering pattern. The small intestinal lumen is segmentally dilated with chyme. The small

DATE

5/2/22



PATIENT

Molly Correia

intestinal wall thickness is normal with a normal layering pattern and appropriate mural detail. Discreet masses are not identified. The colonic wall is normal. No obstructive disease is noted.

Pancreas

SPECIES

Canine

The region of the pancreas is isoechoic relative to surrounding omental fat. No obvious parenchymal abnormalities are observed. There is no evidence of regional inflammation or effusion.

BREED

Mini Schnauzer

Free Abdomen

The peritoneal cavity is normal. There is no evidence of inflammation or effusion. The abdominal lymph nodes are normal/not visible.

SEX

Female, spayed

ULTRASONOGRAPHIC FINDINGS

Primary Findings:

- Non-specific diffuse hepatopathy. Given the elevated ALT, top differentials include inflammatory disease (i.e., chronic active hepatitis, bacterial cholangiohepatitis), copper hepatotoxicosis +/- concurrent age-related change (i.e., vacuolar hepatopathy, regenerative nodular hyperplasia). Neoplasia is possible but considered less likely in this patient. Leptospirosis is also possible but less likely due to the chronicity of liver enzyme elevations.

AGE

10 Yrs.

Secondary Findings:

- Bilateral, non-specific age-related renal changes.
- Mineralized urinary bladder debris +/- tiny calculi.
- Mild right adrenomegaly.

WEIGHT

8.35 kg.

INTERPRETED BY

Andrea Nicastro, DVM,
Diplomate ACVIM
(*Small Animal Internal
Medicine*)

INTERPRETATION OF THE FINDINGS & FURTHER RECOMMENDATIONS

- Hepatic tissue sampling (i.e., fine needle aspirate or surgical biopsy) can be considered. Surgical biopsies are more likely to yield a definitive diagnosis. If pursued, aerobic and anaerobic bile cultures and acquisition of additional hepatic tissue samples for potential copper quantitation are recommended.
- Pre and post prandial serum bile acids can also be considered to assess hepatic function.
- Prior to anesthesia, thoracic radiographs should be performed to assess cardiopulmonary status.
- Leptospirosis testing can also be considered. However, given the chronicity of the liver enzyme elevations, this differential is considered less likely and testing may be of low yield.

IMAGING PERFORMED BY

Kelly Reshny, RVT

HOSPITAL NAME

Oxford Co VC

REFERRING VET

Dr. Halfon

DATE

5/2/22



PATIENT

Molly Correia

SPECIES

Canine

BREED

Mini Schnauzer

SEX

Female, spayed

AGE

10 Yrs.

WEIGHT

8.35 kg.

INTERPRETED BY

Andrea Nicastro, DVM,
Diplomate ACVIM
(*Small Animal Internal
Medicine*)

**IMAGING
PERFORMED BY**

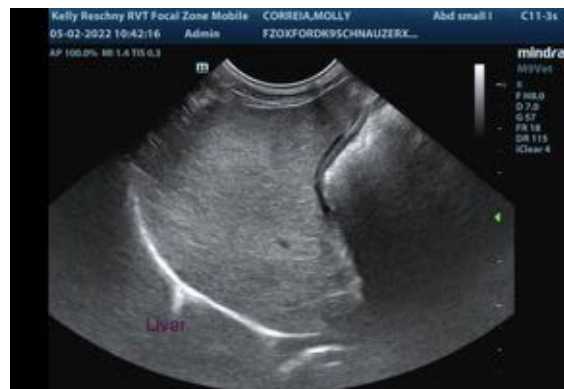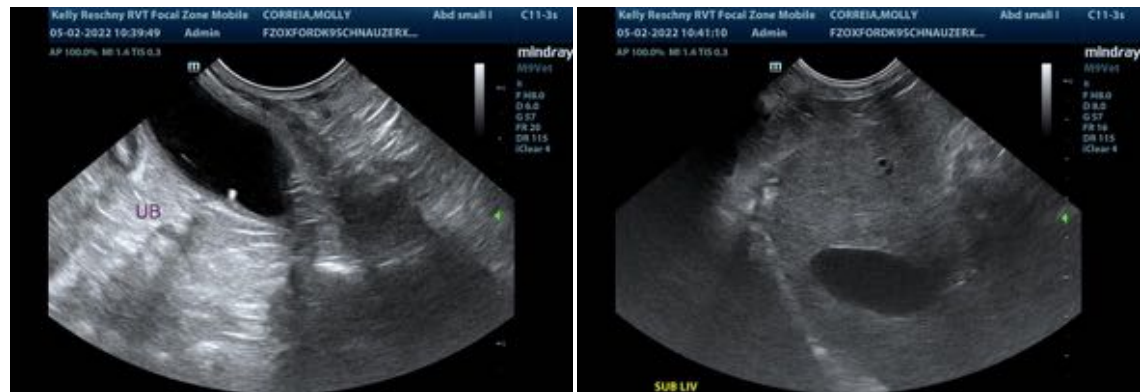
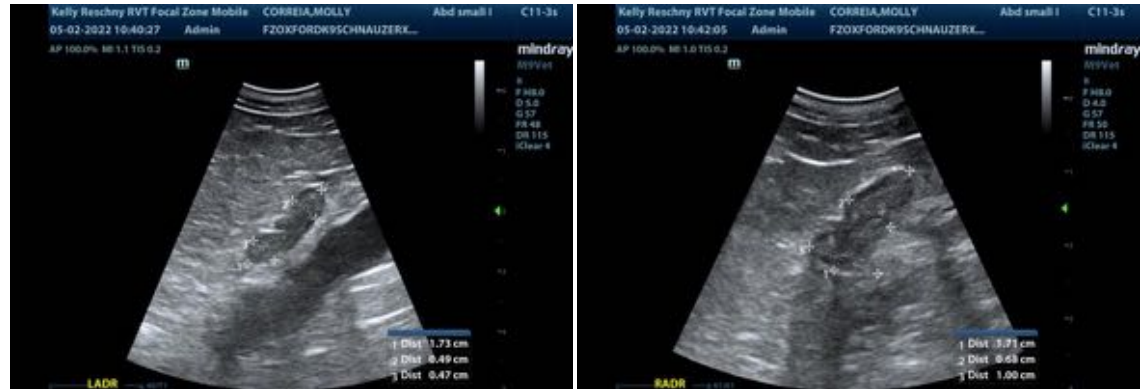Kelly Reshny, RVT

HOSPITAL NAME

Oxford Co VC

REFERRING VET

Dr. Halfon



The information and recommendations provided are based on the images presented by the referring veterinarian/sonographer. No evaluation can be communicated regarding pathology that was not visible in the image/video clips provided.

Thank you for this referral. If the clinical or image interpretation does not parallel your findings or if I can be of any further assistance please contact me.

Andrea Nicastro, DVM, Diplomate ACVIM (*Small Animal Internal Medicine*)

Andrea.nicastro@sonopath.com

DATE
5/2/22