
**PATIENT PRESENTING CLINICAL SIGNS**

Sarah Rosehart History: weight loss, elevated liver values  
 Abnormal PE/Chem/CBC/UA Results: CBC shows thrombocytosis and a monocytosis. Chemistry shows elevated SDMA and BUN. Albumin low, ALKP 2159, ALT 1233, total bili 12.2.

**SPECIES**

Canine

**ULTRASONOGRAPHIC EXAMINATION OF THE ABDOMEN**
*Urinary System*
**BREED**

Pug

The urinary bladder, trigone, and pelvic urethra are normal in thickness and the mucosal surface is smooth. The bladder lumen is moderately distended. A small amount of suspended echogenic debris is observed within the lumen. No masses, inflammatory changes or calculi are observed. Ureteral papillae and visualized portion of the proximal urethra, visible to a depth of 2 cm, are normal.

**SEX**

Female, spayed

The left kidney is normal size (5.36 cm in length); normal shape and architecture with smooth peripheral margins. The cortex is diffusely thickened and hyperechoic and there is moderate loss of corticomedullary distinction. Hyperechoic shadowing diverticular foci are visualized. Moderate to severe pyelectasia is present (0.80 cm in the longitudinal plane). There is no evidence of infarcts or hydroureter. Renal vasculature is normal.

**AGE**

13 Yrs.

The right kidney is normal size (5.75 cm in length); normal shape and architecture with smooth peripheral margins. The cortex is diffusely thickened and hyperechoic and there is moderate loss of corticomedullary distinction. Hyperechoic shadowing diverticular foci are visualized. Moderate to severe pyelectasia is present (1.01 cm in the longitudinal plane). There is no evidence of infarcts or hydroureter. Renal vasculature is normal.

**WEIGHT**

13 lbs.

*Adrenal Glands*
**INTERPRETED BY**

Andrea Nicastro, DVM,  
 Diplomate ACVIM  
 (*Small Animal Internal  
 Medicine*)

The left adrenal gland is enlarged (1.27 cm at cranial pole) (0.43cm at caudal pole) (2.42 cm in length) with an irregular shape and a prominent cranial pole. A 1.54 x 1.21 cm hyperechoic to heterogeneous nodule is observed at the cranial aspect. Hyperechoic foci are observed within the nodule. The glandular echogenicity and detail in the caudal aspect are unremarkable. The phrenicoabdominal vein and surrounding vasculature are normal.

**IMAGING PERFORMED BY**

Kelly Reshny, RVT

The right adrenal gland is mildly enlarged (0.77 cm at cranial pole) (0.58 cm at caudal pole) (2.64 cm in length) with a slightly irregular shape. A 1.19 x 0.56 cm hyperechoic nodule is observed at the cranial aspect. The glandular echogenicity and detail at the caudal aspect are unremarkable. The phrenicoabdominal vein and surrounding vasculature are normal.

**HOSPITAL NAME**

Stoney Ridge AH

*Spleen*

The spleen is normal in size (1.50 cm in width at the level of the hilus) with a normal capsular contour. There is appropriate echogenicity and echotexture. Numerous pinpoint hyperechoic foci are observed throughout the organ. Splenic vasculature is normal.

**REFERRING VET**

Dr. Brooks

*Liver*

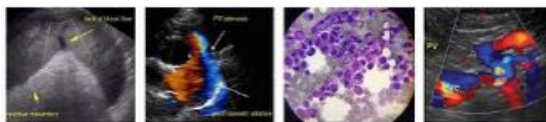
The liver is subjectively normal in size with normal curvilinear peripheral contours. The parenchyma is hypoechoic relative to the spleen and mottled in appearance. A 0.72 cm anechoic cyst is observed on the left side. Vascular and biliary tracts are of normal volume with no evidence of congestion. The gall bladder lumen is moderately distended. The wall is normal in thickness. A few small polypoid like lesions are arising from the luminal surface. A scant amount of echogenic debris is adhered to the wall. The cystic and common bile ducts are normal/not seen.

**INVOICE**

12389

**DATE**

10/19/21


**PATIENT**
***Gastrointestinal***

Sarah Rosehart

The stomach and intestine are free of stasis and exhibit normal peristaltic activity. The gastric lumen is not distended. The gastric wall and pylorus are normal in thickness with a normal layering pattern. The pyloric outflow tract is patent. The small intestinal lumen is not dilated. The small intestinal wall thickness is normal with a normal layering pattern and appropriate mural detail. Discreet masses are not identified. The colonic wall is normal. No obstructive disease is noted.

**SPECIES**

Canine

***Pancreas***
**BREED**

Pug

The region of the pancreas is isoechoic relative to surrounding omental fat. No obvious parenchymal abnormalities are observed. There is no evidence of regional inflammation or effusion.

**SEX**

Female, spayed

***Free Abdomen***

Trace free fluid is observed. The abdominal lymph nodes are normal/not visible.

**AGE**

13 Yrs.

**ULTRASONOGRAPHIC FINDINGS**
**Primary Findings:**

- Non-specific diffuse hepatopathy. Differentials include inflammatory/immune mediated disease (i.e., bacterial cholangiohepatitis, chronic active hepatitis), hepatotoxicosis (i.e., copper), Leptospirosis, infiltrative neoplasia (less likely), other hepatopathy.
- The trace ascites is likely secondary to underlying hepatic disease and hypoalbuminemia.

**WEIGHT**

13 lbs.

**Secondary Findings:**

- Urinary bladder debris.
- The bilateral renal changes are consistent with chronic interstitial nephrosis/nephritis. The pyelectasia may be secondary to pyelonephritis and/or age-related remodeling.
- The bilateral adrenal changes are most consistent with nodular hyperplasia with a lower possibility of emerging neoplasia.
- Splenic dystrophic mineralization.

**INTERPRETED BY**

 Andrea Nicastro, DVM,  
 Diplomate ACVIM  
 (*Small Animal Internal  
 Medicine*)

**IMAGING  
 PERFORMED BY**

Kelly Reshny, RVT

**HOSPITAL NAME**

Stoney Ridge AH

**INTERPRETATION OF THE FINDINGS & FURTHER RECOMMENDATIONS**

- Leptospirosis testing (i.e., blood and urine PCR, serology) is recommended.
- Cytologic evaluation of the liver should be considered in this patient if clotting status is appropriate. A fine needle aspirate using a 25-gauge needle is recommended. If cytologic evaluation is inconclusive, consider a surgical liver biopsy with aerobic and anaerobic bile cultures and acquisition of additional hepatic tissue samples for copper quantitation.
- If a conservative approach is desired, consider empirical treatment for bacterial cholangiohepatitis (amoxicillin-clavulanic acid, Denamarin Advanced). If no improvement in the liver values is seen within 7-10 days of initiating therapy, antibiotics should be discontinued and hepatic tissue sampling reconsidered. If liver values improve, continue therapy for at least 4-6 weeks and 1 week beyond normalization of the liver values.

**REFERRING VET**

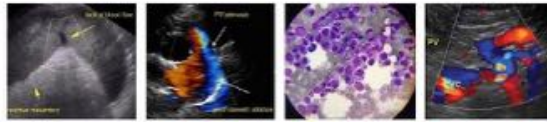
Dr. Brooks

**INVOICE**

12389

**DATE**

10/19/21



**PATIENT**

Sarah Rosehart

- Three-view thoracic radiographs are recommended to assess cardiopulmonary status, particularly given the patient's age.

**SPECIES**

Canine

**BREED**

Pug

**SEX**

Female, spayed

**AGE**

13 Yrs.

**WEIGHT**

13 lbs.

**INTERPRETED BY**

Andrea Nicaastro, DVM,  
Diplomate ACVIM  
(Small Animal Internal  
Medicine)

**IMAGING PERFORMED BY**

Kelly Reshny, RVT

**HOSPITAL NAME**

Stoney Ridge AH

**REFERRING VET**

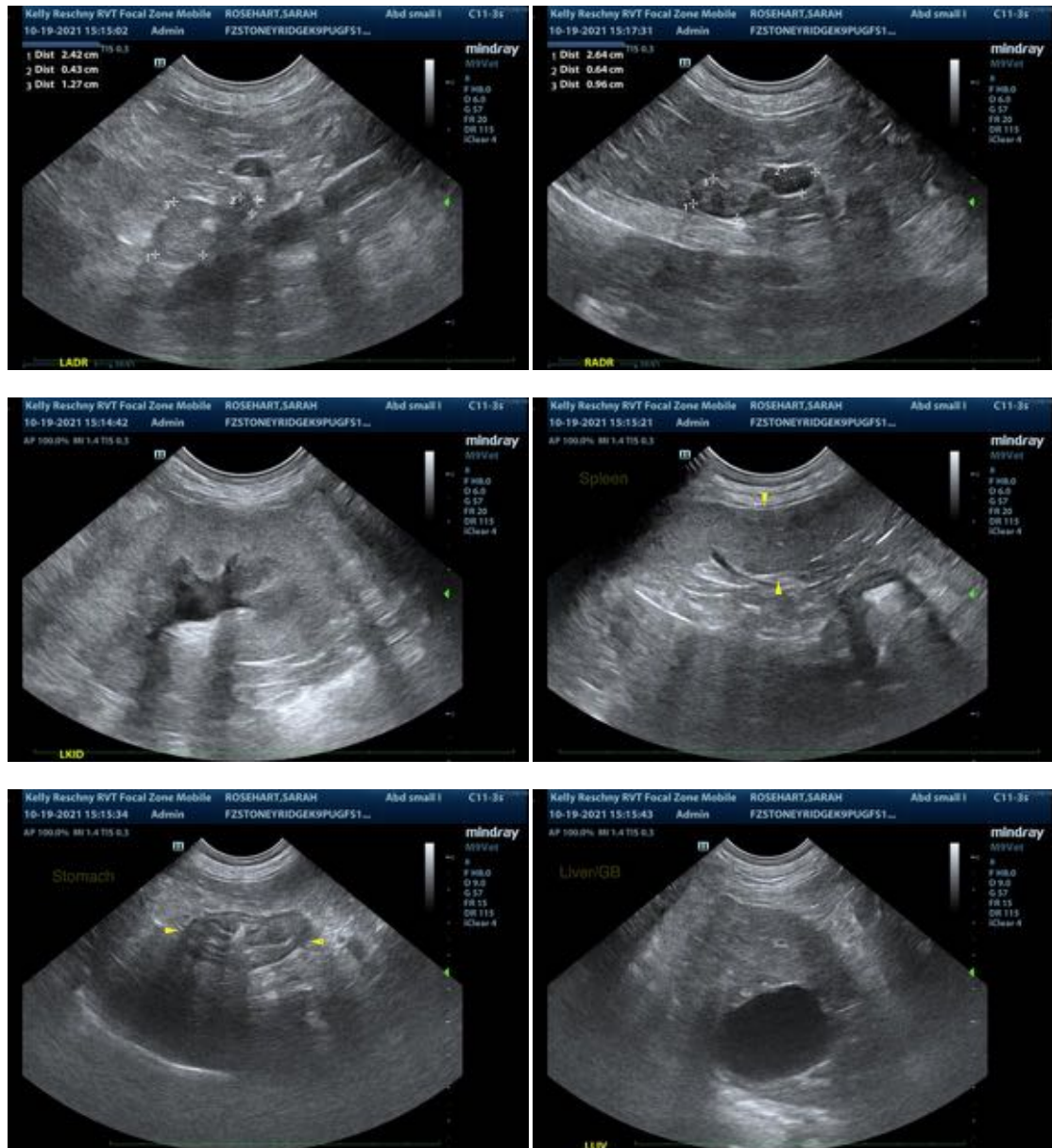
Dr. Brooks

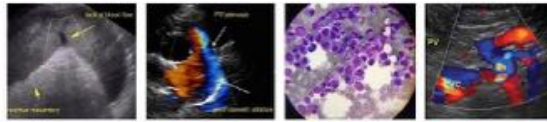
**INVOICE**

12389

**DATE**

10/19/21





**PATIENT**

Sarah Rosehart

**SPECIES**

Canine

**BREED**

Pug

**SEX**

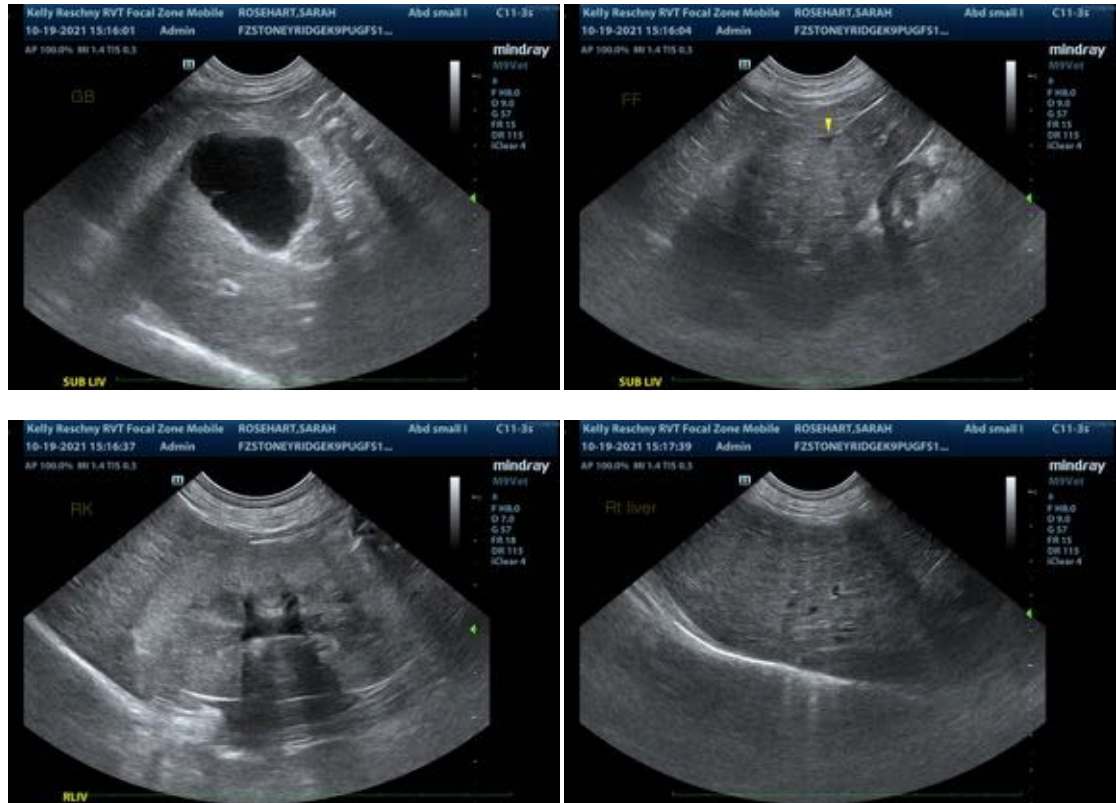
Female, spayed

**AGE**

13 Yrs.

**WEIGHT**

13 lbs.



**INTERPRETED BY**

Andrea Nicastro, DVM,  
Diplomate ACVIM  
(Small Animal Internal  
Medicine)

**IMAGING  
PERFORMED BY**

Kelly Reshny, RVT

**HOSPITAL NAME**

Stoney Ridge AH

**REFERRING VET**

Dr. Brooks

**INVOICE**

12389

**DATE**

10/19/21

The information and recommendations provided are based on the images presented by the referring veterinarian. No evaluation can be communicated regarding pathology that was not visible in the image/video clips provided.

Thank you for this referral. If the clinical or image interpretation does not parallel your findings or if I can be of any further assistance please contact me.

Andrea Nicastro, DVM, Diplomate ACVIM (Small Animal Internal Medicine)

Andrea.nicastro@sonopath.com