


PATIENT

Pepper McLeod

SPECIES

Canine

BREED

Austrian shepherd mix

SEX

Male, neutered

AGE

14 Yrs.

WEIGHT

19.8 kg.

INTERPRETED BY

 Andrea Nicastro, DVM,
 Diplomate ACVIM
 (*Small Animal Internal
 Medicine*)

**IMAGING
 PERFORMED BY**

Kelly Reshny, RVT

HOSPITAL NAME

Oxford County VC

REFERRING VET

Dr. Andratis

INVOICE

12337

DATE

10/12/21

PRESENTING CLINICAL SIGNS

History: On routine wellness in September of 2019 and the AlkP and Alt were elevated. They have been monitored over the last 2 years and continue to climb. Bile Acids were done Sept 2020 and were normal. The volume of water being drank is within normal limits. Diagnosed with Urinary Incontinence in Oct 2020 and is on Proin.

Abnormal PE/Chem/CBC/UA Results: current bloodwork: AlkP 1345, Alt 143

ULTRASONOGRAPHIC EXAMINATION OF THE ABDOMEN
Urinary System

The urinary bladder, trigone, and pelvic urethra are normal in thickness and the mucosal surface is smooth. The bladder lumen is moderately distended with mostly anechoic urine. No masses, inflammatory changes or calculi are observed. Ureteral papillae and visualized portion of the proximal urethra, visible to a depth of 2 cm, are normal.

The prostate is not definitively visualized due to its pelvic location.

The left kidney is normal size (5.47 cm in length); normal shape and architecture with smooth peripheral margins. There is a normal 1:3 cortex to medulla ratio with minimal loss of corticomedullary distinction. There is no evidence of pyelectasia, nephroliths, infarcts or hydroureter. Renal vasculature is normal.

The right kidney is normal size (6.66 cm in length); normal shape and architecture with smooth peripheral margins. There is a normal 1:3 cortex to medulla ratio with minimal loss of corticomedullary distinction. There is no evidence of pyelectasia, nephroliths, infarcts or hydroureter. Renal vasculature is normal.

Adrenal Glands

The left adrenal gland is normal size (0.56 cm at cranial pole) (0.58 cm at caudal pole) (2.36 cm in length); normal shape; homogenous parenchyma. The glandular echogenicity and detail are unremarkable. Capsule, cortex, and medullary definition are normal. The phrenicoabdominal vein and surrounding vasculature are normal.

The right adrenal gland is normal size (1.30 cm at cranial pole) (0.47 cm at caudal pole) (2.42 cm in length); normal shape; homogenous parenchyma. The glandular echogenicity and detail are unremarkable. Capsule, cortex, and medullary definition are normal. The phrenicoabdominal vein and surrounding vasculature are normal.

Spleen

The spleen is normal in size (1.24 cm in width at the level of the hilus) with a normal capsular contour. There is appropriate echogenicity and echotexture. A few small ill-defined myelolipomas are observed in the region of the hilus. Splenic vasculature is normal.

Liver

The liver is subjectively prominent in size with swollen curvilinear peripheral contours. The parenchyma is isoechoic relative to the spleen and exhibits mild heterogeneity. No distinct focal lesions are observed. Hepatic vasculature and biliary tracts are of normal volume with no evidence of congestion. The gallbladder is of normal contours and contains some dependent echogenic debris. The wall is normal in thickness. No choleliths are observed. The cystic and common bile ducts are normal.



PATIENT

Pepper McLeod

SPECIES

Canine

BREED

Austrian shepherd mix

SEX

Male, neutered

AGE

14 Yrs.

WEIGHT

19.8 kg.

INTERPRETED BY

Andrea Nicastro, DVM,
Diplomate ACVIM
(*Small Animal Internal
Medicine*)

**IMAGING
PERFORMED BY**

Kelly Reshny, RVT

HOSPITAL NAME

Oxford County VC

REFERRING VET

Dr. Andratis

INVOICE

12337

DATE

10/12/21

Gastrointestinal

The stomach and intestine are free of stasis and exhibit normal peristaltic activity. The gastric lumen is mildly distended with ingesta. The gastric wall and pylorus are normal in thickness with a normal layering pattern. The pyloric outflow tract is patent. The small intestinal lumen is not dilated. The small intestinal wall thickness is normal with a normal layering pattern and appropriate mural detail. Discreet masses are not identified. The colonic wall is normal. No obstructive disease is noted.

Pancreas

The region of the pancreas is isoechoic relative to surrounding omental fat. No obvious parenchymal abnormalities are observed. There is no evidence of regional inflammation or effusion.

Free Abdomen

The peritoneal cavity is normal. There is no evidence of inflammation or effusion. The abdominal lymph nodes are normal/not visible.

ULTRASONOGRAPHIC FINDINGS

Primary Findings:

- The diffuse hepatic changes are non-specific and could be consistent with vacuolar hepatopathy, regenerative nodular hyperplasia, and/or age-related remodeling. Inflammatory and infiltrative disease are considered less likely.
- Gallbladder debris, non-mucocele.

Secondary Findings:

- Minor age-related renal pathology.

INTERPRETATION OF THE FINDINGS & FURTHER RECOMMENDATIONS

- Serial monitoring (i.e., every 3-4 months) of the patient's liver values is recommended. If values continue to increase, a repeat abdominal ultrasound +/- hepatic tissue sampling may be warranted.
- Consider testing for hyperadrenocorticism with a low-dose dexamethasone suppression test or ACTH stimulation test if clinical signs (i.e., PU/PD) develop in the future.



PATIENT

Pepper McLeod

SPECIES

Canine

BREED

Austrian shepherd mix

SEX

Male, neutered

AGE

14 Yrs.

WEIGHT

19.8 kg.

INTERPRETED BY

Andrea Nicaastro, DVM,
Diplomate ACVIM
(Small Animal Internal
Medicine)

**IMAGING
PERFORMED BY**

Kelly Reshny, RVT

HOSPITAL NAME

Oxford County VC

REFERRING VET

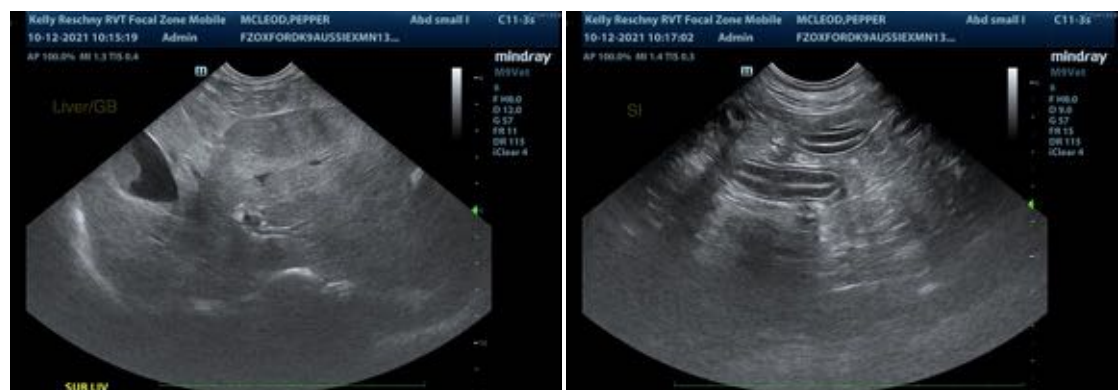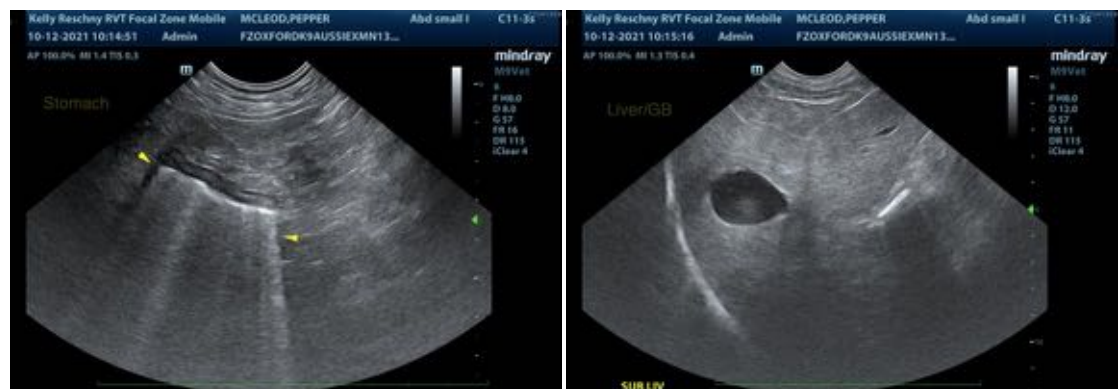
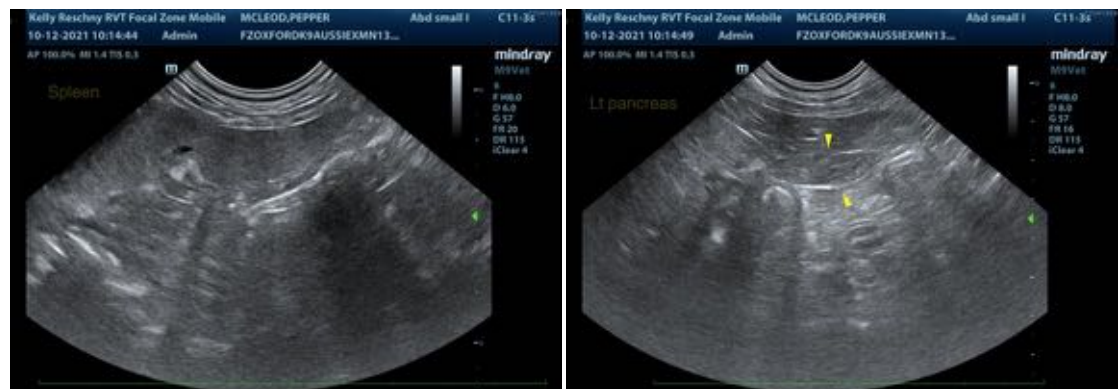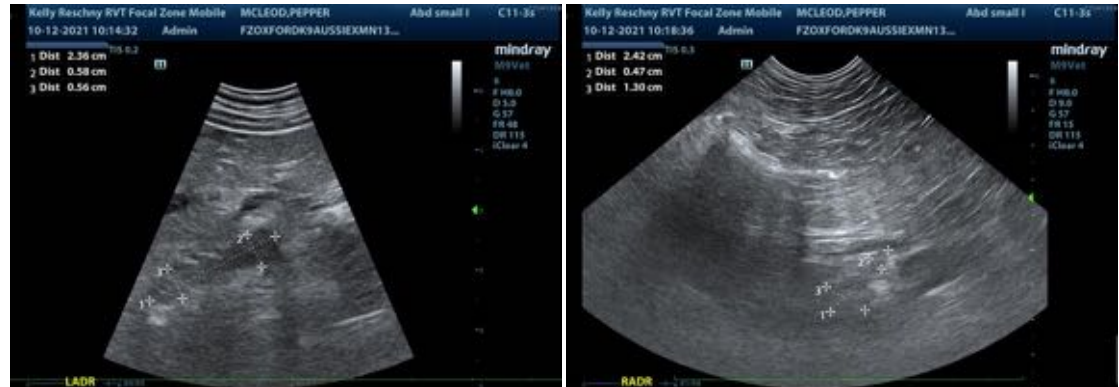Dr. Andratis

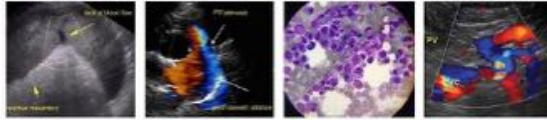
INVOICE

12337

DATE

10/12/21





PATIENT

Pepper McLeod

The information and recommendations provided are based on the images presented by the referring veterinarian. No evaluation can be communicated regarding pathology that was not visible in the image/video clips provided.

SPECIES

Canine

Thank you for this referral. If the clinical or image interpretation does not parallel your findings or if I can be of any further assistance please contact me.

BREED

Andrea Nicastro, DVM, Diplomate ACVIM (*Small Animal Internal Medicine*)

Andrea.nicastro@sonopath.com

Austrialn shepherd mix

SEX

Male, neutered

AGE

14 Yrs.

WEIGHT

19.8 kg.

INTERPRETED BY

Andrea Nicastro, DVM,
Diplomate ACVIM
(*Small Animal Internal
Medicine*)

**IMAGING
PERFORMED BY**

Kelly Reshny, RVT

HOSPITAL NAME

Oxford County VC

REFERRING VET

Dr. Andratis

INVOICE

12337

DATE

10/12/21