



**PATIENT**

Bailey Wilson

**SPECIES**

Canine

**BREED**

Golden Retriever

**SEX**

Male, neutered

**AGE**

6/2/17

**WEIGHT**

89.5 lbs.

**INTERPRETED BY**

Andrea Nicastro, DVM,  
Diplomate ACVIM  
(Small Animal Internal  
Medicine)

**IMAGING  
PERFORMED BY**

Andrea Nicastro, DVM,  
Diplomate ACVIM  
(Small Animal Internal  
Medicine)

**HOSPITAL NAME**

Meadowlawn Loris

**REFERRING VET**

Dr. Graham

**INVOICE**

13590

**DATE**

6/3/26

**PRESENTING CLINICAL SIGNS**

Pt is asymptomatic. This is just a general abdominal screen due to the patient's age.

**ULTRASONOGRAPHIC EXAMINATION OF THE ABDOMEN**

**Urinary System**

The urinary bladder wall is normal in thickness and the mucosal surface is smooth. The bladder is moderately distended. Luminal contents are anechoic. No cystic calculi are observed. The region of the trigone and the proximal urethra, visible to a depth of 5 cm, are normal.

The prostate is normal in size (0.86 cm in width) and shape. Parenchyma is homogenous. The prostatic urethra appears normal without evidence of dilation or obstruction.

The left kidney is normal in size (7.66 cm in length) with a normal shape, architecture and smooth peripheral margins. There is a normal 1:3 cortex to medulla ratio with minimal to mild loss of corticomedullary distinction. There is no evidence of pyelectasia, nephroliths, infarcts or hydroureter. Renal vasculature is normal.

The right kidney is normal in size (7.69 cm in length) with a normal shape, architecture and smooth peripheral margins. There is a normal 1:3 cortex to medulla ratio with minimal to mild loss of corticomedullary distinction. There is no evidence of pyelectasia, nephroliths, infarcts or hydroureter. Renal vasculature is normal.

**Adrenal Glands**

The left adrenal gland is normal in size (0.57 cm at cranial pole) (0.60 cm at caudal pole) with a normal shape and homogenous parenchyma. The glandular echogenicity and detail are unremarkable. Capsule, cortex, and medullary definition are normal. The phrenicoabdominal vein and surrounding vasculature are normal.

The right adrenal gland is normal in size (0.60 cm at cranial pole) (0.53 cm at caudal pole) with a normal shape and homogenous parenchyma. The glandular echogenicity and detail are unremarkable. Capsule, cortex, and medullary definition are normal. The phrenicoabdominal vein and surrounding vasculature are normal.

**Spleen**

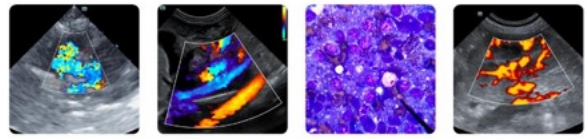
The spleen is normal in size (2.26 cm in width at the level of the hilus) with a normal capsular contour. There is appropriate echogenicity and echotexture. A 1.21 x 0.85 cm hypoechoic nodule is observed at the medial aspect approximately mid-body. Splenic vasculature is normal.

**Liver**

The liver is subjectively normal in size with normal contours and structure. There is appropriate echogenicity and echotexture. No overt structural evidence of inflammatory, infiltrative, or regenerative pathology is evident. Vascular and biliary tracts are of normal volume with no evidence of congestion. The portal vein to caudal vena cava ratio is approximately 1:1.

The gall bladder lumen is moderately distended. The wall is thin and smooth. A small amount of aggregated, echogenic, mostly gravity-dependent debris/sludge is observed within the lumen. The cystic and common bile ducts are normal/not seen.

**Gastrointestinal**



**PATIENT**

Bailey Wilson

**SPECIES**

Canine

**BREED**

Golden Retriever

**SEX**

Male, neutered

**AGE**

6/2/17

**WEIGHT**

89.5 lbs.

**INTERPRETED BY**

Andrea Nicastro, DVM,  
 Diplomate ACVIM  
 (Small Animal Internal  
 Medicine)

**IMAGING PERFORMED BY**

Andrea Nicastro, DVM,  
 Diplomate ACVIM  
 (Small Animal Internal  
 Medicine)

**HOSPITAL NAME**

Meadowlawn Loris

**REFERRING VET**

Dr. Graham

**INVOICE**

13590

**DATE**

6/3/26

The gastric lumen is not distended. The gastric wall and pylorus are normal in thickness with a normal layering pattern. The pyloric outflow tract is patent. The small intestinal lumen is not dilated. The small intestinal wall is normal in thickness with a normal layering pattern and appropriate mural detail. Discreet masses are not identified. The ileocecolic junction and colonic wall are normal. There is no evidence of an obstructive pattern.

**Pancreas**

The region of the pancreas is isoechoic relative to surrounding omental fat. No obvious parenchymal abnormalities are observed. There is no evidence of regional inflammation or effusion.

**Lymph nodes**

The abdominal lymph nodes are normal/not visible.

**Free Abdomen**

The peritoneal cavity is normal. There is no evidence of inflammation or effusion.

**Other**

A brief echocardiogram reveals no evidence of pericardial effusion or obvious right atrial/auricular mass.

**ULTRASONOGRAPHIC FINDINGS**

**Primary Findings:**

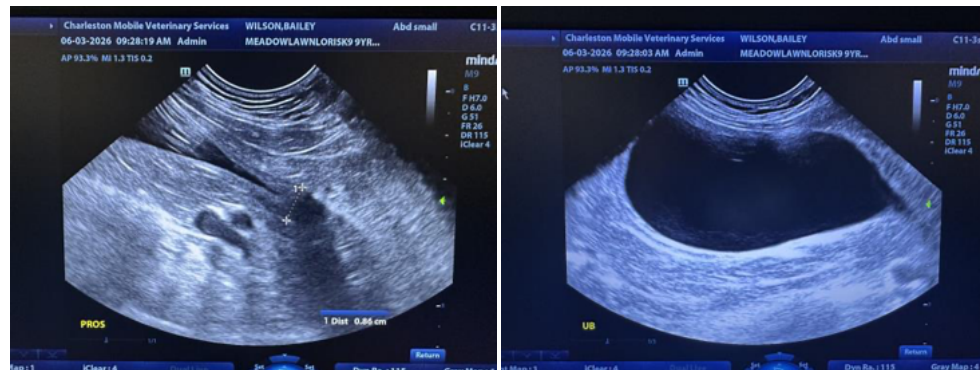
- The splenic nodule trends toward the benign (i.e., focus of lymphoid hyperplasia or similar). However, an emerging tumor cannot be completely excluded.

**Secondary Findings:**

- Mild bilateral nonspecific, age-related renal changes

**INTERPRETATION OF THE FINDINGS & FURTHER RECOMMENDATIONS**

Due to the location of the splenic nodule, aspiration would be difficult. Therefore, consider a recheck ultrasound in 2 months to assess for growth of the lesion.





**PATIENT**

Bailey Wilson

**SPECIES**

Canine

**BREED**

Golden Retriever

**SEX**

Male, neutered

**AGE**

6/2/17

**WEIGHT**

89.5 lbs.

**INTERPRETED BY**

Andrea Nicastro, DVM,  
 Diplomate ACVIM  
 (Small Animal Internal  
 Medicine)

**IMAGING PERFORMED BY**

Andrea Nicastro, DVM,  
 Diplomate ACVIM  
 (Small Animal Internal  
 Medicine)

**HOSPITAL NAME**

Meadowlawn Loris

**REFERRING VET**

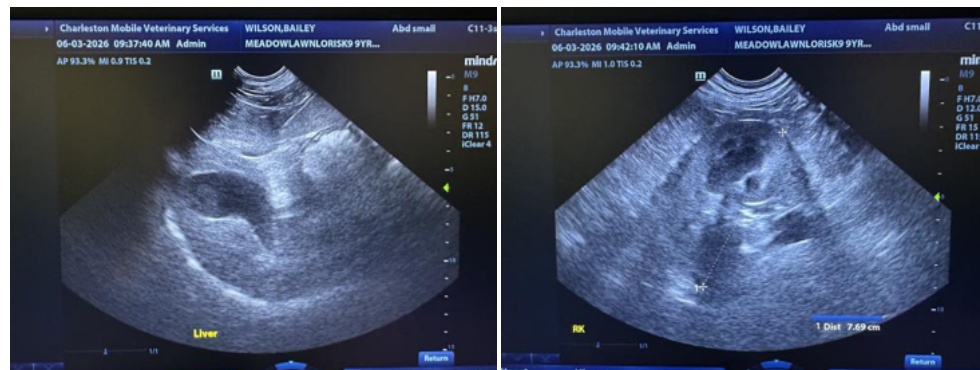
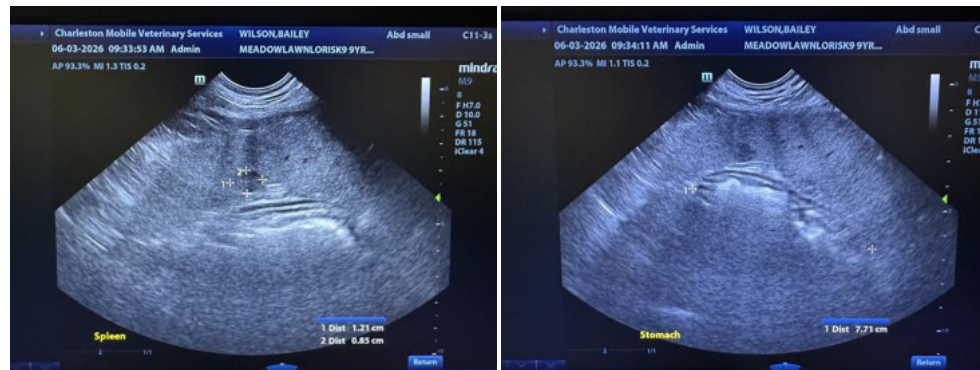
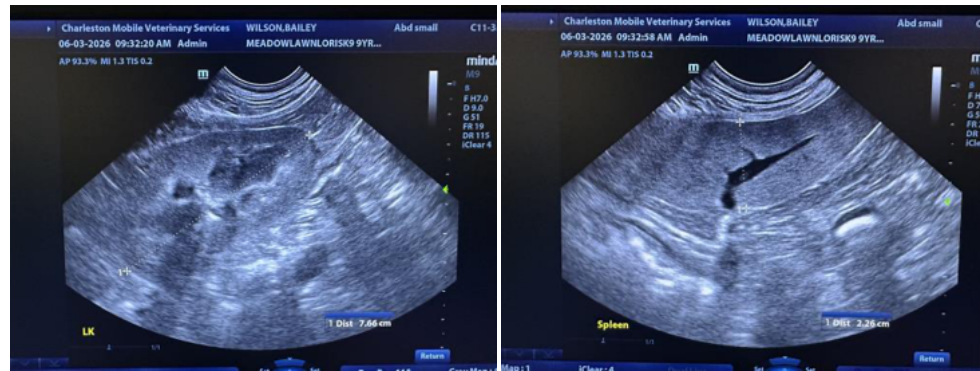
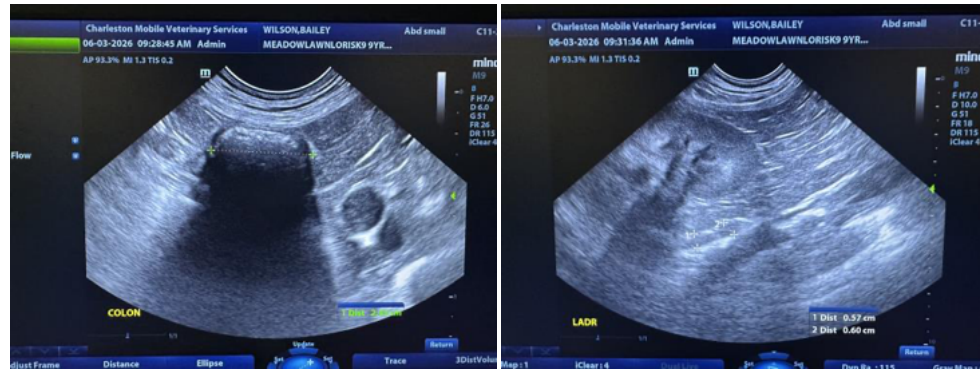
Dr. Graham

**INVOICE**

13590

**DATE**

6/3/26





**PATIENT**

Bailey Wilson

**SPECIES**

Canine

**BREED**

Golden Retriever

**SEX**

Male, neutered

**AGE**

6/2/17

**WEIGHT**

89.5 lbs.

**INTERPRETED BY**

Andrea Nicastro, DVM,  
 Diplomate ACVIM  
 (Small Animal Internal  
 Medicine)

**IMAGING  
 PERFORMED BY**

Andrea Nicastro, DVM,  
 Diplomate ACVIM  
 (Small Animal Internal  
 Medicine)

**HOSPITAL NAME**

Meadowlawn Loris

**REFERRING VET**

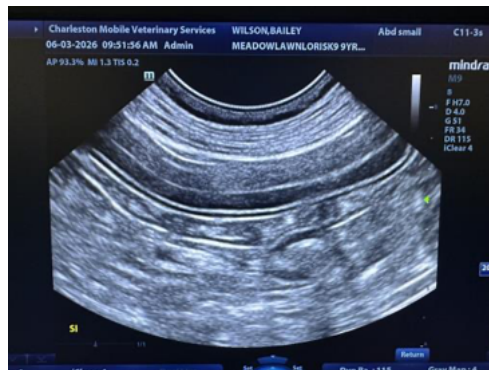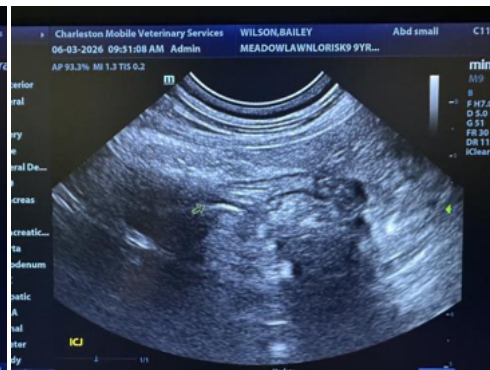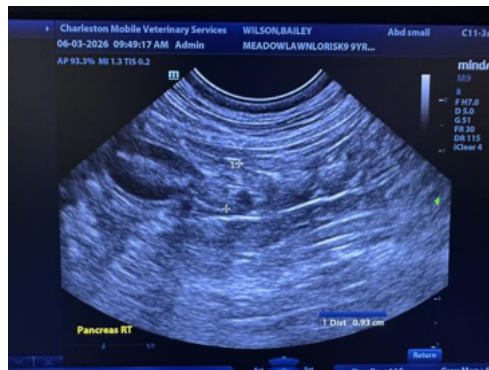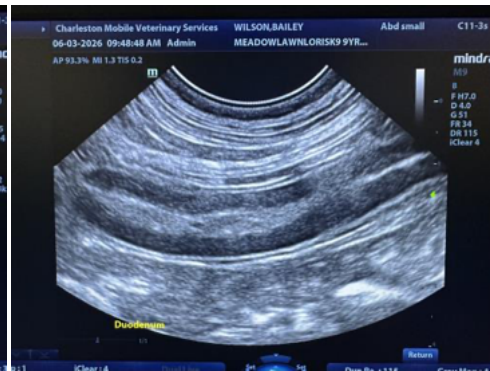
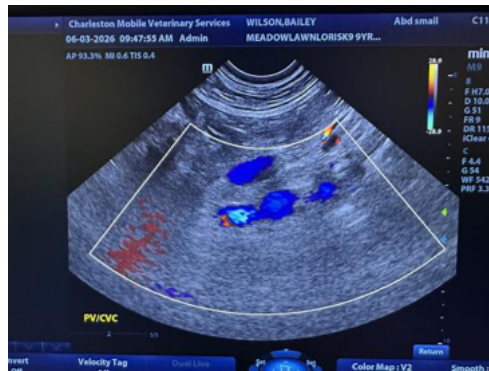
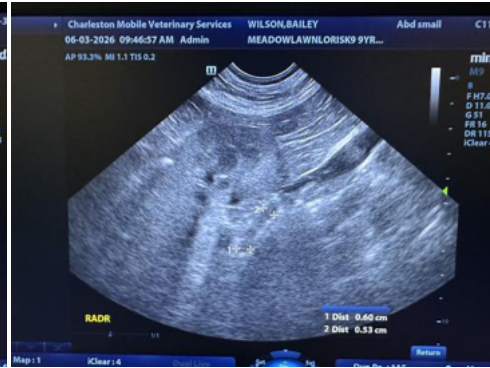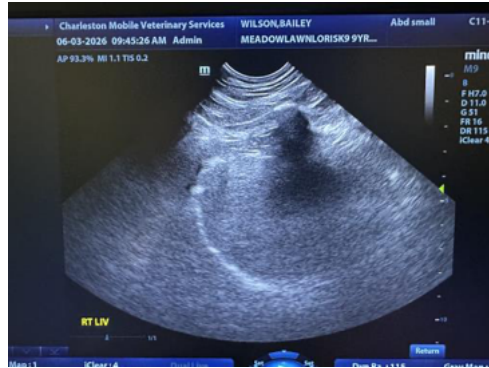
Dr. Graham

**INVOICE**

13590

**DATE**

6/3/26





**PATIENT**

Bailey Wilson

**SPECIES**

Canine

**BREED**

Golden Retriever

**SEX**

Male, neutered

**AGE**

6/2/17

**WEIGHT**

89.5 lbs.

**INTERPRETED BY**

Andrea Nicastro, DVM,  
Diplomate ACVIM  
*(Small Animal Internal  
Medicine)*

**IMAGING  
PERFORMED BY**

Andrea Nicastro, DVM,  
Diplomate ACVIM  
*(Small Animal Internal  
Medicine)*

**HOSPITAL NAME**

Meadowlawn Lorris

**REFERRING VET**

Dr. Graham

**INVOICE**

13590

**DATE**

6/3/26

The information and recommendations provided are based on the images presented by the referring veterinarian/sonographer. No evaluation can be communicated regarding pathology that was not visible in the image/video clips provided.

Thank you for this referral. If the clinical or image interpretation does not parallel your findings or if I can be of any further assistance please contact me.

Andrea Nicastro, MPH, DVM, Diplomate DACVIM (Small Animal Internal Medicine)  
[info@SonoPath.com](mailto:info@SonoPath.com)