



**PATIENT**

Pink Silveria

**SPECIES**

Canine

**BREED**

Siberian Husky

**SEX**

Female, spayed

**AGE**

10.5 Yrs.

**WEIGHT**

**INTERPRETED BY**

Andrea Nicastro, DVM,  
Diplomate ACVIM  
(Small Animal Internal  
Medicine)

**IMAGING  
PERFORMED BY**

Andrea Nicastro, DVM,  
Diplomate ACVIM  
(Small Animal Internal  
Medicine)

**HOSPITAL NAME**

Palmetto VH

**REFERRING VET**

Dr. Sivakoff

**INVOICE**

13732

**DATE**

5/19/26

**PRESENTING CLINICAL SIGNS**

Pt has had a chronically elevated ALT in the 200-300 range for the last several months. Pt is asymptomatic.

**ULTRASONOGRAPHIC EXAMINATION OF THE ABDOMEN**

**Urinary System**

The urinary bladder wall is normal in thickness and the mucosal surface is smooth. The bladder is moderately distended. Luminal contents are anechoic. No cystic calculi are observed. The region of the trigone and the proximal urethra, visible to a depth of 2 cm, are normal.

The left kidney is normal in size (6.01 cm in length) with a normal shape, architecture and smooth peripheral margins. There is a normal 1:3 cortex to medulla ratio with minimal to mild loss of corticomedullary distinction. There is no evidence of pyelectasia, nephroliths, infarcts or hydroureter. Renal vasculature is normal.

The right kidney is normal in size (6.87 cm in length) with a normal shape, architecture and smooth peripheral margins. There is a normal 1:3 cortex to medulla ratio with minimal to mild loss of corticomedullary distinction. There is no evidence of pyelectasia, nephroliths, infarcts or hydroureter. Renal vasculature is normal.

**Adrenal Glands**

The left adrenal gland is normal in size (0.59 cm at cranial pole) (0.44 cm at caudal pole) with a normal shape and homogenous parenchyma. The glandular echogenicity and detail are unremarkable. Capsule, cortex, and medullary definition are normal. The phrenicoabdominal vein and surrounding vasculature are normal.

The right adrenal gland is normal in size (1.02 cm at cranial pole) (0.58 cm at caudal pole) with a normal shape and homogenous parenchyma. The glandular echogenicity and detail are unremarkable. Capsule, cortex, and medullary definition are normal. The phrenicoabdominal vein and surrounding vasculature are normal.

**Spleen**

The spleen is normal in size (2.14 cm in width at the level of the hilus) with a normal capsular contour. There is appropriate echogenicity and echotexture. No focal lesions are observed. Splenic vasculature is normal.

**Liver**

The liver is subjectively normal in size with normal curvilinear peripheral contours. The parenchyma is hypoechoic relative to the spleen and slightly mottled in appearance. No distinct focal lesions are observed. Hepatic vasculature and intrahepatic biliary tracts are of normal volume with no evidence of congestion. The portal vein to caudal vena cava ratio is approximately 1:1.

The gall bladder lumen is moderately distended. The wall is thin and smooth. A scant amount of gravity-dependent hyperechoic debris is observed within the lumen. The cystic and common bile ducts are normal/not seen.

**Gastrointestinal**

The gastric lumen is not distended. The gastric wall and pylorus are normal in thickness with a normal layering pattern. The pyloric outflow tract is patent. The small intestinal lumen is not dilated. The small intestinal wall is normal in thickness with a normal layering pattern and appropriate mural



**PATIENT**

Pink Silveria

**SPECIES**

Canine

**BREED**

Siberian Husky

**SEX**

Female, spayed

**AGE**

10.5 Yrs.

**WEIGHT**

**INTERPRETED BY**

Andrea Nicastro, DVM,  
Diplomate ACVIM  
(Small Animal Internal  
Medicine)

**IMAGING PERFORMED BY**

Andrea Nicastro, DVM,  
Diplomate ACVIM  
(Small Animal Internal  
Medicine)

**HOSPITAL NAME**

Palmetto VH

**REFERRING VET**

Dr. Sivakoff

**INVOICE**

13732

**DATE**

5/19/26

detail. Discreet masses are not identified. The colonic wall is normal. The colonic lumen contains some shadowing fecal material. There is no obvious evidence of an obstructive pattern.

**Pancreas**

The region of the pancreas is isoechoic relative to surrounding omental fat. No obvious parenchymal abnormalities are observed. There is no evidence of regional inflammation or effusion.

**Lymph nodes**

The abdominal lymph nodes are normal/not visible.

**Free Abdomen**

The peritoneal cavity is normal. There is no evidence of inflammation or effusion.

**ULTRASONOGRAPHIC FINDINGS**

**Primary Findings:**

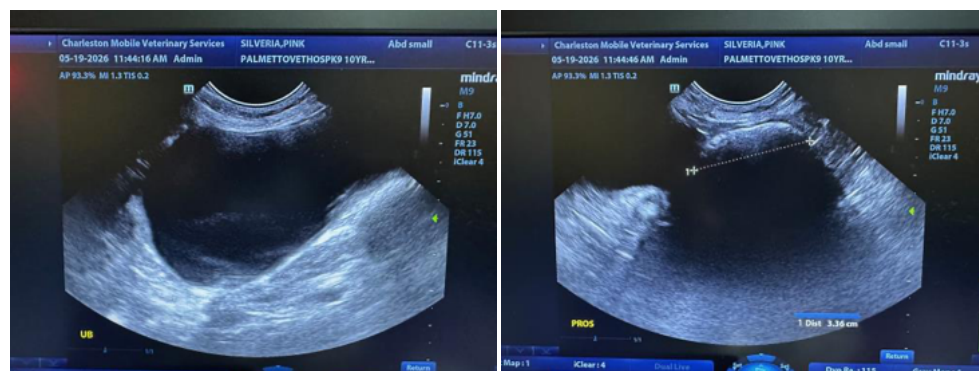
- The hepatic changes are nonspecific and could be secondary to inflammatory disease (i.e., cholangiohepatitis, chronic hepatitis), hepatotoxicosis (i.e., copper), infiltrative neoplasia (unlikely), other hepatopathy, or some combination thereof.

**Secondary Findings:**

- Minor bilateral age-related renal changes

**INTERPRETATION OF THE FINDINGS & FURTHER RECOMMENDATIONS**

1. Consider laparoscopic or surgical liver biopsies with aerobic and anaerobic bile cultures and hepatic copper quantitation.
2. If a more conservative approach is desired, consider empirical treatment for bacterial cholangiohepatitis (amoxicillin-clavulanic acid, Denamarin). If no improvement in the liver values is seen within 7-10 days of initiating therapy, antibiotics should be discontinued, and hepatic tissue sampling reconsidered. If liver values improve, continue therapy for at least 4-6 weeks and 1 week beyond normalization of the liver values.





**PATIENT**

Pink Silveria

**SPECIES**

Canine

**BREED**

Siberian Husky

**SEX**

Female, spayed

**AGE**

10.5 Yrs.

**WEIGHT**

**INTERPRETED BY**

Andrea Nicastro, DVM,  
 Diplomate ACVIM  
 (Small Animal Internal  
 Medicine)

**IMAGING  
 PERFORMED BY**

Andrea Nicastro, DVM,  
 Diplomate ACVIM  
 (Small Animal Internal  
 Medicine)

**HOSPITAL NAME**

Palmetto VH

**REFERRING VET**

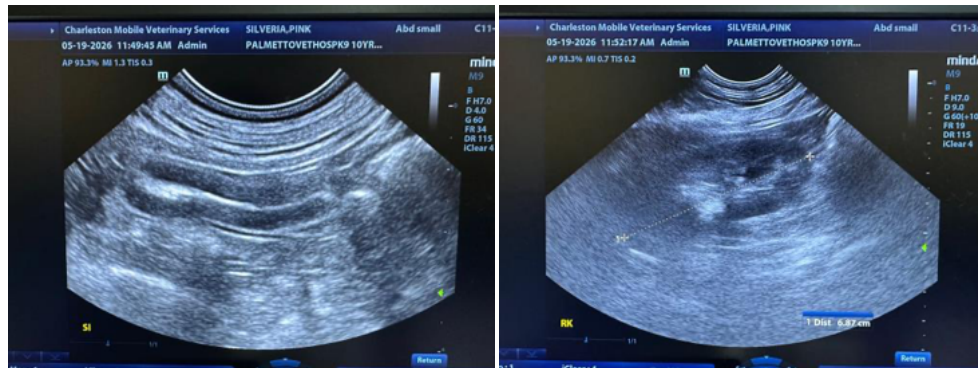
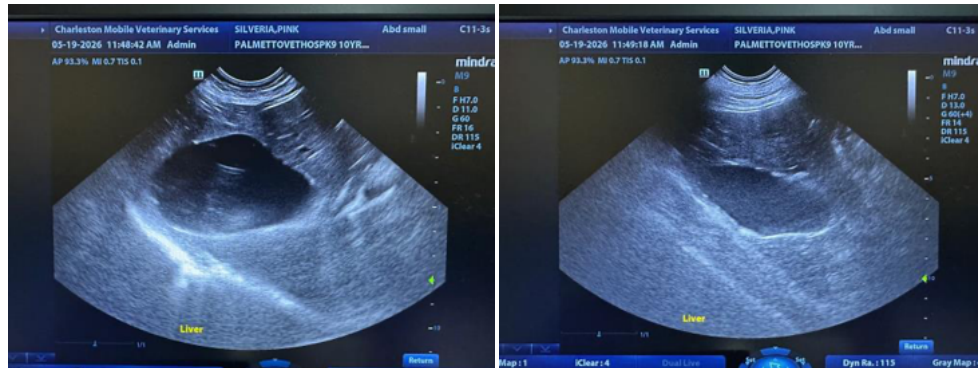
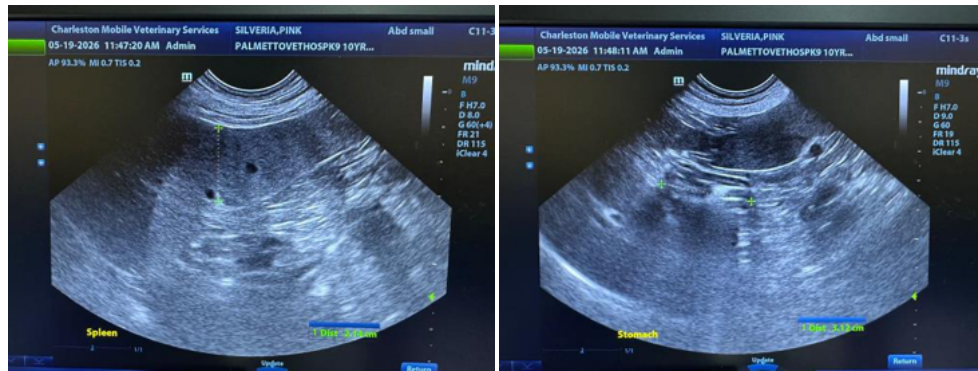
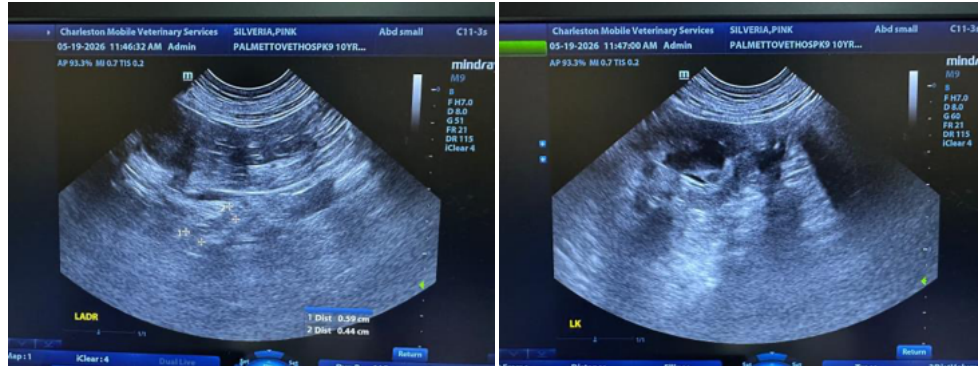
Dr. Sivakoff

**INVOICE**

13732

**DATE**

5/19/26





**PATIENT**

Pink Silveria

**SPECIES**

Canine

**BREED**

Siberian Husky

**SEX**

Female, spayed

**AGE**

10.5 Yrs.

**WEIGHT**

**INTERPRETED BY**

Andrea Nicastro, DVM,  
 Diplomate ACVIM  
 (Small Animal Internal  
 Medicine)

**IMAGING PERFORMED BY**

Andrea Nicastro, DVM,  
 Diplomate ACVIM  
 (Small Animal Internal  
 Medicine)

**HOSPITAL NAME**

Palmetto VH

**REFERRING VET**

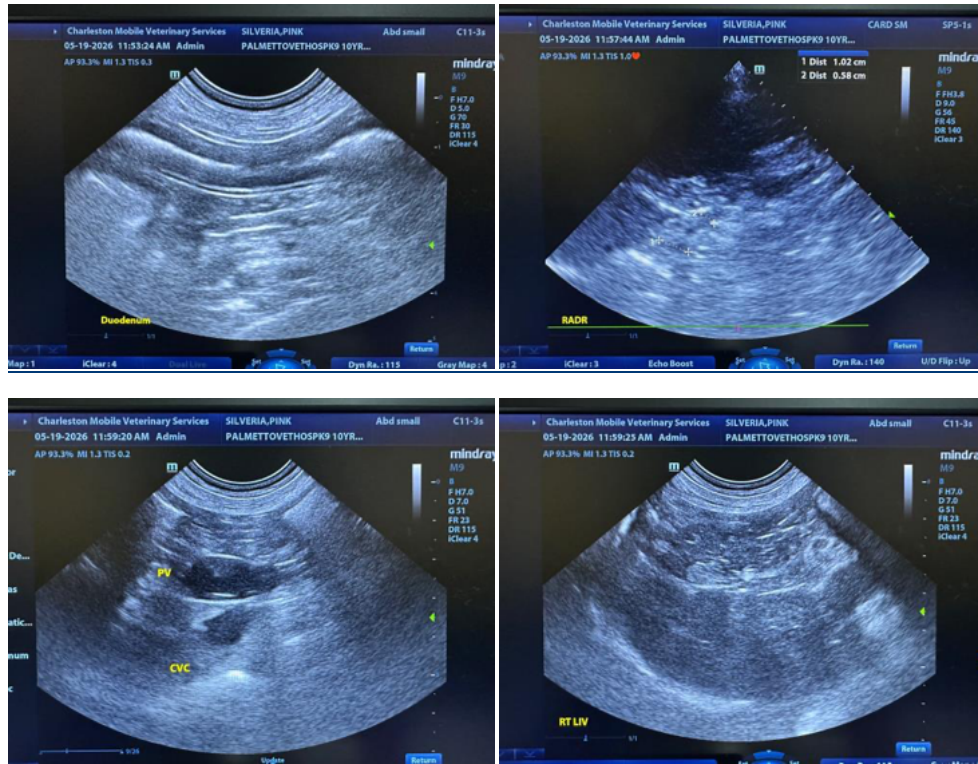
Dr. Sivakoff

**INVOICE**

13732

**DATE**

5/19/26



The information and recommendations provided are based on the images presented by the referring veterinarian/sonographer. No evaluation can be communicated regarding pathology that was not visible in the image/video clips provided.

Thank you for this referral. If the clinical or image interpretation does not parallel your findings or if I can be of any further assistance please contact me.

Andrea Nicastro, MPH, DVM, Diplomate DACVIM (Small Animal Internal Medicine)  
[info@SonoPath.com](mailto:info@SonoPath.com)