



PATIENT

Saltie Gillardon-Tarini

SPECIES

Canine

BREED

Golden Retriever

SEX

Female, intact

AGE

1 Yr.

WEIGHT

55.8

INTERPRETED BY

Andrea Nicastro, DVM,
Diplomate ACVIM
(Small Animal Internal
Medicine)

**IMAGING
PERFORMED BY**

Andrea Nicastro, DVM,
Diplomate ACVIM
(Small Animal Internal
Medicine)

HOSPITAL NAME

Sun Dog Cat Moon

REFERRING VET

Dr. Pruitt

INVOICE

13398

DATE

5/18/22

PRESENTING CLINICAL SIGNS

The patient was just spayed today and became acutely hypertensive during recovery with a normal heart rate; panting a lot. Has had one heat cycle which ended about 6 weeks ago.

ULTRASONOGRAPHIC EXAMINATION OF THE ABDOMEN

Urinary System

The urinary bladder, trigone, and pelvic urethra are normal in thickness and the mucosal surface is smooth. The bladder lumen is moderately distended. A small to moderate amount of suspended echogenic debris is observed within the lumen. No masses, inflammatory changes or calculi are observed. Ureteral papillae and visualized portion of the proximal urethra, visible to a depth of 2 cm, are normal.

The left kidney is normal size (6.66 cm in length); normal shape and architecture with smooth peripheral margins. There is a normal 1:3 cortex to medulla ratio with normal corticomedullary distinction. There is no evidence of pyelectasia, nephroliths, infarcts or hydroureter. Renal vasculature is normal.

The right kidney is normal size (7.29 cm in length); normal shape and architecture with smooth peripheral margins. There is a normal 1:3 cortex to medulla ratio with normal corticomedullary distinction. There is no evidence of pyelectasia, nephroliths, infarcts or hydroureter. Renal vasculature is normal.

Adrenal Glands

The left adrenal gland is normal size (0.37 cm at cranial pole) (0.41 cm at caudal pole); normal shape; homogenous parenchyma. The glandular echogenicity and detail are unremarkable. Capsule, cortex, and medullary definition are normal. The phrenicoabdominal vein and surrounding vasculature are normal.

The right adrenal gland is normal size (1.48 cm at cranial pole) (0.66 cm at caudal pole) (2.46 cm in length); normal shape; homogenous parenchyma. The glandular echogenicity and detail are unremarkable. Capsule, cortex, and medullary definition are normal. The phrenicoabdominal vein and surrounding vasculature are normal.

Spleen

The spleen is normal in size (2.21 cm in width at the level of the hilus) with a normal capsular contour. There is appropriate echogenicity and echotexture. No focal lesions are observed. Splenic vasculature is normal.

Liver

The liver is subjectively normal in size with normal contours and structure. There is appropriate echogenicity and echotexture. No overt structural evidence of inflammatory, infiltrative or regenerative pathology is evident. Vascular and biliary tracts are of normal volume with no evidence of congestion. No pathological hepatic lymphadenopathy observed. The gall bladder lumen is moderately distended. The wall is thin and smooth. Luminal contents are anechoic. The cystic and common bile ducts are normal/not seen.

Gastrointestinal



PATIENT

Saltie Gillardon-Tarini

SPECIES

Canine

BREED

Golden Retriever

SEX

Female, intact

AGE

1 Yr.

WEIGHT

55.8

INTERPRETED BY

Andrea Nicastro, DVM,
Diplomate ACVIM
(Small Animal Internal
Medicine)

IMAGING PERFORMED BY

Andrea Nicastro, DVM,
Diplomate ACVIM
(Small Animal Internal
Medicine)

HOSPITAL NAME

Sun Dog Cat Moon

REFERRING VET

Dr. Pruitt

INVOICE

13398

DATE

5/18/22

The stomach and intestine are free of stasis and exhibit normal peristaltic activity. The gastric lumen is mildly fluid distended. The gastric wall and pylorus are normal in thickness with a normal layering pattern. The pyloric outflow tract is patent. The small intestinal lumen is not dilated. The small intestinal wall thickness is normal with a normal layering pattern and appropriate mural detail. Discreet masses are not identified. The colonic wall is normal. No obstructive disease is noted.

Pancreas

The region of the pancreas is isoechoic relative to surrounding omental fat. No obvious parenchymal abnormalities are observed. There is no evidence of regional inflammation or effusion.

Free Abdomen

Trace free fluid is observed. The abdominal lymph nodes are normal/not visible.

Other

The region of the left and right pedicles and uterine stump appear as expected immediately post-ovariohysterectomy. No obvious pathology is seen.

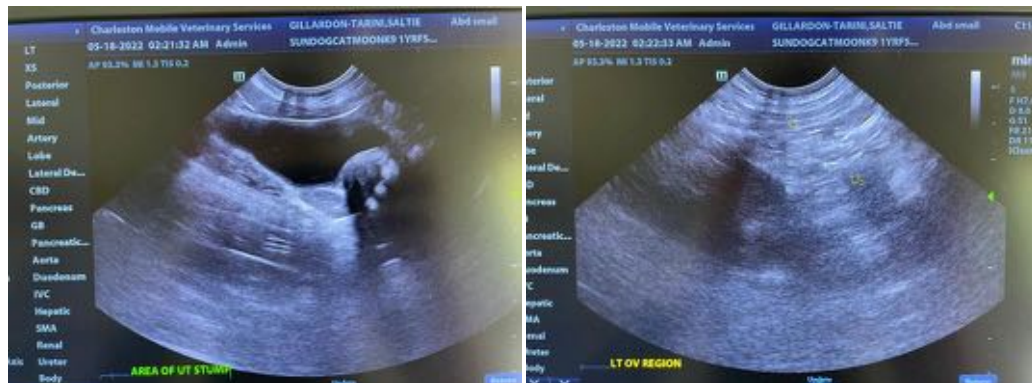A brief echocardiogram reveals no evidence of pericardial effusion or obvious right atrial/auricular mass.

ULTRASONOGRAPHIC FINDINGS

Trace ascites, as expected immediately post-surgery. No obvious evidence of excessive hemorrhage.

INTERPRETATION OF THE FINDINGS & FURTHER RECOMMENDATIONS

- Pain control and normal post-operative care is recommended with along with serial blood pressure monitoring.
- Consider baseline labwork including a CBC chemistry panel, urinalysis and T4, if not already performed.
- Consider a recheck AFAST in 1-2 hours to reassess for free fluid.





PATIENT

Saltie Gillardon-Tarini

SPECIES

Canine

BREED

Golden Retriever

SEX

Female, intact

AGE

1 Yr.

WEIGHT

55.8

INTERPRETED BY

Andrea Nicastro, DVM,
Diplomate ACVIM
(Small Animal Internal
Medicine)

IMAGING PERFORMED BY

Andrea Nicastro, DVM,
Diplomate ACVIM
(Small Animal Internal
Medicine)

HOSPITAL NAME

Sun Dog Cat Moon

REFERRING VET

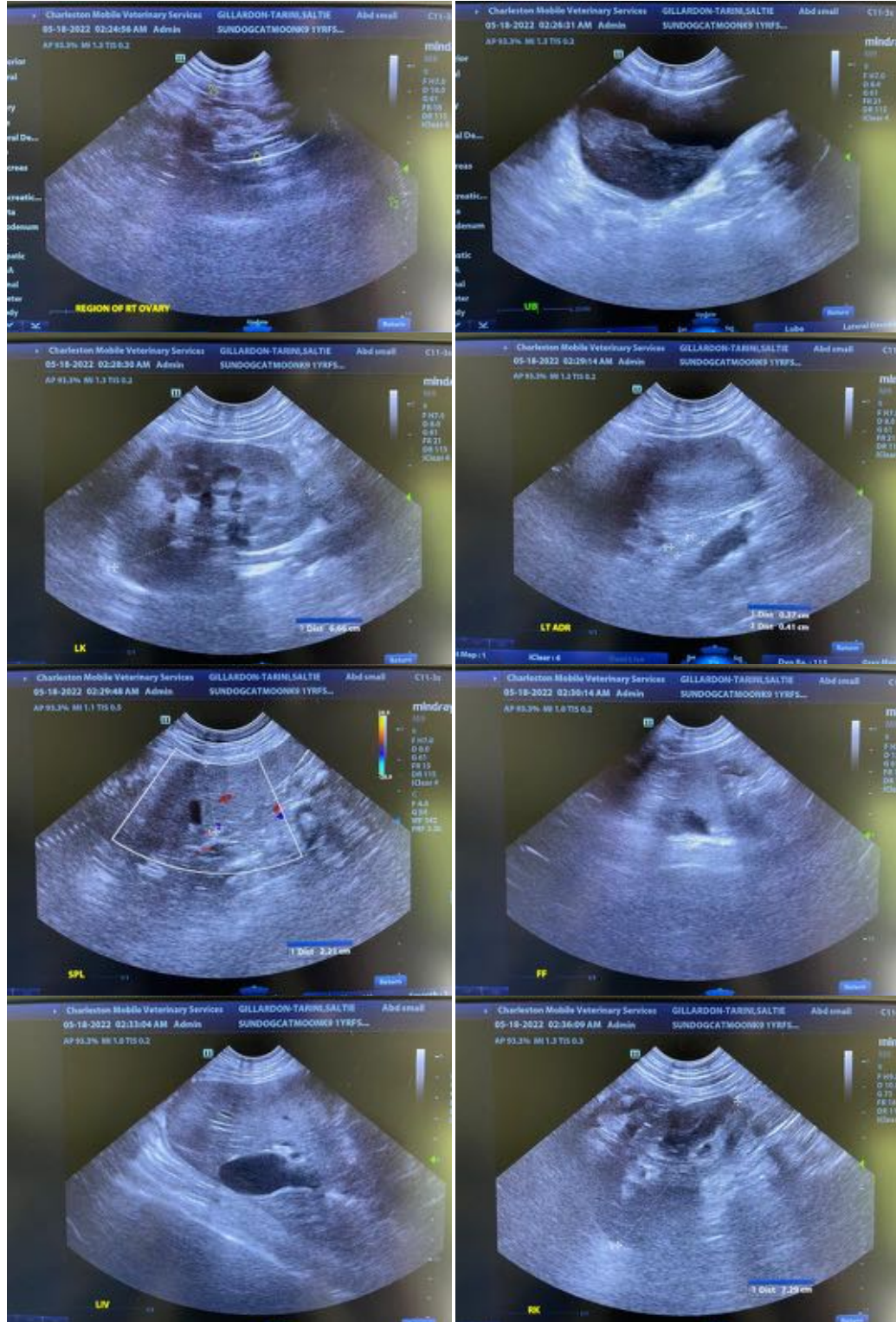
Dr. Pruitt

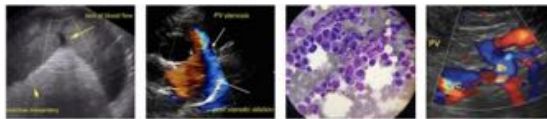
INVOICE

13398

DATE

5/18/22





PATIENT

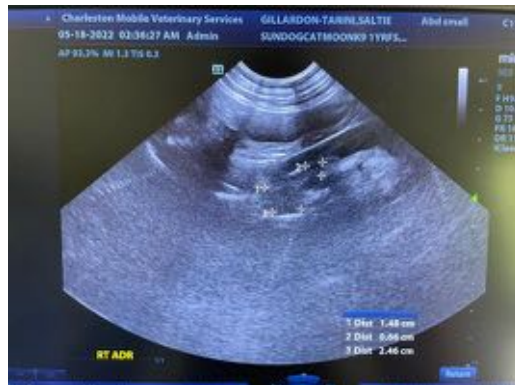Saltie Gillardon-Tarini

SPECIES

Canine

BREED

Golden Retriever



SEX

Female, intact

The information and recommendations provided are based on the images presented by the referring veterinarian/sonographer. No evaluation can be communicated regarding pathology that was not visible in the image/video clips provided.

AGE

1 Yr.

Thank you for this referral. If the clinical or image interpretation does not parallel your findings or if I can be of any further assistance please contact me.

WEIGHT

55.8

Andrea Nicastro, DVM, Diplomate ACVIM (*Small Animal Internal Medicine*)

Andrea.Nicastro@CharlestonMobile.net

INTERPRETED BY

Andrea Nicastro, DVM,
Diplomate ACVIM
(*Small Animal Internal
Medicine*)

**IMAGING
PERFORMED BY**

Andrea Nicastro, DVM,
Diplomate ACVIM
(*Small Animal Internal
Medicine*)

HOSPITAL NAME

Sun Dog Cat Moon

REFERRING VET

Dr. Pruitt

INVOICE

13398

DATE

5/18/22