Charleston Mobile Veterinary Services
IN PARTNERSHIP WITH SONOPATH VETERINARY ULTRASOUND

SonoPath
FOSTERING THE ART OF VETERINARY MEDICINE™
www.charlestonmobile.net
info@charlestonmobile.net 800.403.5408

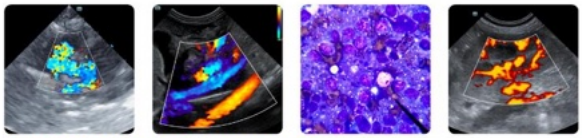

Clinical Sonography & Telecytology
Educational Teleconsultation Services™

PATIENT
Billy Joel Livigni

SPECIES
Canine

BREED
Shih Tzu

SEX
Male, neutered

AGE
11 Yrs. 10 months

WEIGHT

INTERPRETED BY
Andrea Nicastro, DVM, Diplomate ACVIM (*Small Animal Internal Medicine*)

IMAGING PERFORMED BY
Andrea Nicastro, DVM, Diplomate ACVIM (*Small Animal Internal Medicine*)

HOSPITAL NAME
VCA Palmetto

REFERRING VET
Dr. Buerkle

INVOICE
13692

DATE
4/29/26

PRESENTING CLINICAL SIGNS

Pt is a diabetic. Owners have been adjusting the insulin at home. Is currently on 12 units twice a day. Recent bloodwork reveals an ALT of 446, ALP of 446, GGT 23, T-bili normal at 0.2. These values are higher than they were on 2/19. At that time, the ALT was 150, ALP was 153, GGT 17. The patient also has a BUN of 34. Previously, the BUN was 16. Pt's blood glucose is relatively well regulated at the current insulin dose.

ULTRASONOGRAPHIC EXAMINATION OF THE ABDOMEN

Urinary System

The urinary bladder wall is normal in thickness and the mucosal surface in the region of the apex is slightly irregular. The bladder is moderately distended. Luminal contents are anechoic. No cystic calculi are observed. The region of the trigone and the proximal urethra, visible to a depth of 2 cm, are normal.

The prostate is normal in size (0.70 cm in width) and shape. Parenchyma is homogenous. The prostatic urethra appears normal without evidence of dilation or obstruction.

The left kidney is normal in size (4.79 cm in length) with a normal shape, architecture and smooth peripheral margins. There is a normal 1:3 cortex to medulla ratio with mild loss of corticomedullary distinction. There is no evidence of pyelectasia, nephroliths, infarcts or hydroureter. Renal vasculature is normal.

The right kidney is normal in size (5.36 cm in length) with a normal shape, architecture and smooth peripheral margins. There is a normal 1:3 cortex to medulla ratio with mild to moderate loss of corticomedullary distinction. There is no evidence of pyelectasia, nephroliths, infarcts or hydroureter. Renal vasculature is normal.

Adrenal Glands

The left adrenal gland is mildly enlarged (0.63 cm at cranial pole) (0.69 cm at caudal pole) with swollen peripheral contours. The glandular echogenicity and detail are unremarkable. The phrenicoabdominal vein and surrounding vasculature are normal.

The right adrenal gland is mildly enlarged (0.85 cm at cranial pole) (0.70 cm at caudal pole) with swollen peripheral contours. The glandular echogenicity and detail are unremarkable. The phrenicoabdominal vein and surrounding vasculature are normal.

Spleen

The spleen is normal in size (0.94 cm in width at the level of the hilus) with a normal capsular contour. There is appropriate echogenicity and echotexture. No focal lesions are observed. Splenic vasculature is normal.

Liver

The liver is subjectively enlarged with slightly swollen peripheral contours. The parenchyma is isoechoic relative to the spleen and diffusely homogeneous in appearance. No distinct focal lesions are observed. Vascular and biliary tracts are of normal volume with no evidence of congestion. The portal vein to caudal vena cava ratio is approximately 1:1.

The gall bladder lumen is moderately distended. The wall is thin and smooth. A scant amount of echogenic debris is observed within the lumen. The cystic and common bile ducts are normal/not seen. The duodenal papilla is normal in size (0.30 cm in width).

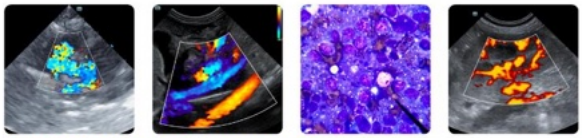

Clinical Sonography & Telecytology
Educational Teleconsultation Services™

PATIENT
Billy Joel Livigni

SPECIES
Canine

BREED
Shih Tzu

SEX
Male, neutered

AGE
11 Yrs. 10 months

WEIGHT

Gastrointestinal
The gastric lumen is not distended. The gastric wall and pylorus are normal in thickness with a normal layering pattern. The pyloric outflow tract is patent. The small intestinal lumen is not dilated. The small intestinal wall is normal in thickness with a normal layering pattern and appropriate mural detail. Discreet masses are not identified. The ileocecocolic junction and colonic wall are normal. There is no evidence of an obstructive pattern.

Pancreas
The base and limbs of the pancreas are normal in size with normal curvilinear peripheral contours. The parenchyma is largely isoechoic relative to surrounding omental fat and slightly mottled in appearance. The pancreatic duct is visible but not overtly dilated. There is no evidence of peripancreatic inflammation or effusion.

Lymph nodes
The abdominal lymph nodes are normal/not visible.

Free Abdomen
The peritoneal cavity is normal. There is no evidence of inflammation or effusion.

INTERPRETED BY
Andrea Nicastro, DVM, Diplomate ACVIM (*Small Animal Internal Medicine*)

IMAGING PERFORMED BY
Andrea Nicastro, DVM, Diplomate ACVIM (*Small Animal Internal Medicine*)

HOSPITAL NAME
VCA Palmetto

REFERRING VET
Dr. Buerkle

INVOICE
13692

DATE
4/29/26

ULTRASONOGRAPHIC FINDINGS

Primary Findings:

- The hepatic changes are nonspecific and could be secondary to inflammatory disease (i.e., cholangiohepatitis, chronic hepatitis), Leptospirosis, hepatotoxicosis, infiltrative neoplasia (i.e., lymphoma), vacuolar hepatopathy, regenerative nodular hyperplasia, other hepatopathy, or some combination thereof.
- Mild bilateral adrenomegaly

Secondary Findings:

- Minor age-related pancreatic parenchymal remodeling
- Mild bilateral nonspecific, age-related renal changes

INTERPRETATION OF THE FINDINGS & FURTHER RECOMMENDATIONS

1. To further evaluate the elevated liver values, consider hepatic tissue sampling (i.e., aspirates or biopsies). If biopsies are pursued, aerobic and anaerobic bile cultures and hepatic copper quantitation should also be performed.
2. If a conservative approach is desired, consider empirical treatment for bacterial cholangiohepatitis (amoxicillin-clavulanic acid, Denamarin). If no improvement in the liver values is seen within 7-10 days of initiating therapy, antibiotics should be discontinued, and hepatic tissue sampling reconsidered. If liver values improve, continue therapy for at least 4-6 weeks and 1 week beyond normalization of the liver values.
3. If the patient is to undergo anesthesia, benzodiazepines should be avoided and opioids used judiciously.

PATIENT

Billy Joel Livigni

SPECIES

Canine

BREED

Shih Tzu

SEX

Male, neutered

AGE

11 Yrs. 10 months

WEIGHT

INTERPRETED BY

Andrea Nicastro, DVM, Diplomate ACVIM (*Small Animal Internal Medicine*)

IMAGING PERFORMED BY

Andrea Nicastro, DVM, Diplomate ACVIM (*Small Animal Internal Medicine*)

HOSPITAL NAME

VCA Palmetto

REFERRING VET

Dr. Buerkle

INVOICE

13692

DATE
4/29/26

4. Consider testing for hyperadrenocorticism with a low-dose dexamethasone suppression test or ACTH stimulation test if clinical signs (i.e., PU/PD) develop in the future.

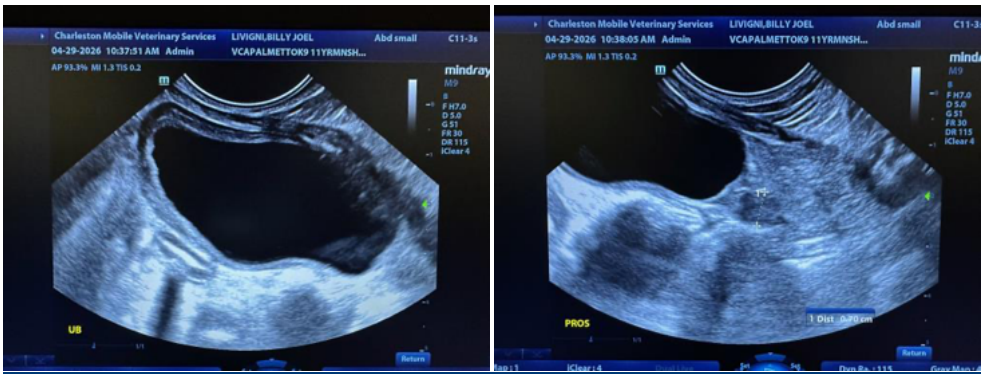

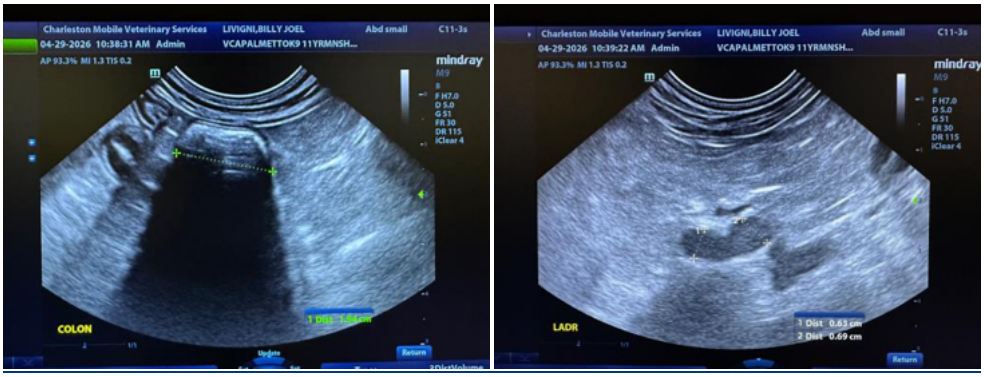

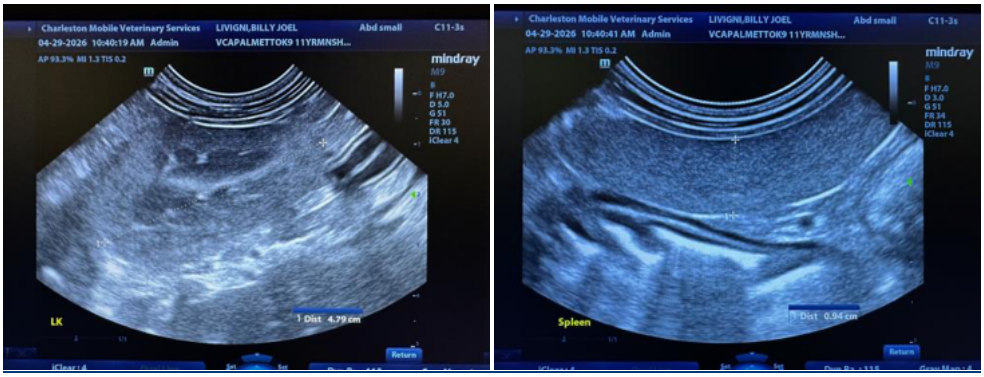

Charleston Mobile Veterinary Services
IN PARTNERSHIP WITH SONOPATH VETERINARY ULTRASOUND

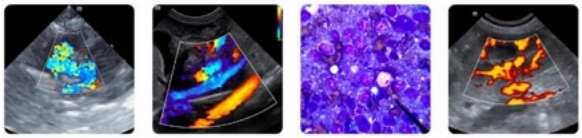

Clinical Sonography & Telecytology
Educational Teleconsultation Services™

SonoPath
FOSTERING THE ART OF VETERINARY MEDICINE™

www.charlestonmobile.net
info@charlestonmobile.net 800.403.5408

PATIENT

Billy Joel Livigni

SPECIES

Canine

BREED

Shih Tzu

SEX

Male, neutered

AGE

11 Yrs. 10 months

WEIGHT

INTERPRETED BY

Andrea Nicastro, DVM, Diplomate ACVIM (*Small Animal Internal Medicine*)

IMAGING PERFORMED BY

Andrea Nicastro, DVM, Diplomate ACVIM (*Small Animal Internal Medicine*)

HOSPITAL NAME

VCA Palmetto

REFERRING VET

Dr. Buerkle

INVOICE

13692

DATE
4/29/26

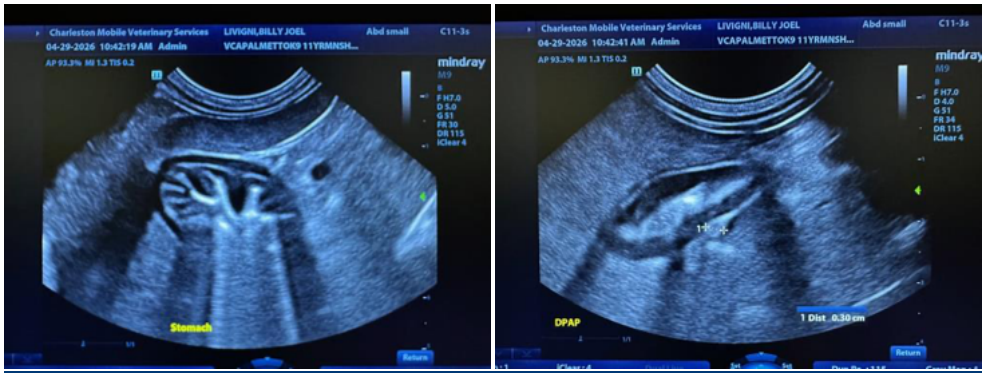

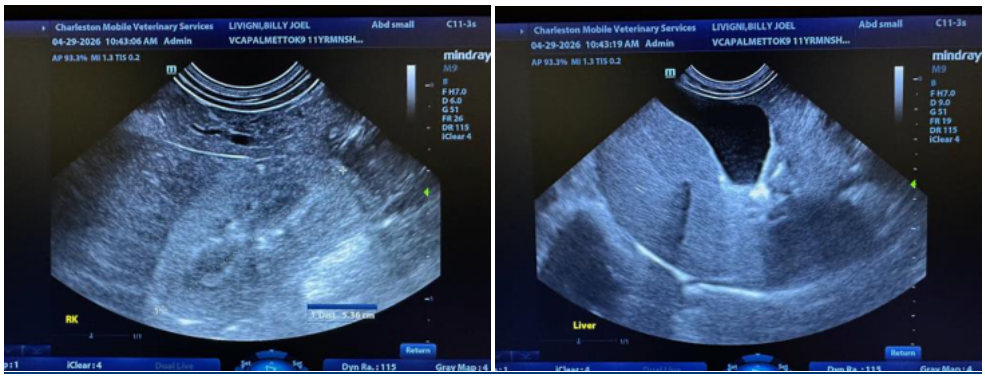

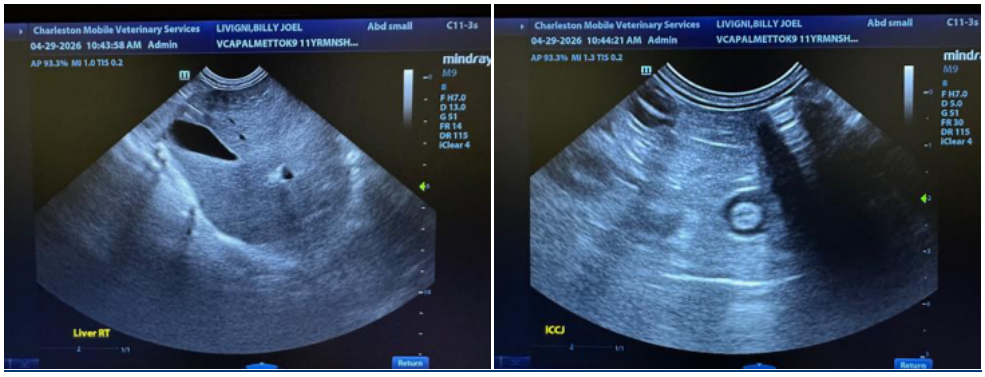

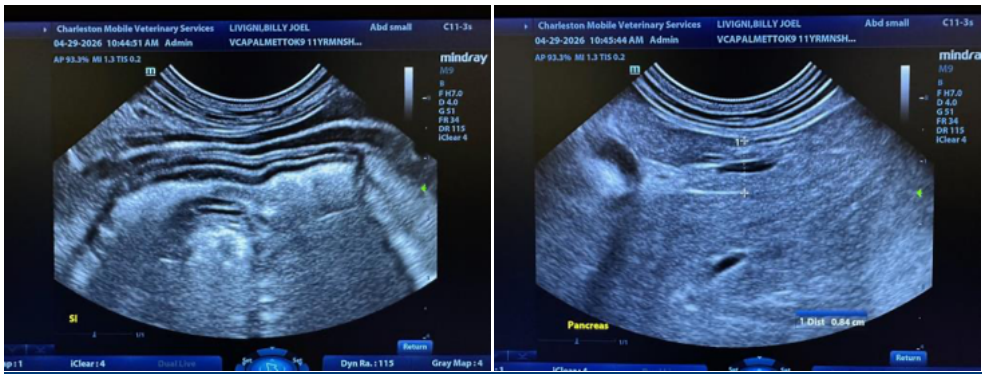

Charleston Mobile Veterinary Services
IN PARTNERSHIP WITH SONOPATH VETERINARY ULTRASOUND

SonoPath
FOSTERING THE ART OF VETERINARY MEDICINE
www.charlestonmobile.net
info@charlestonmobile.net 800.403.5408

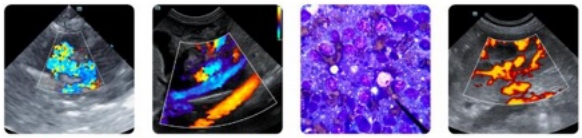

Clinical Sonography & Telecytology
Educational Teleconsultation Services™

PATIENT

Billy Joel Livigni

SPECIES

Canine

BREED

Shih Tzu

SEX

Male, neutered

AGE

11 Yrs. 10 months

WEIGHT

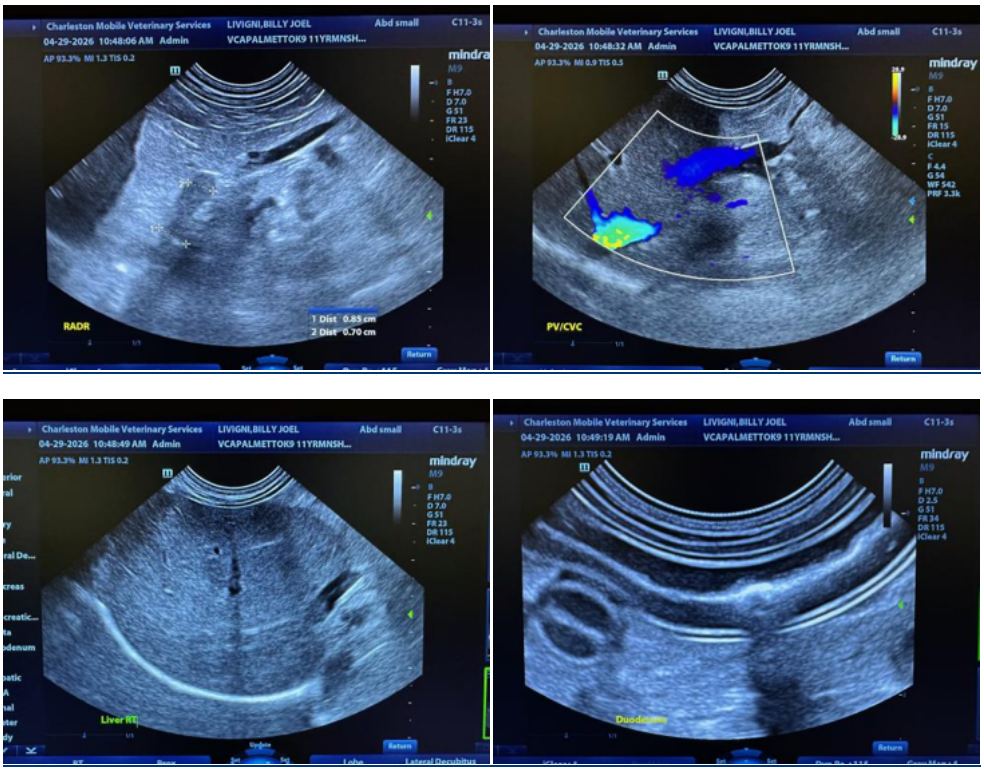

INTERPRETED BY

Andrea Nicastro, DVM, Diplomate ACVIM (*Small Animal Internal Medicine*)

The information and recommendations provided are based on the images presented by the referring veterinarian/sonographer. No evaluation can be communicated regarding pathology that was not visible in the image/video clips provided.

Thank you for this referral. If the clinical or image interpretation does not parallel your findings or if I can be of any further assistance please contact me.

Andrea Nicastro, MPH, DVM, Diplomate DACVIM (Small Animal Internal Medicine)
info@SonoPath.com

IMAGING PERFORMED BY

Andrea Nicastro, DVM, Diplomate ACVIM (*Small Animal Internal Medicine*)

HOSPITAL NAME

VCA Palmetto

REFERRING VET

Dr. Buerkle

INVOICE

13692

DATE
4/29/26