

**PATIENT**

Theadora Bracken

**SPECIES**

Canine

**BREED**

German Shepherd

**SEX**

Female, spayed

**AGE**

4/1/2023

**WEIGHT**

63.2 lbs.

**INTERPRETED BY**

Andrea Nicastro, DVM,  
 Diplomate ACVIM  
 (Small Animal Internal  
 Medicine)

**IMAGING PERFORMED BY**

Andrea Nicastro, DVM,  
 Diplomate ACVIM  
 (Small Animal Internal  
 Medicine)

**HOSPITAL NAME**

Saddleback

**REFERRING VET**

Dr. Klein

**INVOICE**

13687

**DATE**

4/28/26

**PRESENTING CLINICAL SIGNS**

Pt presented with vomiting and GI upset. CBC chem WNL. GI panel and resting cortisol levels are pending. Pt sedated with Dexdomitor for this study. A fecal PCR panel is pending. Pt is on a raw diet.

**ULTRASONOGRAPHIC EXAMINATION OF THE ABDOMEN**

**Urinary System**

The urinary bladder wall is normal in thickness and the mucosal surface is smooth. The bladder is moderately distended. Luminal contents are anechoic. No cystic calculi are observed. The region of the trigone and the visible portion of the proximal urethra are normal.

The left kidney is normal in size (6.47 cm in length) with a normal shape, architecture and smooth peripheral margins. There is a normal 1:3 cortex to medulla ratio with normal corticomedullary distinction. There is no evidence of pyelectasia, nephroliths, infarcts or hydroureter. Renal vasculature is normal.

The right kidney is normal in size (7.69 cm in length) with a normal shape, architecture and smooth peripheral margins. There is a normal 1:3 cortex to medulla ratio with normal corticomedullary distinction. There is no evidence of pyelectasia, nephroliths, infarcts or hydroureter. Renal vasculature is normal.

**Adrenal Glands**

The left adrenal gland is normal in size (0.41 cm at cranial pole) (0.48 cm at caudal pole) with a normal shape and homogenous parenchyma. The glandular echogenicity and detail are unremarkable. Capsule, cortex, and medullary definition are normal. The phrenicoabdominal vein and surrounding vasculature are normal.

The right adrenal gland is normal in size (1.13 cm at cranial pole) (0.47 cm at caudal pole) with a normal shape and homogenous parenchyma. The glandular echogenicity and detail are unremarkable. Capsule, cortex, and medullary definition are normal. The phrenicoabdominal vein and surrounding vasculature are normal.

**Spleen**

The spleen is normal in size (1.23 cm in width at the level of the hilus) with a normal capsular contour. There is appropriate echogenicity and echotexture. No focal lesions are observed. Splenic vasculature is normal.

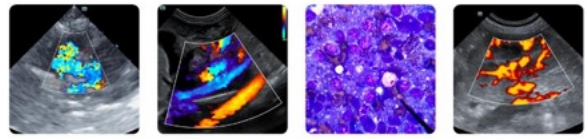
**Liver**

The liver is subjectively normal in size with normal contours and structure. There is appropriate echogenicity and echotexture. No overt structural evidence of inflammatory, infiltrative, or regenerative pathology is evident. Vascular and biliary tracts are of normal volume with no evidence of congestion.

The gallbladder is of normal contours and contains some dependent echogenic debris. The wall is normal in thickness. No choleliths are observed. The cystic and common bile ducts are normal.

**Gastrointestinal**

The gastric lumen is not distended. The gastric wall and pylorus are normal in thickness with a normal layering pattern. The pyloric outflow tract is patent. The small intestinal lumen is not dilated. The small intestinal wall is normal in thickness with a normal layering pattern and appropriate mural detail. Discreet masses are not identified. The ileocecolic junction and colonic wall are normal. There is no evidence of an obstructive pattern.



**PATIENT**

Theadora Bracken

**SPECIES**

Canine

**BREED**

German Shepherd

**SEX**

Female, spayed

**AGE**

4/1/2023

**WEIGHT**

63.2 lbs.

**INTERPRETED BY**

Andrea Nicastro, DVM,  
Diplomate ACVIM  
(Small Animal Internal  
Medicine)

**IMAGING PERFORMED BY**

Andrea Nicastro, DVM,  
Diplomate ACVIM  
(Small Animal Internal  
Medicine)

**HOSPITAL NAME**

Saddleback

**REFERRING VET**

Dr. Klein

**INVOICE**

13687

**DATE**

4/28/26

**Pancreas**

The region of the pancreas is isoechoic relative to surrounding omental fat. No obvious parenchymal abnormalities are observed. There is no evidence of regional inflammation or effusion.

**Lymph nodes**

2-3 prominent mesenteric lymph nodes are visualized, one of the nodes measuring 1.69 x 0.68 cm.

**Free Abdomen**

There is no obvious evidence of free fluid.

**Other**

A brief echocardiogram reveals no evidence of pericardial effusion or obvious right atrial/auricular mass.

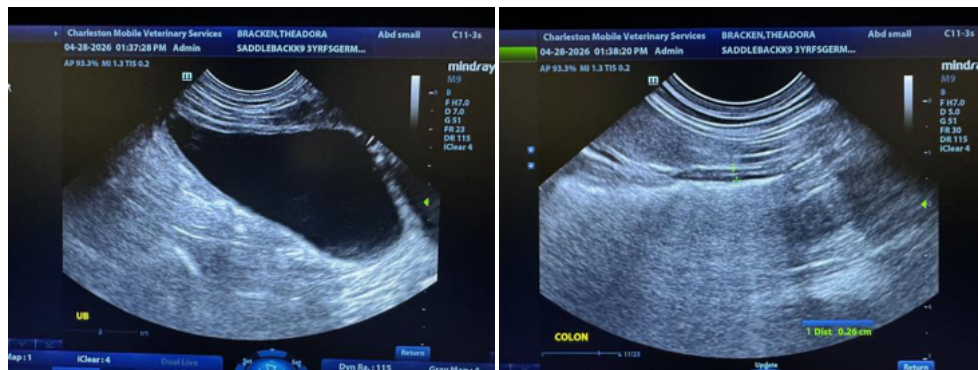
**ULTRASONOGRAPHIC FINDINGS**

- The prominent abdominal lymph nodes are most consistent with reactive lymphadenitis or lymphoid hyperplasia. Neoplastic infiltration is considered less likely.
- The remainder of the abdomen is structurally unremarkable.

\*\*An obvious cause for the patient's clinical signs is not definitively identified in this study. Considerations include a microscopic enteropathy (i.e., food allergy/intolerance, inflammatory bowel disease, infectious/parasitic disease), underlying metabolic issue, other.

**INTERPRETATION OF THE FINDINGS & FURTHER RECOMMENDATIONS**

1. Consider prophylactic deworming with fenbendazole.
2. Also consider initiation of a probiotic as well as a fiber supplement.
3. If the pending diagnostics are inconclusive, consider transitioning to a limited antigen or hydrolyzed protein diet.
4. Ultimately, endoscopic or surgical GI biopsies may be necessary to get a definitive diagnosis.





**PATIENT**

Theadora Bracken

**SPECIES**

Canine

**BREED**

German Shepherd

**SEX**

Female, spayed

**AGE**

4/1/2023

**WEIGHT**

63.2 lbs.

**INTERPRETED BY**

Andrea Nicastro, DVM,  
 Diplomate ACVIM  
 (Small Animal Internal  
 Medicine)

**IMAGING  
 PERFORMED BY**

Andrea Nicastro, DVM,  
 Diplomate ACVIM  
 (Small Animal Internal  
 Medicine)

**HOSPITAL NAME**

Saddleback

**REFERRING VET**

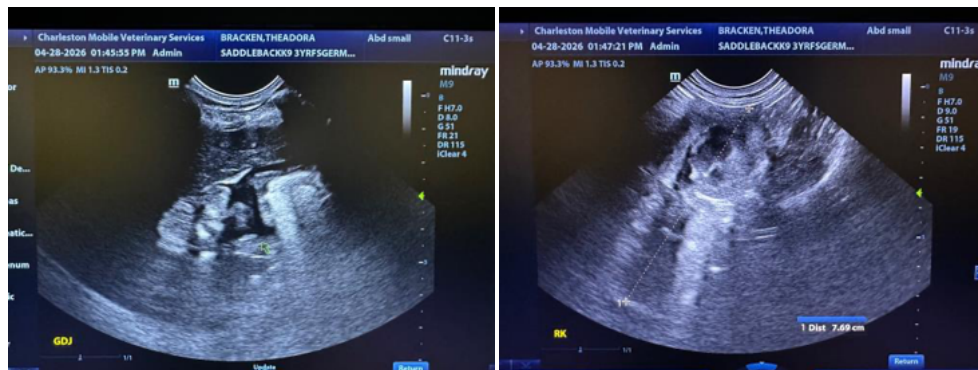
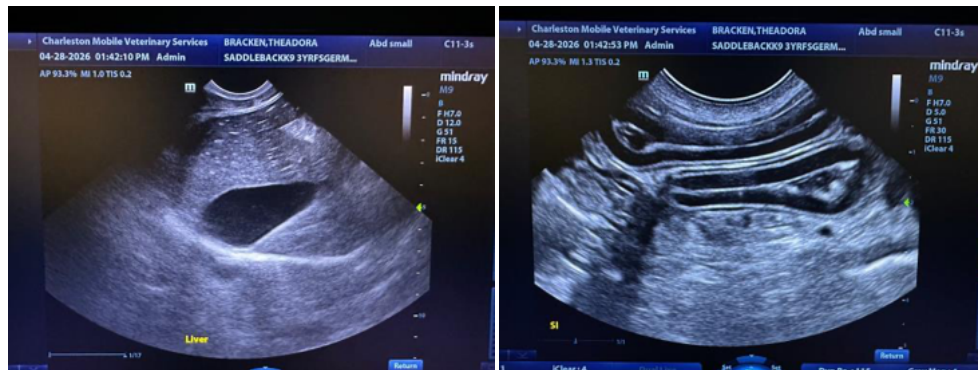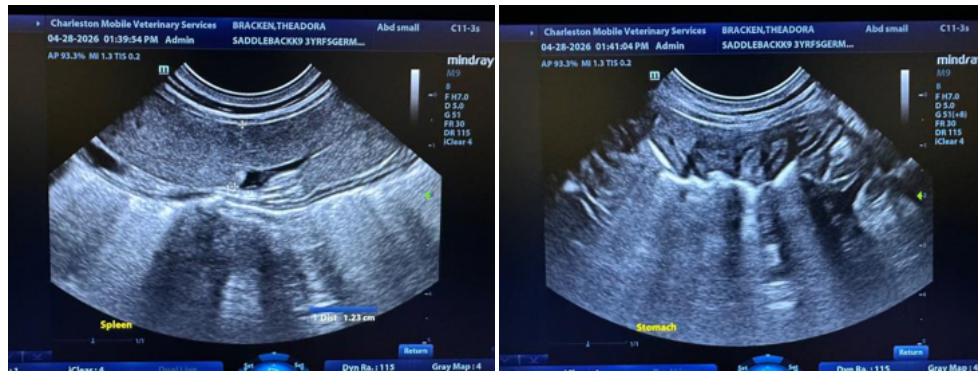
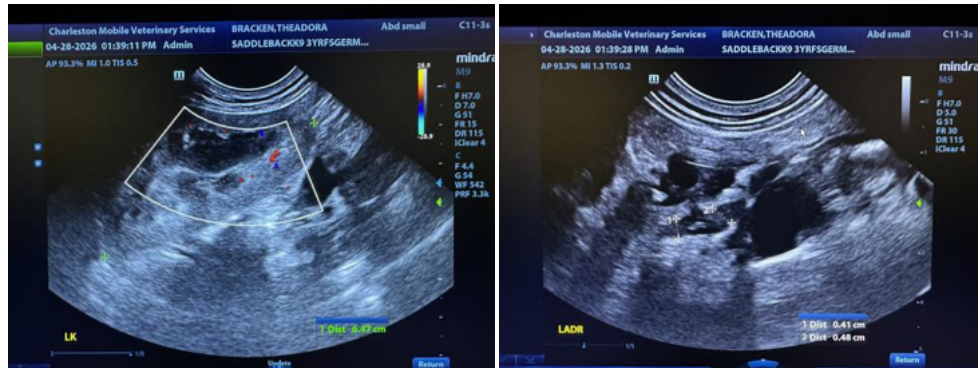
Dr. Klein

**INVOICE**

13687

**DATE**

4/28/26





**PATIENT**

Theadora Bracken

**SPECIES**

Canine

**BREED**

German Shepherd

**SEX**

Female, spayed

**AGE**

4/1/2023

**WEIGHT**

63.2 lbs.

**INTERPRETED BY**

Andrea Nicastro, DVM,  
 Diplomate ACVIM  
 (Small Animal Internal  
 Medicine)

**IMAGING PERFORMED BY**

Andrea Nicastro, DVM,  
 Diplomate ACVIM  
 (Small Animal Internal  
 Medicine)

**HOSPITAL NAME**

Saddleback

**REFERRING VET**

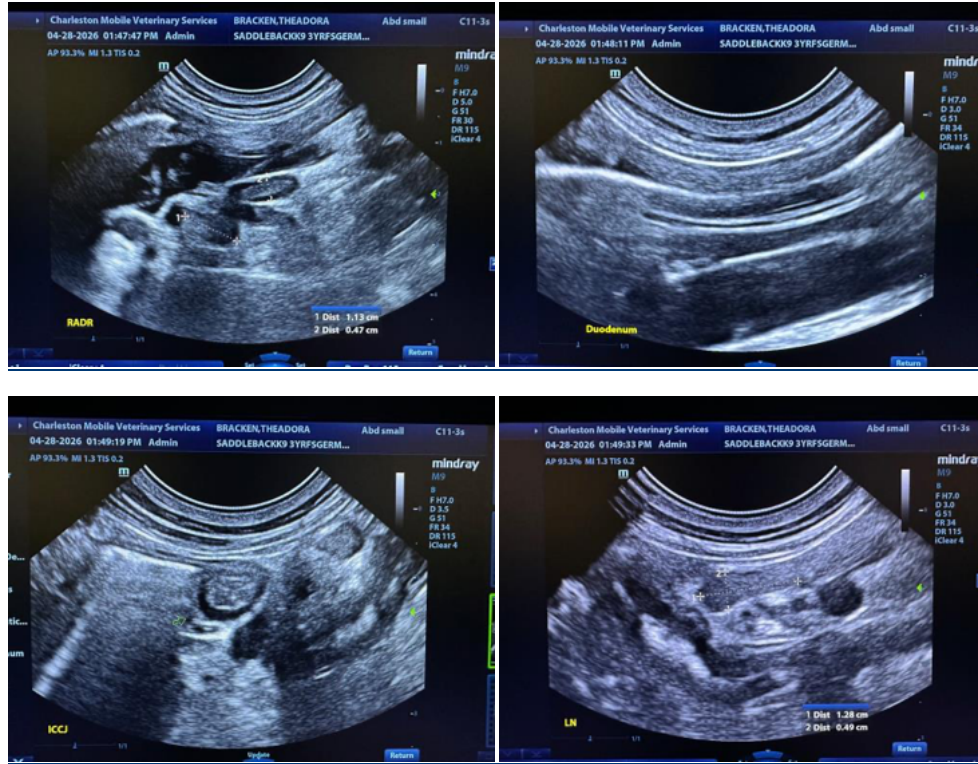
Dr. Klein

**INVOICE**

13687

**DATE**

4/28/26



The information and recommendations provided are based on the images presented by the referring veterinarian/sonographer. No evaluation can be communicated regarding pathology that was not visible in the image/video clips provided.

Thank you for this referral. If the clinical or image interpretation does not parallel your findings or if I can be of any further assistance please contact me.

Andrea Nicastro, MPH, DVM, Diplomate DACVIM (Small Animal Internal Medicine)  
[info@SonoPath.com](mailto:info@SonoPath.com)