



PATIENT PRESENTING CLINICAL SIGNS

Cassie Zink Temp (°F): 101.30 H.R.: 172 R.R.: 32 Eyes: No Abnormal Findings Ears: No Abnormal Findings Oronasal: MM pink Dermatologic: No significant findings Lymph Nodes: WNL Heart: Strong, synchronous pulses; No murmur, Normal rhythm Lungs: clear Abdomen: tense with palpation but Benign, non-painful Urogenital: NSF - no vaginal discharge and/or mass noted today, digital exam normal MS/ Orthopedic: ambx4, no pain and/or swelling noted, No significant finding Neurologic: Full neuro NE; No significant findings BCS/Other: BCS 5/9; rectal - NSF, normal formed stool Weight: 4.64 kg

BREED

Dachshund Today: ALT 255U/L CBC (4/7/22): PLT 571 (170-400), LYMPH 5324 (690-4500) Chemistry (4/7/22): AST 69 (15-66), ALT 295 (12-118), UREA N 41 (6-31), crea 0.9, BUN/CREA 46 (4-27), cPL 157 (24-140) T4 (4/7/22): WNL (1.8) Urinalysis (4/7/22): PRO trace, SG 1.042 Heartworm (4/7/22): neg Fecal (8/24/21): neg 8 thoracic + abdominal x-rays interpretation 8/23/21 AUS via Collaboration 8/24/21 Cytology, 2 vulva slides (4/12/22): suppurative inflammation Aerobic c+s, vulva (4/12/22): Pasturella

SEX

Female, spayed

AGE

9/20/2008

ULTRASONOGRAPHIC EXAMINATION OF THE ABDOMEN

Urinary System

WEIGHT

4.6 lbs.

The urinary bladder, trigone, and pelvic urethra are normal in thickness and the mucosal surface is smooth. The bladder lumen is moderately distended with anechoic urine. No masses, inflammatory changes or calculi are observed. Ureteral papillae and visualized portion of the proximal urethra, visible to a depth of 2 cm, are normal.

INTERPRETED BY

Andrea Nicastro, DVM,
Diplomate ACVIM
(Small Animal Internal
Medicine)

The left kidney is normal size (3.77 cm in length); normal shape and architecture with smooth peripheral margins. There is a normal 1:3 cortex to medulla ratio with minimal loss of corticomedullary distinction. There is no evidence of pyelectasia, nephroliths, infarcts or hydronephrosis. Renal vasculature is normal.

The right kidney is normal size (4.02 cm in length); normal shape and architecture with smooth peripheral margins. There is a normal 1:3 cortex to medulla ratio with minimal loss of corticomedullary distinction. There is no evidence of pyelectasia, nephroliths, infarcts or hydronephrosis. Renal vasculature is normal.

IMAGING PERFORMED BY

Andrea Nicastro, DVM,
Diplomate ACVIM
(Small Animal Internal
Medicine)

Adrenal Glands

HOSPITAL NAME

Blue Pearl

The left adrenal gland is mildly enlarged (0.59 cm at cranial pole) (0.57 cm at caudal pole) (1.65 cm in length); normal shape; homogenous parenchyma. The glandular echogenicity and detail are unremarkable. Capsule, cortex, and medullary definition are normal. The phrenicoabdominal vein and surrounding vasculature are normal.

REFERRING VET

Dr. Johnson

The right adrenal gland is mildly enlarged (0.68 cm at cranial pole) (0.58 cm at caudal pole) (1.51 cm in length); normal shape; homogenous parenchyma. The glandular echogenicity and detail are unremarkable. Capsule, cortex, and medullary definition are normal. The phrenicoabdominal vein and surrounding vasculature are normal.

INVOICE

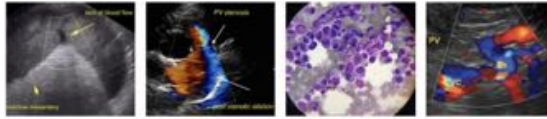
13281

Spleen

DATE

4/27/22

The spleen is normal in size (0.88 cm in width at the level of the hilus) with a normal capsular contour. There is appropriate echogenicity and echotexture. No focal lesions are observed. Splenic vasculature is normal.



PATIENT *Liver*

Cassie Zink The liver is prominent in size with normal curvilinear peripheral contours. The parenchyma is slightly mottled in appearance. No distinct focal lesions are observed. Vascular and biliary tracts are of normal volume with no evidence of congestion. The portal vein: caudal vena cava ratio is approximately 1:1. The gall bladder lumen is moderately distended. The wall is thin and smooth. A small amount of aggregated echogenic mostly gravity-dependent debris is observed within the lumen. The cystic and common bile ducts are normal/not seen.

BREED *Gastrointestinal*

Dachshund The stomach and intestine are free of stasis and exhibit normal peristaltic activity. The gastric lumen is not distended. The gastric wall and pylorus are normal in thickness with a normal layering pattern. The pyloric outflow tract is patent. The small intestinal lumen is not dilated. The small intestinal wall thickness is normal with a normal layering pattern and appropriate mural detail. Discreet masses are not identified. The colonic wall is normal. No obstructive disease is noted.

SEX

Female, spayed

AGE

9/20/2008

Pancreas

The region of the pancreas is isoechoic relative to surrounding omental fat. No obvious parenchymal abnormalities are observed. There is no evidence of regional inflammation or effusion.

WEIGHT

4.6 lbs.

Free Abdomen

The peritoneal cavity is normal. There is no evidence of inflammation or effusion. The abdominal lymph nodes are normal/not visible.

INTERPRETED BY

Andrea Nicastro, DVM,
Diplomate ACVIM
(Small Animal Internal
Medicine)

Other

A brief echocardiogram reveals no evidence of pericardial effusion or obvious right atrial/auricular mass.

IMAGING PERFORMED BY

Andrea Nicastro, DVM,
Diplomate ACVIM
(Small Animal Internal
Medicine)

ULTRASONOGRAPHIC FINDINGS

- Mild bilateral adrenomegaly.
- The sonographic hepatic changes are most consistent with age-related remodeling. However, given the mild liver enzyme elevations, a microscopic hepatopathy (i.e., chronic active hepatitis, bacterial cholangiohepatitis, copper hepatotoxicosis, Leptospirosis) cannot be excluded.
- Gallbladder debris, non-mucocele.

HOSPITAL NAME

Blue Pearl

*There is no obvious evidence of neoplasia in the abdomen.

REFERRING VET

Dr. Johnson

INTERPRETATION OF THE FINDINGS & FURTHER RECOMMENDATIONS

INVOICE

13281

- Thoracic radiographs (three-view) are recommended prior to anesthesia for the vaginoscopy.
- Serial monitoring of the patient's liver values is recommended. Hepatic tissue sampling may be necessary to further evaluate the abnormal values.

DATE

4/27/22



PATIENT

Cassie Zink

SPECIES

Canine

BREED

Dachshund

SEX

Female, spayed

AGE

9/20/2008

WEIGHT

4.6 lbs.

INTERPRETED BY

Andrea Nicastro, DVM,
Diplomate ACVIM
(Small Animal Internal
Medicine)

IMAGING PERFORMED BY

Andrea Nicastro, DVM,
Diplomate ACVIM
(Small Animal Internal
Medicine)

HOSPITAL NAME

Blue Pearl

REFERRING VET

Dr. Johnson

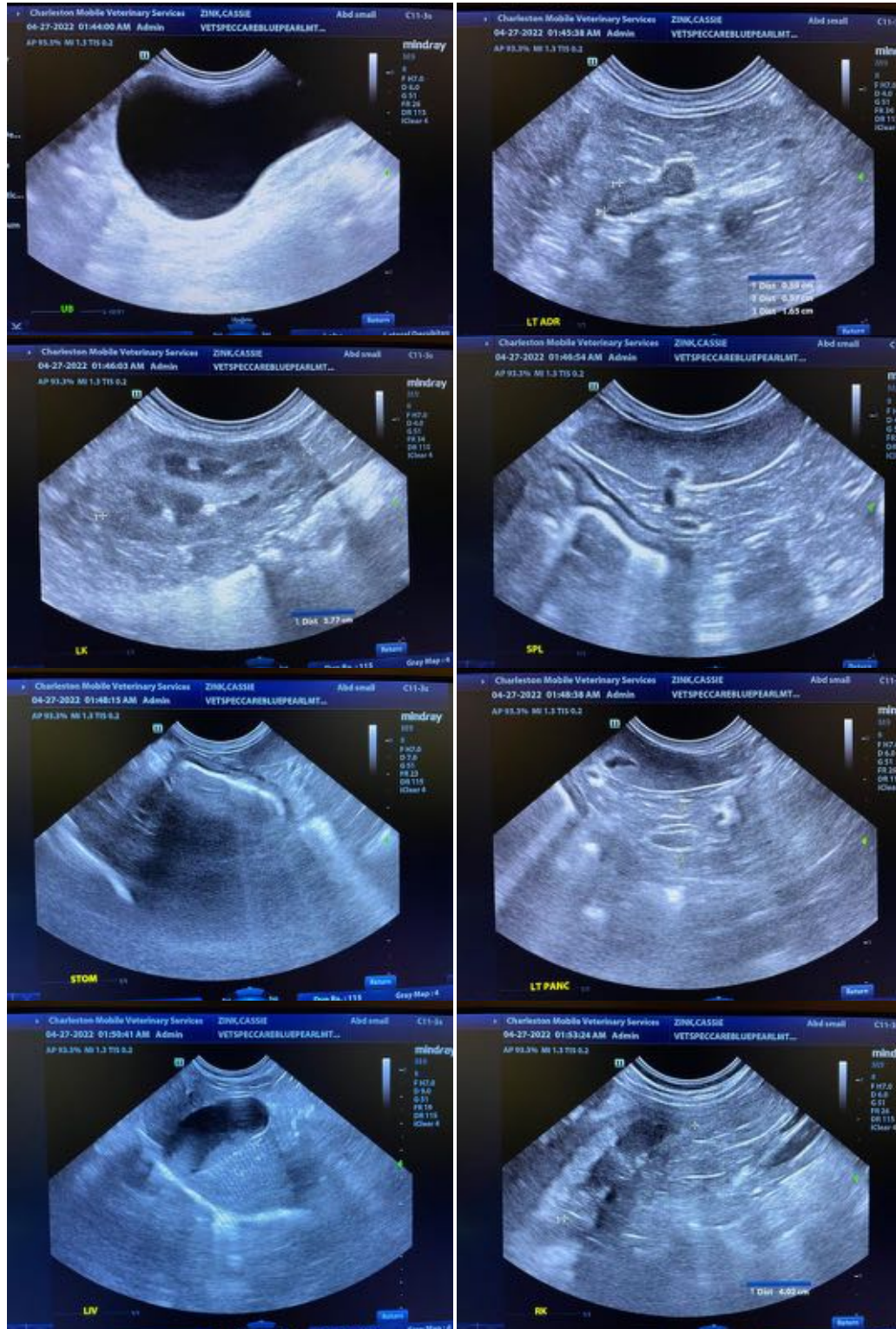INVOICE

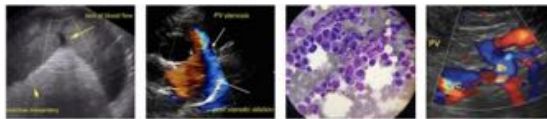
13281

DATE

4/27/22

- Consider testing for hyperadrenocorticism with a low-dose dexamethasone suppression test or ACTH stimulation test if clinical signs (i.e., PU/PD) develop in the future.





PATIENT

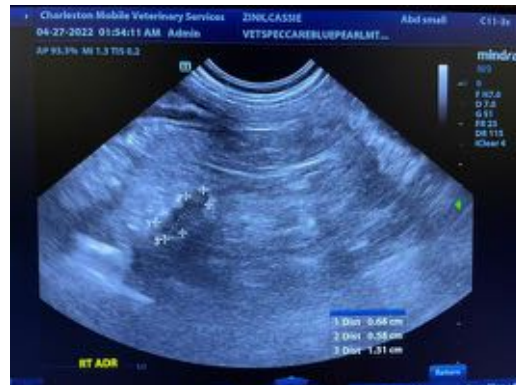Cassie Zink

SPECIES

Canine

BREED

Dachshund



SEX

Female, spayed

AGE

9/20/2008

WEIGHT

4.6 lbs.

The information and recommendations provided are based on the images presented by the referring veterinarian/sonographer. No evaluation can be communicated regarding pathology that was not visible in the image/video clips provided.

Thank you for this referral. If the clinical or image interpretation does not parallel your findings or if I can be of any further assistance please contact me.

Andrea Nicastro, DVM, Diplomate ACVIM (*Small Animal Internal Medicine*)

Andrea.Nicastro@CharlestonMobile.net

INTERPRETED BY

Andrea Nicastro, DVM,
Diplomate ACVIM
(*Small Animal Internal
Medicine*)

**IMAGING
PERFORMED BY**

Andrea Nicastro, DVM,
Diplomate ACVIM
(*Small Animal Internal
Medicine*)

HOSPITAL NAME

Blue Pearl

REFERRING VET

Dr. Johnson

INVOICE

13281

DATE

4/27/22