



PATIENT

Little Man Wilson

SPECIES

Canine

BREED

Australian cattledog

SEX

Male, neutered

AGE

9/6/2009

WEIGHT

46.8 lbs.

INTERPRETED BY

Andrea Nicastro, DVM,
Diplomate ACVIM
(Small Animal Internal
Medicine)

**IMAGING
PERFORMED BY**

Andrea Nicastro, DVM,
Diplomate ACVIM
(Small Animal Internal
Medicine)

HOSPITAL NAME

Brighton AH

REFERRING VET

Dr. Ciccone

INVOICE

14829

DATE

4/25/23

PRESENTING CLINICAL SIGNS

This is a recheck ultrasound with a liver biopsy; first ultrasound was completed on 9/22/2022.

The most recent liver values on 4/13/23 showed ALT 409, ALP of 634, PT/PTT normal.

ULTRASONOGRAPHIC EXAMINATION OF THE ABDOMEN

Urinary System

The urinary bladder wall is normal in thickness and the mucosal surface is smooth. The bladder is moderately distended. A scant amount of suspended echogenic debris is observed within the lumen. No cystic calculi are observed. The region of the trigone and the proximal urethra, visible to a depth of 2 cm, are normal.

The prostate is normal in size (0.18 cm in width) and shape. Parenchyma is homogenous. The prostatic urethra appears normal without evidence of dilation or obstruction.

The left kidney is normal size (6.52 cm in length); normal shape and architecture with smooth peripheral margins. There is a normal 1:3 cortex to medulla ratio with mild loss of corticomedullary distinction. There is no evidence of pyelectasia, nephroliths, infarcts or hydroureter. Renal vasculature is normal.

The right kidney is normal size (6.52 cm in length); normal shape and architecture with smooth peripheral margins. There is a normal 1:3 cortex to medulla ratio with mild loss of corticomedullary distinction. There is no evidence of pyelectasia, nephroliths, infarcts or hydroureter. Renal vasculature is normal.

Adrenal Glands

The left adrenal gland is normal size (0.59 cm at cranial pole) (0.70 cm at caudal pole); normal shape; homogenous parenchyma. The glandular echogenicity and detail are unremarkable. Capsule, cortex, and medullary definition are normal. The phrenicoabdominal vein and surrounding vasculature are normal.

The right adrenal gland is upper limits of normal size (0.95 cm at cranial pole) (0.76 cm at caudal pole); normal shape; homogenous parenchyma. The glandular echogenicity and detail are unremarkable. Capsule, cortex, and medullary definition are normal. The phrenicoabdominal vein and surrounding vasculature are normal.

Spleen

The spleen is normal in size (1.51 cm in width at the level of the hilus) with a normal capsular contour. There is appropriate echogenicity and echotexture. A 0.50 cm hyperechoic nodule is observed at the caudomedial aspect. Splenic vasculature is normal.

Liver

The liver is subjectively normal to slightly prominent in size. The parenchyma is isoechoic relative to the spleen and subtly heterogeneous in appearance. A 6.63 cm isoechoic slightly cavitated mass is observed in the region of the right medial lobe. The mass causes slight capsular expansion. The remaining peripheral margins are curvilinear. Vascular and biliary tracts are of normal volume with no evidence of congestion. The portal vein to caudal vena cava ratio is approximately 1:1. The gall bladder lumen is distended. The wall is normal in thickness. Several polypoid like lesions are arising from the luminal



PATIENT

Little Man Wilson

SPECIES

Canine

BREED

Australian cattledog

SEX

Male, neutered

AGE

9/6/2009

WEIGHT

46.8 lbs.

INTERPRETED BY

Andrea Nicastro, DVM,
Diplomate ACVIM
(Small Animal Internal
Medicine)

**IMAGING
PERFORMED BY**

Andrea Nicastro, DVM,
Diplomate ACVIM
(Small Animal Internal
Medicine)

HOSPITAL NAME

Brighton AH

REFERRING VET

Dr. Ciccone

INVOICE

14829

DATE

4/25/23

surface. A small amount of adhered echogenic to mineralized debris is seen within the lumen. The cystic and common bile ducts are normal/not seen.

Gastrointestinal

The stomach and intestine are free of stasis and exhibit normal peristaltic activity. The gastric lumen is mildly distended with ingesta. The gastric wall and pylorus are normal in thickness with a normal layering pattern. The pyloric outflow tract is patent. The small intestinal lumen is not dilated. The small intestinal wall thickness is normal with a normal layering pattern and appropriate mural detail. Discreet masses are not identified. The wall of the descending colon is mildly thickened (up to 0.50 cm) with retention of the normal layering pattern. No obstructive disease is noted.

Pancreas

The right limb of the pancreas is visible with normal curvilinear peripheral contours. The parenchyma is largely hyperechoic relative to surrounding omental fat and slightly mottled in appearance. The pancreatic duct is visible but not overtly dilated. There is no evidence of peripancreatic inflammation or effusion.

Free Abdomen

The peritoneal cavity is normal. There is no evidence of inflammation or effusion. The abdominal lymph nodes are normal/not visible.

Other

A brief echocardiogram reveals no obvious evidence of pericardial effusion.

*Fine needle aspirates of the hepatic mass were obtained at the end of the study without incident. 25 gauge needles were used for the procedure.

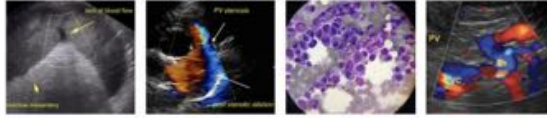
ULTRASONOGRAPHIC FINDINGS

Primary Findings:

- Hepatic mass in the region of the right medial lobe. The mass is slightly larger compared to the previous sonogram. Differentials include adenoma, adenocarcinoma, hemangiosarcoma, round cell tumor, benign lesion (i.e., inflammatory focus, large regenerative nodule), other.

Secondary Findings:

- The pancreatic changes are most consistent with age-related parenchymal remodeling, potentially secondary to a prior inflammatory episode, early fibrosis or chronic pancreatitis.
- Bilateral, chronic, age-related renal changes.
- Gallbladder debris, non-mucocele.
- The mild thickening of the descending colonic wall is most consistent with an inflammatory process with a lower possibility of emerging neoplasia.



PATIENT

Little Man Wilson

SPECIES

Canine

BREED

Australian cattledog

SEX

Male, neutered

AGE

9/6/2009

WEIGHT

46.8 lbs.

INTERPRETED BY

Andrea Nicastro, DVM,
Diplomate ACVIM
(Small Animal Internal
Medicine)

IMAGING PERFORMED BY

Andrea Nicastro, DVM,
Diplomate ACVIM
(Small Animal Internal
Medicine)

HOSPITAL NAME

Brighton AH

REFERRING VET

Dr. Ciccone

INVOICE

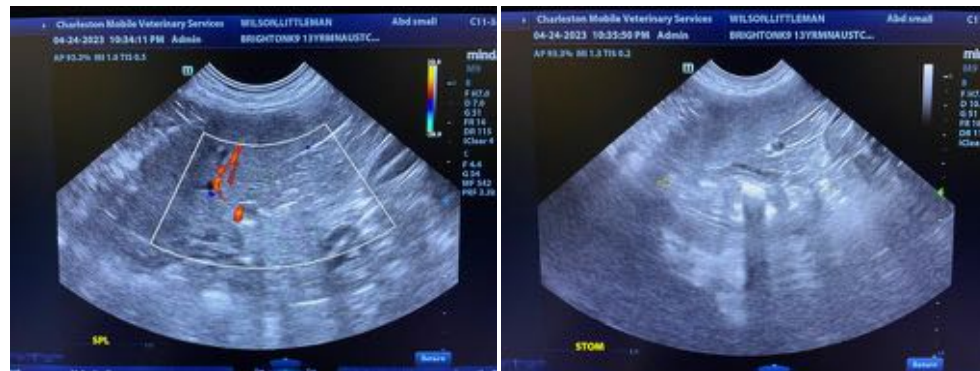
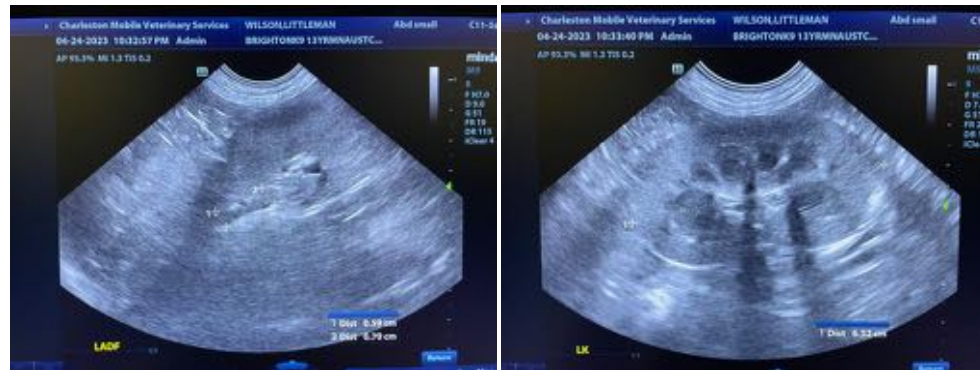
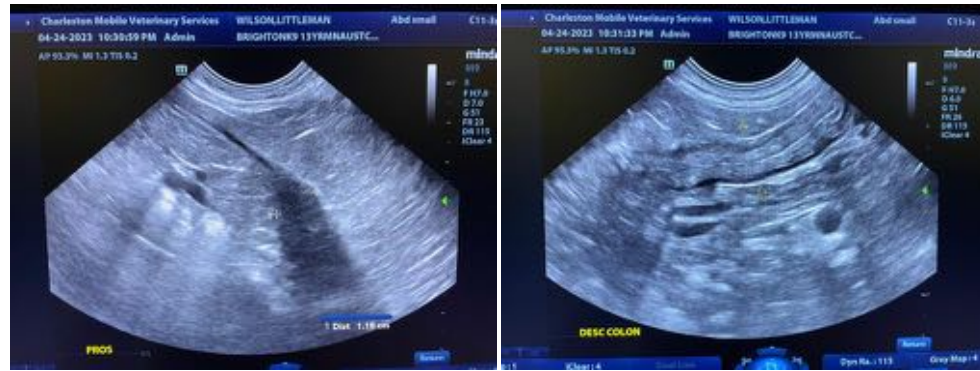
14829

DATE

4/25/23

INTERPRETATION OF THE FINDINGS & FURTHER RECOMMENDATIONS

- Three-view thoracic radiographs are recommended to assess for pulmonary metastases.
- If the cytology results from the hepatic mass are inconclusive, consider consultation with a board certified surgeon to discuss excisional biopsy with submission for histopathology. An abdominal CT scan would be useful in pre-surgical planning.





PATIENT

Little Man Wilson

SPECIES

Canine

BREED

Australian cattedog

SEX

Male, neutered

AGE

9/6/2009

WEIGHT

46.8 lbs.

INTERPRETED BY

Andrea Nicastro, DVM,
Diplomate ACVIM
(Small Animal Internal
Medicine)

**IMAGING
PERFORMED BY**

Andrea Nicastro, DVM,
Diplomate ACVIM
(Small Animal Internal
Medicine)

HOSPITAL NAME

Brighton AH

REFERRING VET

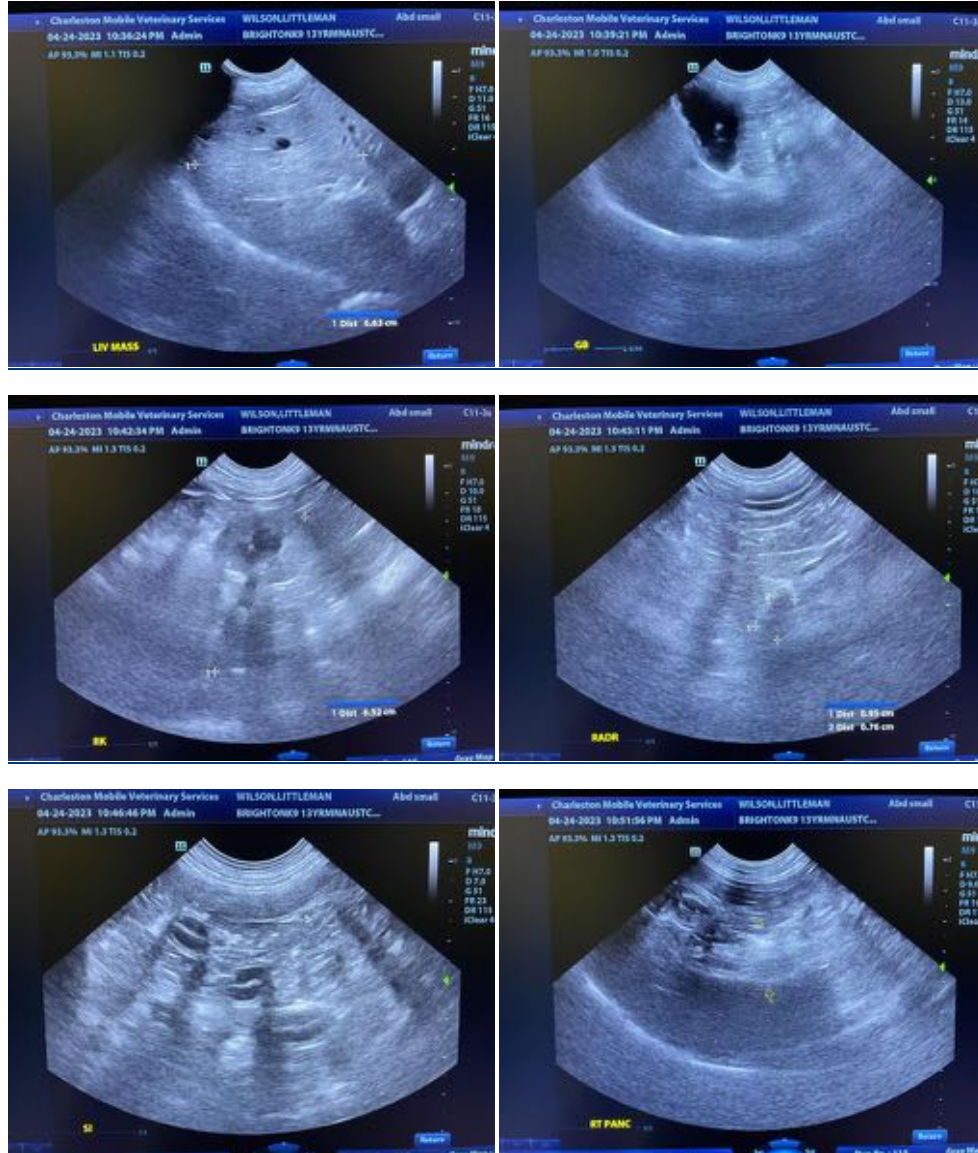
Dr. Ciccone

INVOICE

14829

DATE

4/25/23



The information and recommendations provided are based on the images presented by the referring veterinarian/sonographer. No evaluation can be communicated regarding pathology that was not visible in the image/video clips provided.

Thank you for this referral. If the clinical or image interpretation does not parallel your findings or if I can be of any further assistance please contact me.

Andrea Nicastro, MPH, DVM, Diplomate DACVIM (Small Animal Internal Medicine)
info@SonoPath.com