



**PATIENT**

Maddie Bonavito

**SPECIES**

Canine

**BREED**

Cavalier King Charles

**SEX**

Female, spayed

**AGE**

12/19/2013

**WEIGHT**

20 lbs.

**INTERPRETED BY**

Andrea Nicastro, DVM,  
Diplomate ACVIM  
(Small Animal Internal  
Medicine)

**IMAGING  
PERFORMED BY**

Andrea Nicastro, DVM,  
Diplomate ACVIM  
(Small Animal Internal  
Medicine)

**HOSPITAL NAME**

VCA Palmetto

**REFERRING VET**

Dr. Ghiorzi

**INVOICE**

13655

**DATE**

4/15/26

**PRESENTING CLINICAL SIGNS**

Maddie has history of heart murmur, being managed with Vetmedin, which has been progressing. She also has syringomyelia and macrocytic thrombocytopenia. Once we started her on Vetmedin, she has developed bilious vomiting if prolonged fasting - client has been feeding her even if a few treats, every 4 hours or so. Irregularly irregular extra beats ausculted.

Thrombocytopenia with platelet clumps and giant platelets present. Mild lymphopenia. Chem panel unremarkable, T4 normal. 4DX negative.

**ULTRASONOGRAPHIC EXAMINATION OF THE ABDOMEN**

**Urinary System**

The urinary bladder wall is normal in thickness and the mucosal surface is smooth. The bladder is moderately distended. Luminal contents are anechoic. No cystic calculi are observed. The region of the trigone and the visible portion of the proximal urethra are normal.

The left kidney is normal in size (4.22 cm in length) with a normal shape, architecture and smooth peripheral margins. There is a normal 1:3 cortex to medulla ratio with mild loss of corticomedullary distinction. A few small non-obstructive mineralized foci are visualized. There is no evidence of pyelectasia, infarcts or hydronephrosis. Renal vasculature is normal.

The right kidney is normal in size (4.85 cm in length) with a normal shape, architecture and smooth peripheral margins. There is a normal 1:3 cortex to medulla ratio with mild loss of corticomedullary distinction. A few small non-obstructive mineralized foci are visualized. There is no evidence of pyelectasia, infarcts or hydronephrosis. Renal vasculature is normal.

**Adrenal Glands**

The left adrenal gland is normal in size (0.59 cm at cranial pole) (0.43 cm at caudal pole) with a normal shape. A 0.87 x 0.38 cm hyperechoic nodule is observed at the cranial pole. The glandular echogenicity and detail at the caudal pole are unremarkable. The phrenicoabdominal vein and surrounding vasculature are normal.

The right adrenal gland is normal in size (0.48 cm at cranial pole) (0.37 cm at caudal pole) with a normal shape and homogenous parenchyma. The glandular echogenicity and detail are unremarkable. Capsule, cortex, and medullary definition are normal. The phrenicoabdominal vein and surrounding vasculature are normal.

**Spleen**

The spleen is normal in size (1.45 cm in width at the level of the hilus) with a normal capsular contour. The parenchyma is subtly mottled in appearance. No focal lesions are observed. Splenic vasculature is normal.

**Liver**

The liver is subjectively normal in size with normal curvilinear peripheral contours. The parenchyma is hypoechoic relative to the spleen and slightly mottled in appearance. No distinct focal lesions are observed. Hepatic vasculature and intrahepatic biliary tracts are of normal volume with no evidence of congestion. The portal vein to caudal vena cava ratio is approximately 1:1.

The gallbladder is of normal contours and contains some dependent echogenic debris. The wall is normal in thickness. No choleliths are observed. The cystic and common bile ducts are normal.



**PATIENT**

Maddie Bonavito

**SPECIES**

Canine

**BREED**

Cavalier King Charles

**SEX**

Female, spayed

**AGE**

12/19/2013

**WEIGHT**

20 lbs.

**INTERPRETED BY**

Andrea Nicastro, DVM,  
Diplomate ACVIM  
(Small Animal Internal  
Medicine)

**IMAGING  
PERFORMED BY**

Andrea Nicastro, DVM,  
Diplomate ACVIM  
(Small Animal Internal  
Medicine)

**HOSPITAL NAME**

VCA Palmetto

**REFERRING VET**

Dr. Ghiorzi

**INVOICE**

13655

**DATE**

4/15/26

***Gastrointestinal***

The gastric lumen is mildly distended with ingesta. The gastric wall and pylorus are normal in thickness with a normal layering pattern. The pyloric outflow tract is patent. The small intestinal lumen is not dilated. The small intestinal wall is normal in thickness with a normal layering pattern and appropriate mural detail. Discreet masses are not identified. The ileoceocolic junction and colonic wall are normal. There is no evidence of an obstructive pattern.

***Pancreas***

The region of the pancreas is isoechoic relative to surrounding omental fat. No obvious parenchymal abnormalities are observed. There is no evidence of regional inflammation or effusion.

***Lymph nodes***

The abdominal lymph nodes are normal/not visible.

***Free Abdomen***

There is no obvious evidence of free fluid.

**ULTRASONOGRAPHIC FINDINGS**

- Bilateral nonspecific, age-related renal changes with non-obstructive nephrocalcinosis.
- Geriatric hepatic parenchymal changes
- The left adrenal nodule could be consistent with focal nodular hyperplasia, adenoma or less likely, emerging adenocarcinoma, pheochromocytoma, other.
- The splenic parenchymal changes are most consistent with a benign process such as lymphoid hyperplasia, extramedullary hematopoiesis, splenitis or antigenic stimulation with a lower possibility of infiltrative neoplasia (i.e., lymphoma, mast cell neoplasia).
- If the patient was fasted for this study, the presence of ingesta within the gastric lumen could suggest delayed gastric emptying.

\*An obvious cause for the patient's clinical signs is not identified in this study. Considerations include drug side effect, bilious vomiting syndrome, infectious/parasitic disease, food allergy/intolerance, inflammatory bowel disease, underlying metabolic issue, other.

**INTERPRETATION OF THE FINDINGS & FURTHER RECOMMENDATIONS**

1. If alterations in the feeding schedule do not improve the patient's clinical signs, consider further GI workup (i.e., GI panel, resting cortisol level, limited antigen diet trial +/- GI biopsies).
2. Further recommendations should be based on the echocardiogram report.



**PATIENT**

Maddie Bonavito

**SPECIES**

Canine

**BREED**

Cavalier King Charles

**SEX**

Female, spayed

**AGE**

12/19/2013

**WEIGHT**

20 lbs.

**INTERPRETED BY**

Andrea Nicastro, DVM,  
 Diplomate ACVIM  
 (Small Animal Internal  
 Medicine)

**IMAGING  
 PERFORMED BY**

Andrea Nicastro, DVM,  
 Diplomate ACVIM  
 (Small Animal Internal  
 Medicine)

**HOSPITAL NAME**

VCA Palmetto

**REFERRING VET**

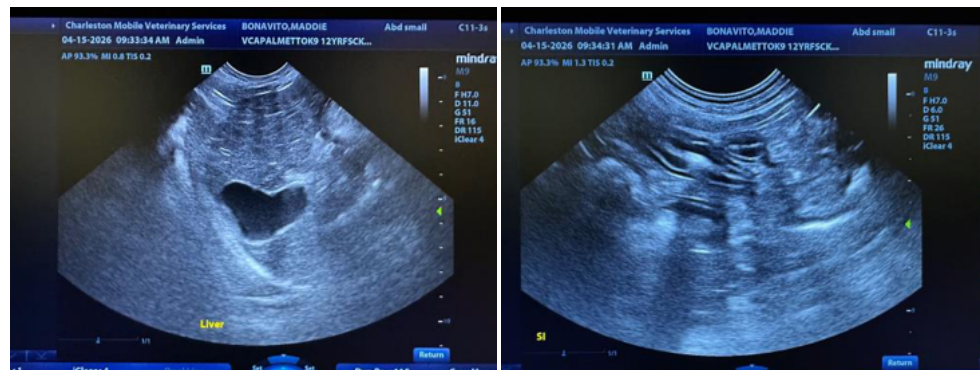
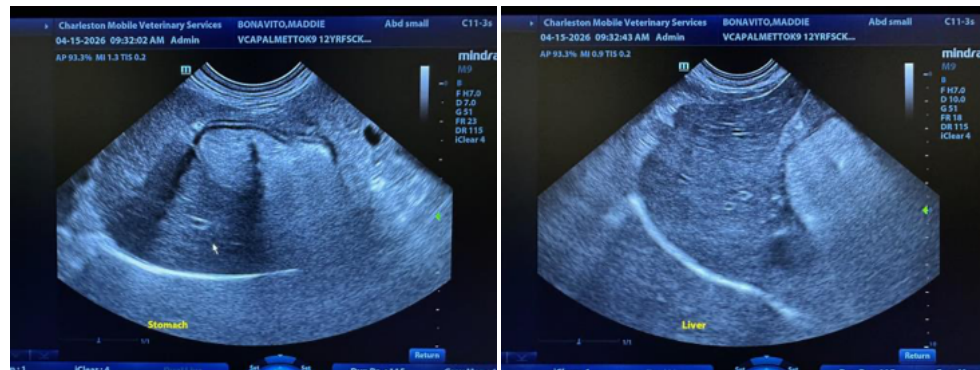
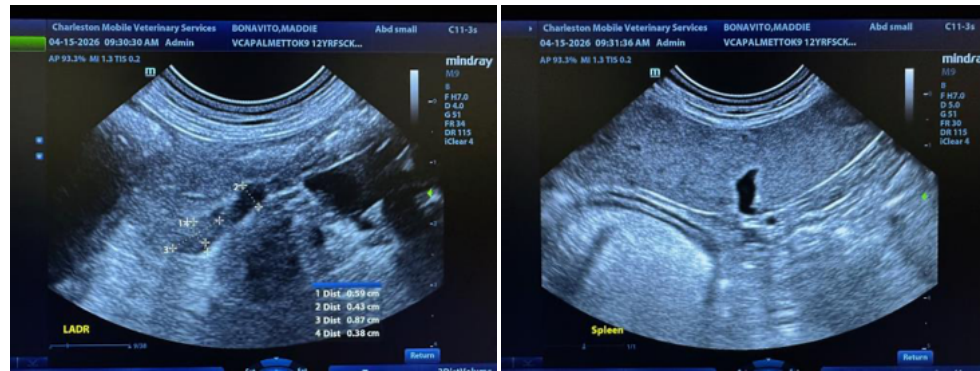
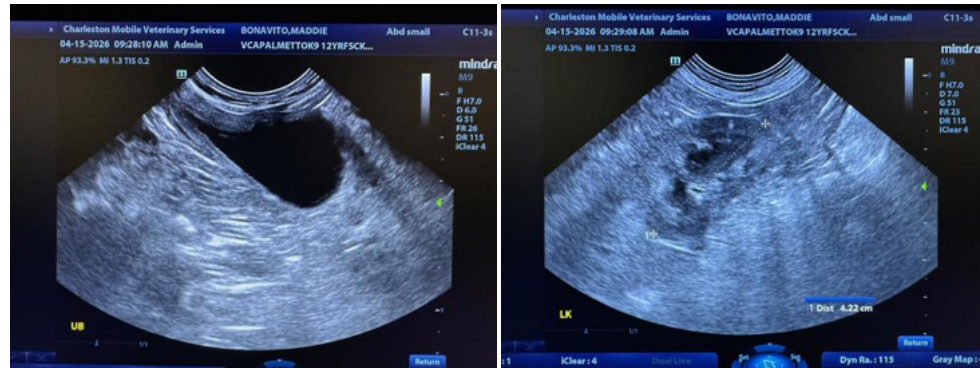
Dr. Ghiorzi

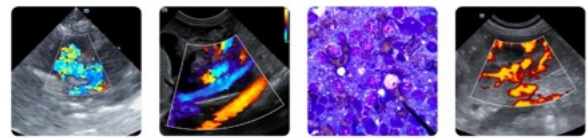
**INVOICE**

13655

**DATE**

4/15/26





**PATIENT**

Maddie Bonavito

**SPECIES**

Canine

**BREED**

Cavalier King Charles

**SEX**

Female, spayed

**AGE**

12/19/2013

**WEIGHT**

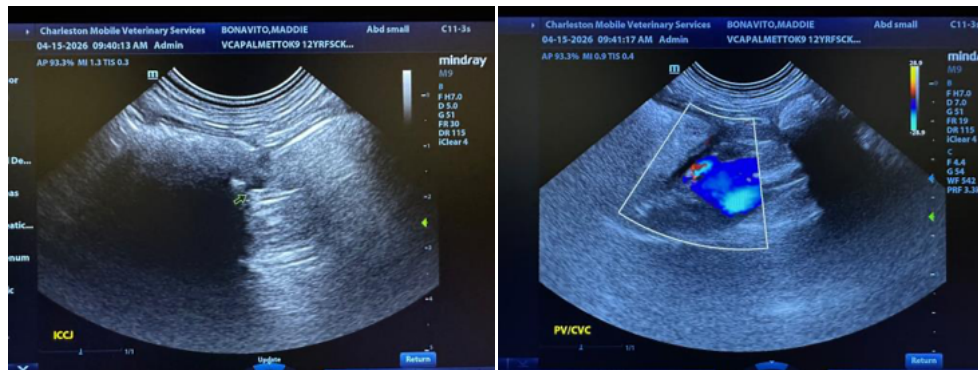
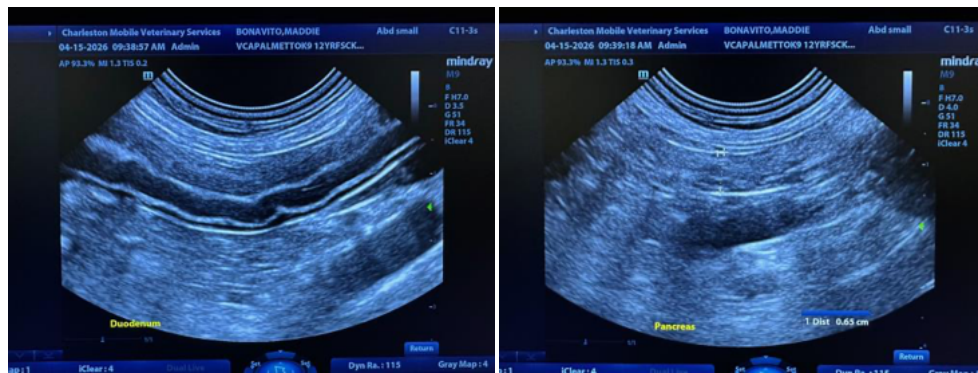
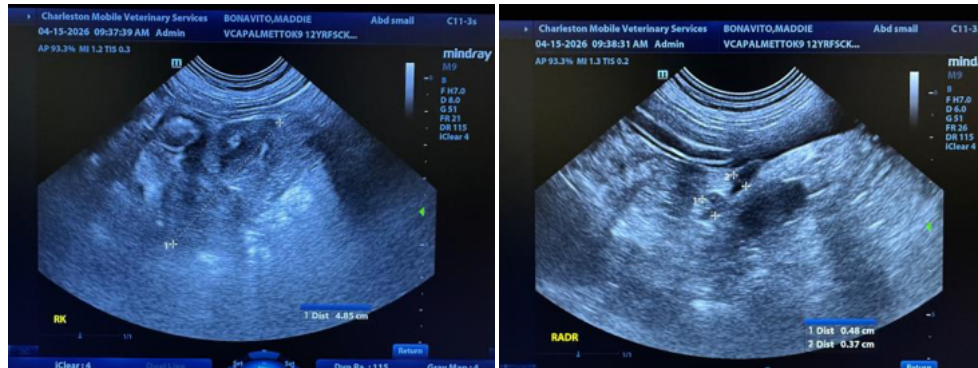
20 lbs.

**INTERPRETED BY**

Andrea Nicastro, DVM,  
 Diplomate ACVIM  
 (Small Animal Internal  
 Medicine)

**IMAGING  
 PERFORMED BY**

Andrea Nicastro, DVM,  
 Diplomate ACVIM  
 (Small Animal Internal  
 Medicine)



**HOSPITAL NAME**

VCA Palmetto

**REFERRING VET**

Dr. Ghiorzi

**INVOICE**

13655

**DATE**

4/15/26

The information and recommendations provided are based on the images presented by the referring veterinarian/sonographer. No evaluation can be communicated regarding pathology that was not visible in the image/video clips provided.

Thank you for this referral. If the clinical or image interpretation does not parallel your findings or if I can be of any further assistance please contact me.

Andrea Nicastro, MPH, DVM, Diplomate DACVIM (Small Animal Internal Medicine)  
[info@SonoPath.com](mailto:info@SonoPath.com)