

PATIENT PRESENTING CLINICAL SIGNS

PATIENT
Shay Cray

SPECIES
Canine

BREED
Basset Hound

SEX
Female, intact

AGE
8 Yrs.

WEIGHT
51.4 lbs.

INTERPRETED BY
Andrea Nicastro, DVM,
Diplomate ACVIM
(Small Animal Internal
Medicine)

IMAGING PERFORMED BY
Andrea Nicastro, DVM,
Diplomate ACVIM
(Small Animal Internal
Medicine)

HOSPITAL NAME
Flowertown AH

REFERRING VET
Dr. Pignatello

INVOICE
14705

DATE
3/7/23

-- Presented for evaluation of acute onset vomiting and anorexia
-- Recently finished heat cycle
-- No diarrhea
-- No known foreign body ingestion, toxin exposure, or dietary indiscretion
-- PE fairly unremarkable

ULTRASONOGRAPHIC EXAMINATION OF THE ABDOMEN

Urinary System

The urinary bladder wall is normal in thickness and the mucosal surface is smooth. The bladder lumen is distended with anechoic urine. No masses, inflammatory changes or calculi are observed. Ureteral papillae and visualized portion of the proximal urethra, visible to a depth of 3-4 cm, are normal.

The left kidney is normal in size (6.38 cm in length) with a normal shape, smooth peripheral margins and normal internal architecture. There is mild to moderate loss of corticomedullary distinction. Hyperechoic foci are observed throughout the cortex. Mild pyelectasia is present (0.38 cm in the transverse plane). There is no evidence of infarcts or hydronephrosis. Renal vasculature is normal.

The right kidney is normal size (6.90 cm in length) with a normal shape, smooth peripheral margins and normal internal architecture. There is mild to moderate loss of corticomedullary distinction. Hyperechoic foci are observed throughout the cortex. Mild pyelectasia is present (0.38 cm in the transverse plane). There is no evidence of infarcts or hydronephrosis. Renal vasculature is normal.

Adrenal Glands

The left adrenal gland is normal size (0.54 cm at cranial pole) (0.68 cm at caudal pole) with a normal shape and smooth peripheral contours. A pinpoint hyperechoic focus is observed at the caudal pole. Glandular echogenicity and detail are otherwise normal. The phrenicoabdominal vein and surrounding vasculature are normal.

The right adrenal gland is normal size (1.47 cm at cranial pole) (0.59 cm at caudal pole) with a normal shape and smooth peripheral contours. A 1.47 x 1.34 cm hyperechoic nodule is observed at the cranial pole. Glandular echogenicity and detail at the caudal pole are normal. The phrenicoabdominal vein and surrounding vasculature are normal.

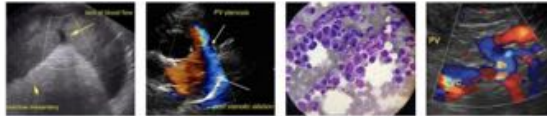
Spleen

The spleen is normal in size (1.66 cm in width at the level of the hilus) with a normal capsular contour. There is appropriate echogenicity and echotexture. No focal lesions are observed. Splenic vasculature is normal.

Liver

The liver is subjectively enlarged with slightly swollen peripheral contours. The parenchyma is hypoechoic relative to the spleen and diffusely homogeneous in appearance. No distinct focal lesions are observed. Vascular and biliary tracts are of normal volume with no evidence of congestion. The portal vein: caudal vena cava ratio is approximately 1:1. The gall bladder lumen is moderately distended. The wall is thin and smooth. Luminal contents are anechoic. The cystic and common bile ducts are normal/not seen.

Gastrointestinal



PATIENT

Shay Cray

The stomach and intestine are free of stasis and exhibit normal peristaltic activity. The gastric lumen is not distended. The gastric wall and pylorus are normal in thickness with a normal layering pattern. The pyloric outflow tract is patent. The small intestinal lumen is not dilated. The small intestinal wall thickness is normal with a normal layering pattern and appropriate mural detail. Discreet masses are not identified. The colonic wall is normal. No obstructive disease is noted.

SPECIES

Canine

Pancreas

BREED

Basset Hound

The right limb of the pancreas is normal in size with normal curvilinear peripheral contours. The parenchyma is largely isoechoic relative to surrounding omental fat and slightly mottled in appearance. The pancreatic duct is visible but not overtly dilated. There is no evidence of peripancreatic inflammation or effusion.

SEX

Female, intact

Free Abdomen

There is no obvious evidence of free fluid. Several prominent to enlarged rounded slightly hypoechoic medial iliac and sublumbar lymph nodes are visualized. The left medial iliac lymph node measures 2.44 cm in length and the right medial iliac lymph node measures 2.34 cm in length.

AGE

8 Yrs.

Other

The uterine horns and uterine body are visible. The uterine body measures 1.05 cm in width. No obvious pathology is seen.

WEIGHT

51.4 lbs.

The ovaries are subjectively normal in size (left 2.36 x 1.19 cm; right 2.42 x 1.16 cm). No obvious pathology is seen.

INTERPRETED BY

Andrea Nicastro, DVM,
Diplomate ACVIM
(*Small Animal Internal
Medicine*)

A brief echocardiogram reveals no evidence of pericardial effusion or obvious right atrial/auricular mass.

*Fine needle aspirates of the medial iliac lymph nodes were performed at the end of the study without incident.

IMAGING PERFORMED BY

Andrea Nicastro, DVM,
Diplomate ACVIM
(*Small Animal Internal
Medicine*)

ULTRASONOGRAPHIC FINDINGS

Primary Findings:

- The caudal abdominal lymphadenopathy could be consistent with reactive change or emerging neoplasia (i.e., round cell tumor).

Secondary Findings:

- Bilateral, chronic renal changes with dystrophic mineralization and mild left pyelectasia.
- The hepatic changes are most consistent with a benign hepatopathy (i.e., vacuolar hepatopathy), particularly in light of the normal liver values.
- The right adrenal nodule could be consistent with benign nodular hyperplasia or an emerging tumor.
- Minor, age-related pancreatic remodeling in the right limb.

HOSPITAL NAME

Flowertown AH

REFERRING VET

Dr. Pignatello

INVOICE

14705

DATE

3/7/23



PATIENT

Shay Cray

SPECIES

Canine

BREED

Basset Hound

SEX

Female, intact

AGE

8 Yrs.

WEIGHT

51.4 lbs.

INTERPRETED BY

Andrea Nicastro, DVM,
Diplomate ACVIM
(Small Animal Internal
Medicine)

IMAGING PERFORMED BY

Andrea Nicastro, DVM,
Diplomate ACVIM
(Small Animal Internal
Medicine)

HOSPITAL NAME

Flowertown AH

REFERRING VET

Dr. Pignatello

INVOICE

14705

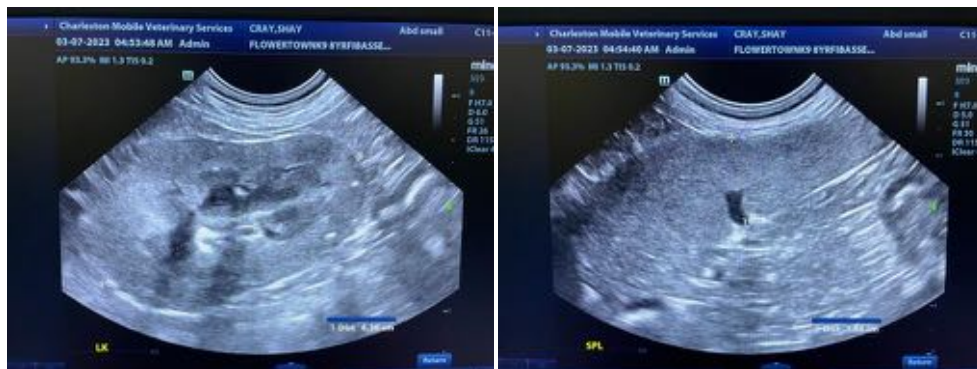
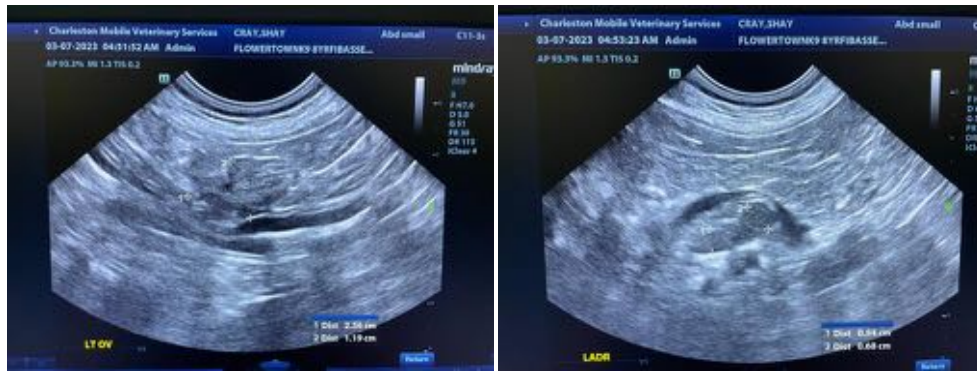
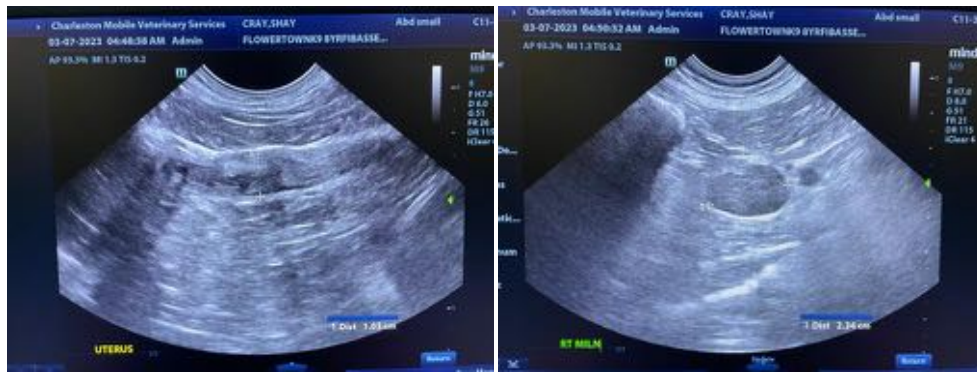
DATE

3/7/23

INTERPRETATION OF THE FINDINGS & FURTHER RECOMMENDATIONS

Cytologic evaluation of the medial iliac lymph nodes is to be performed. Other diagnostic/therapeutic considerations include the following:

1. A fecal evaluation for ova/Giardia
2. Symptomatic care for acute gastroenteritis.
3. If cytology results are inconclusive and if the patient does not respond to medical management, a more comprehensive GI workup (i.e., malabsorption panel, diet trial, GI biopsies) may be warranted.
4. Consider a recheck ultrasound in 3-6 months to reevaluate the right adrenal nodule.





PATIENT

Shay Cray

SPECIES

Canine

BREED

Basset Hound

SEX

Female, intact

AGE

8 Yrs.

WEIGHT

51.4 lbs.

INTERPRETED BY

Andrea Nicastro, DVM,
Diplomate ACVIM
(Small Animal Internal
Medicine)

IMAGING PERFORMED BY

Andrea Nicastro, DVM,
Diplomate ACVIM
(Small Animal Internal
Medicine)

HOSPITAL NAME

Flowertown AH

REFERRING VET

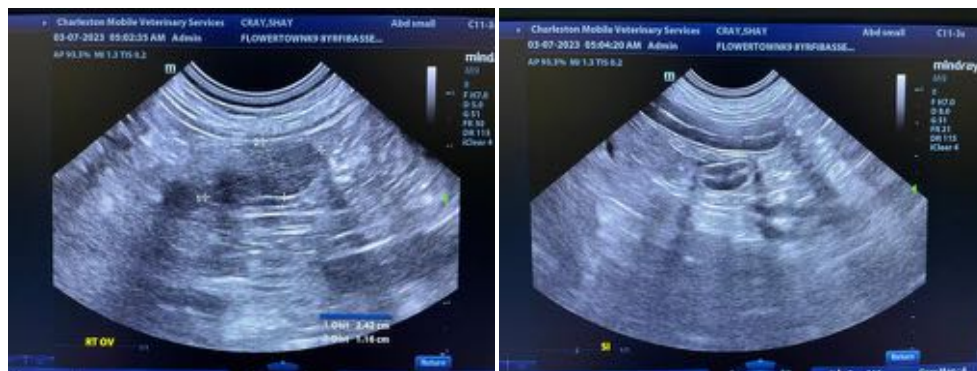
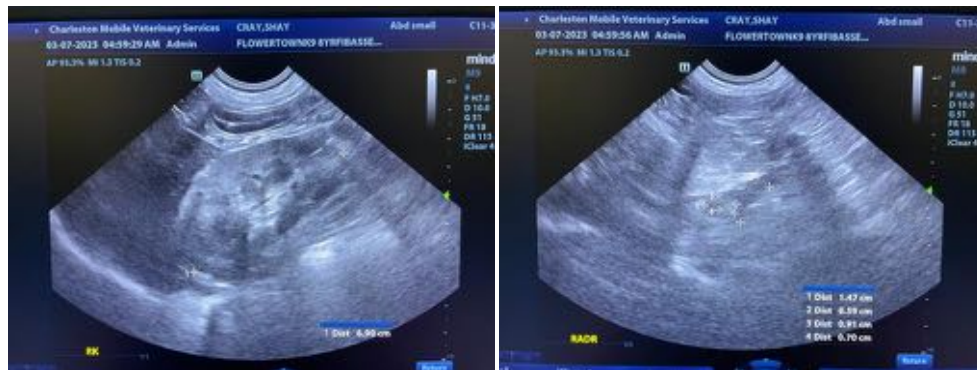
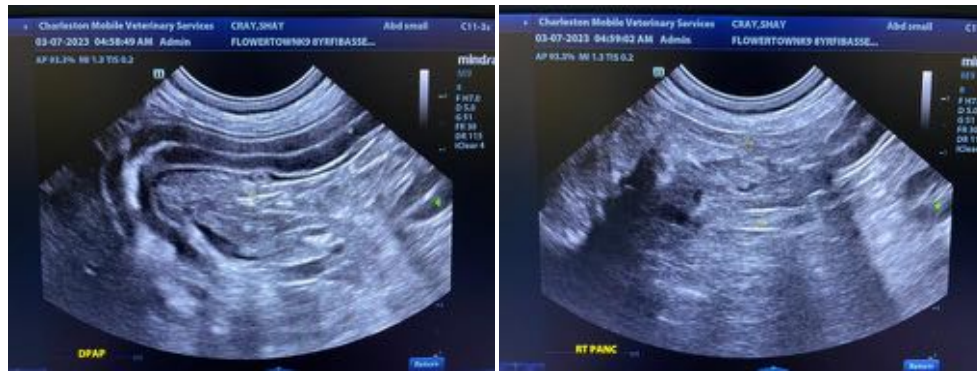
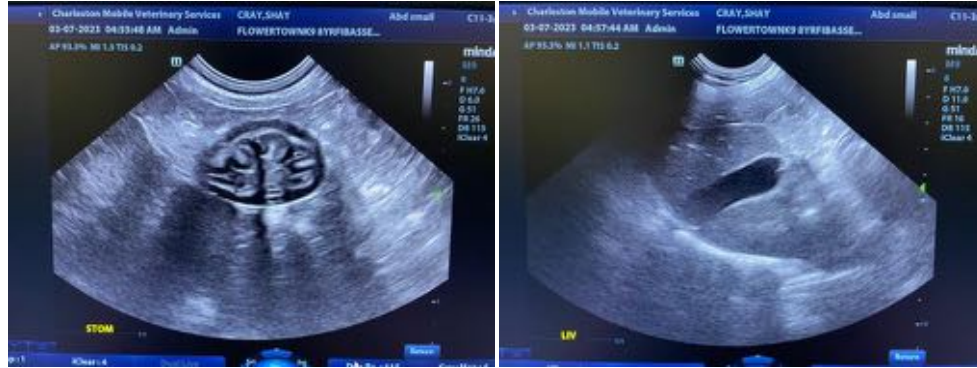Dr. Pignatello

INVOICE

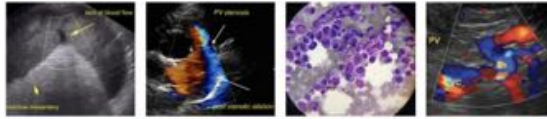
14705

DATE

3/7/23



The information and recommendations provided are based on the images presented by the referring veterinarian/sonographer. No evaluation can be communicated regarding pathology that was not visible



PATIENT in the image/video clips provided.

Shay Cray Thank you for this referral. If the clinical or image interpretation does not parallel your findings or if I can be of any further assistance please contact me.

SPECIES

Canine Andrea Nicastro, MPH, DVM, Diplomate DACVIM (Small Animal Internal Medicine)
info@SonoPath.com

BREED

Basset Hound

SEX

Female, intact

AGE

8 Yrs.

WEIGHT

51.4 lbs.

INTERPRETED BY

Andrea Nicastro, DVM,
Diplomate ACVIM
(*Small Animal Internal
Medicine*)

**IMAGING
PERFORMED BY**

Andrea Nicastro, DVM,
Diplomate ACVIM
(*Small Animal Internal
Medicine*)

HOSPITAL NAME

Flowertown AH

REFERRING VET

Dr. Pignatello

INVOICE

14705

DATE

3/7/23